Settings

1 2 3 4 5 6 7 8 9 10 11 12 13 14 15 16 17 18 19 20 21 22 23 24 25 26 27 28 29 30

Item 1 of 40
Question Id: 1060

Mark | Previous | Next | Full Screen | Tutorial | Lab Values | Notes | Calculator | Reverse Color | Text Zoom | Settings

A 59-year-old man comes to the emergency department with diplopia that started several hours ago. His past medical history is significant for long-standing diabetes with poor glycemic control, right-knee osteoarthritis, and peptic ulcer disease. Physical examination shows right-sided ptosis with the right pupil in the inferolateral position. Pupils are equal in size and reactive to light bilaterally. This patient's condition is most likely due to which of the following etiologies?

A. Nerve compression

B. Nerve inflammation

C. Nerve ischemia

D. Lacunar stroke

E. Muscle infiltration

Submit

Block Time Remaining: 00:00:02
TUTOR

3 | Feedback | Suspend | End Block

Settings

1 2 3 4 5 6 7 8 9 10 11 12 13 14 15 16 17 18 19 20 21 22 23 24 25 26 27 28 29 30

Item 1 of 40
Question Id: 1060

Mark | Previous | Next | Full Screen | Tutorial | Lab Values | Notes | Calculator | Reverse Color | Text Zoom | Settings

A 59-year-old man comes to the emergency department with diplopia that started several hours ago. His past medical history is significant for long-standing diabetes with poor glycemic control, right-knee osteoarthritis, and peptic ulcer disease. Physical examination shows right-sided ptosis with the right pupil in the inferolateral position. Pupils are equal in size and reactive to light bilaterally. This patient's condition is most likely due to which of the following etiologies?

- A. Nerve compression (21%)
- B. Nerve inflammation (11%)
- ✓ C. Nerve ischemia (54%)
- D. Lacunar stroke (9%)
- E. Muscle infiltration (2%)

Omitted
Correct answer
C

54%
Answered correctly

04 secs
Time Spent

03/15/2020
Last Updated

Explanation

Block Time Remaining: 00:00:04
TUTOR

3 | Feedback | Suspend | End Block

Aneurysmal compression of oculomotor nerve

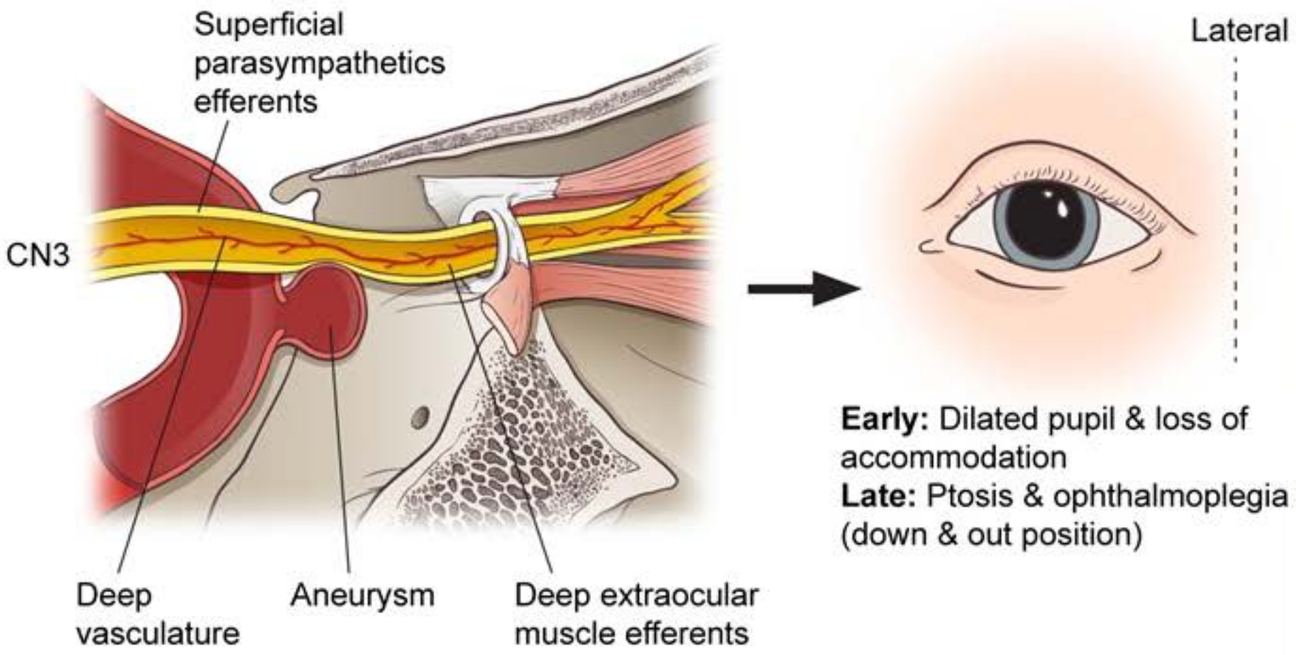

Early: Dilated pupil & loss of accommodation
Late: Ptosis & ophthalmoplegia (down & out position)

Diabetic ophthalmoplegia

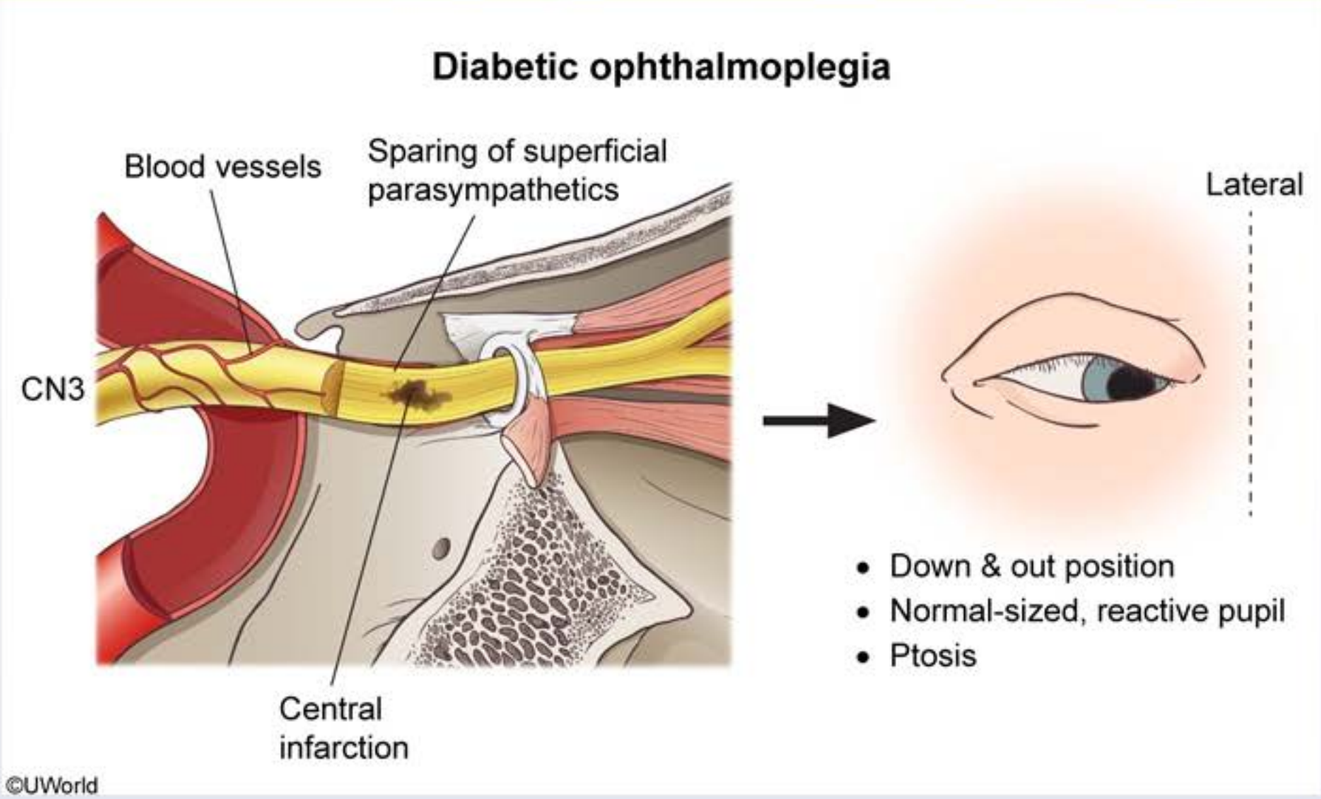

Neuropathy is a common chronic complication of diabetes mellitus. The clinical features of diabetic neuropathy vary considerably depending on the pattern of nerve involvement, which can be broadly divided into polyneuropathy, mononeuropathy, and autonomic neuropathy. Mononeuropathies can also be further subdivided into cranial and peripheral types.

All ocular motor nerves (III, IV, VI) can be affected in diabetes but unilateral cranial nerve III (CN III) involvement is most common. **Diabetic CN III mononeuropathy** classically presents with **acute onset diplopia**. On examination, the affected eye assumes a **"down and out" position** due to the unopposed pull by the superior oblique (CN IV) and lateral rectus (CN VI) muscles because all other extraocular muscles (inferior oblique and superior, inferior, and medial recti) are supplied by CN III. **Ptosis** also occurs due to paralysis of the levator palpebrae.

©UWorld

Neuropathy is a common chronic complication of diabetes mellitus. The clinical features of diabetic neuropathy vary considerably depending on the pattern of nerve involvement, which can be broadly divided into polyneuropathy, mononeuropathy, and autonomic neuropathy. Mononeuropathies can also be further subdivided into cranial and peripheral types.

All ocular motor nerves (III, IV, VI) can be affected in diabetes but unilateral cranial nerve III (CN III) involvement is most common. **Diabetic CN III mononeuropathy** classically presents with **acute onset diplopia**. On examination, the affected eye assumes a **"down and out" position** due to the unopposed pull by the superior oblique (CN IV) and lateral rectus (CN VI) muscles because all other extraocular muscles (inferior oblique and superior, inferior, and medial recti) are supplied by CN III. **Ptosis** also occurs due to paralysis of the levator palpebrae.

Diabetic mononeuropathy is caused by ischemic nerve damage, which predominantly involves the core of the CN III with relative sparing of the peripheral part. The somatic component of CN III that innervates the extraocular muscles is located centrally, but the autonomic component responsible for pupillary constriction and accommodation is located in the peripheral aspect of the nerve. Therefore, **pupillary size and reactivity is normal** in diabetic CN III mononeuropathy.

(Choice A) CN III neuropathy can also occur due to nerve compression. Causes include transtentorial (uncal) herniation, neoplasms, and aneurysms of the posterior cerebral and posterior communicating arteries. In contrast to diabetic CN III mononeuropathy, pupillary dysfunction is often an early manifestation of external nerve compression due to injury of the peripherally located parasympathetic fibers.

(Choices B and E) Neither nerve inflammation nor muscle infiltration contributes to the development of diabetic neuropathy.

(Choice D) Lacunar midbrain strokes can involve the CN III nuclei. Because many neurologic pathways are densely packed in this area, CN III nuclei impairment is almost always associated with other neurologic deficits (eg, cerebellar ataxia, hemiparesis, or contralateral extrapyramidal symptoms). In addition, the contralateral superior rectus is affected because the subnucleus fibers decussate to the contralateral side. Midbrain lesions also cause bilateral ptosis because both levator palpebrae are innervated by a single subnucleus.

Educational objective:
Diabetic mononeuropathy often involves cranial nerve III. It is caused by predominantly central ischemia, which affects the somatic nerve fibers but spares peripheral parasympathetic fibers. Symptoms include ptosis, a "down and out" gaze, and normal light and accommodation reflexes.

superior, inferior, and medial recti) are supplied by CN III. **Ptosis** also occurs due to paralysis of the levator palpebrae.

Diabetic mononeuropathy is caused by ischemic nerve damage, which predominantly involves the core of the CN III with relative sparing of the peripheral part. The somatic component of CN III that innervates the extraocular muscles is located centrally, but the autonomic component responsible for pupillary constriction and accommodation is located in the peripheral aspect of the nerve. Therefore, **pupillary size and reactivity is normal** in diabetic CN III mononeuropathy.

(Choice A) CN III neuropathy can also occur due to nerve compression. Causes include transtentorial (uncal) herniation, neoplasms, and aneurysms of the posterior cerebral and posterior communicating arteries. In contrast to diabetic CN III mononeuropathy, pupillary dysfunction is often an early manifestation of external nerve compression due to injury of the peripherally located parasympathetic fibers.

(Choices B and E) Neither nerve inflammation nor muscle infiltration contributes to the development of diabetic neuropathy.

(Choice D) Lacunar midbrain strokes can involve the CN III nuclei. Because many neurologic pathways are densely packed in this area, CN III nuclei impairment is almost always associated with other neurologic deficits (eg, cerebellar ataxia, hemiparesis, or contralateral extrapyramidal symptoms). In addition, the contralateral superior rectus is affected because the subnucleus fibers decussate to the contralateral side. Midbrain lesions also cause bilateral ptosis because both levator palpebrae are innervated by a single subnucleus.

Educational objective:
Diabetic mononeuropathy often involves cranial nerve III. It is caused by predominantly central ischemia, which affects the somatic nerve fibers but spares peripheral parasympathetic fibers. Symptoms include ptosis, a "down and out" gaze, and normal light and accommodation reflexes.

References

- Acute ocular motor mononeuropathies: prospective study of the roles of neuroimaging and clinical assessment.

Pathology	Nervous System	Cranial nerve palsy
Subject	System	Topic

Copyright © UWorld. All rights reserved.

Settings

1 2 3 4 5 6 7 8 9 10 11 12 13 14 15 16 17 18 19 20 21 22 23 24 25 26 27 28 29 30

Item 2 of 40
Question Id: 919

Mark | Previous | Next | Full Screen | Tutorial | Lab Values | Notes | Calculator | Reverse Color | Text Zoom | Settings

A 34-year-old woman comes to the office due to a 2-day history of reduced sensation in her legs. Lately, the patient has also had significant fatigue, especially with exercise. Six months ago, she had an episode of visual blurring that resolved spontaneously after a few days. Medical history is significant for psoriasis, for which she uses a topical glucocorticoid ointment. The patient does not use tobacco or illicit drugs. Vital signs are normal. Examination indicates decreased pain and light touch perception in both legs below the level of the umbilicus. Mild bilateral spasticity is noted. Which of the following pathologic brain lesions is most specific for this patient's disease process?

A. Microglial nodules

B. Neuritic plaques and neurofibrillary tangles

C. Perivenular inflammatory cells

D. Spongiform changes

E. Viral inclusions

Submit

Block Time Remaining: 00:00:04
TUTOR

3 | Feedback | Suspend | End Block

A 34-year-old woman comes to the office due to a 2-day history of reduced sensation in her legs. Lately, the patient has also had significant fatigue, especially with exercise. Six months ago, she had an episode of visual blurring that resolved spontaneously after a few days. Medical history is significant for psoriasis, for which she uses a topical glucocorticoid ointment. The patient does not use tobacco or illicit drugs. Vital signs are normal. Examination indicates decreased pain and light touch perception in both legs below the level of the umbilicus. Mild bilateral spasticity is noted. Which of the following pathologic brain lesions is most specific for this patient's disease process?

- A. Microglial nodules (26%)
- B. Neuritic plaques and neurofibrillary tangles (3%)
- ✓ C. Perivenular inflammatory cells (59%)
- D. Spongiform changes (3%)
- E. Viral inclusions (5%)

Omitted
Correct answer
C

59%
Answered correctly

01 sec
Time Spent

03/27/2020
Last Updated

Explanation

Pathogenesis of multiple sclerosis

Settings

1
2
3
4
5
6
7
8
9
10
11
12
13
14
15
16
17
18
19
20
21
22
23
24
25
26
27
28
29
30

Item 2 of 40
Question Id: 919

Mark | Previous | Next | Full Screen | Tutorial | Lab Values | Notes | Calculator | Reverse Color | Text Zoom | Settings

Pathogenesis of multiple sclerosis

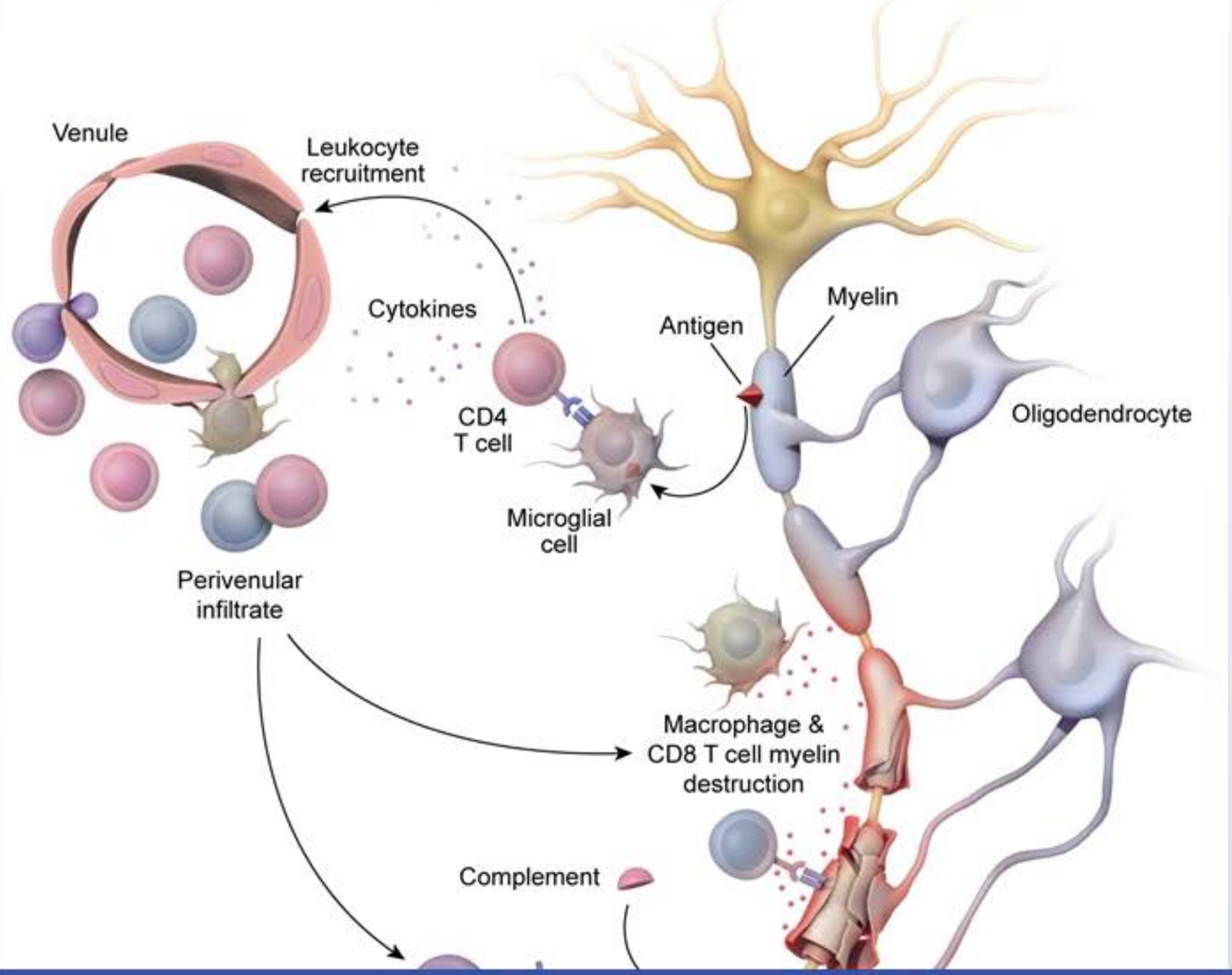

Block Time Remaining: 00:00:05
TUTOR

3 | Feedback | Suspend | End Block

Settings

1
2
3
4
5
6
7
8
9
10
11
12
13
14
15
16
17
18
19
20
21
22
23
24
25
26
27
28
29
30

Item 2 of 40
Question Id: 919

Mark | Previous | Next | Full Screen | Tutorial | Lab Values | Notes | Calculator | Reverse Color | Text Zoom | Settings

Venule

Leukocyte

Exhibit Display

Pathogenesis of multiple sclerosis

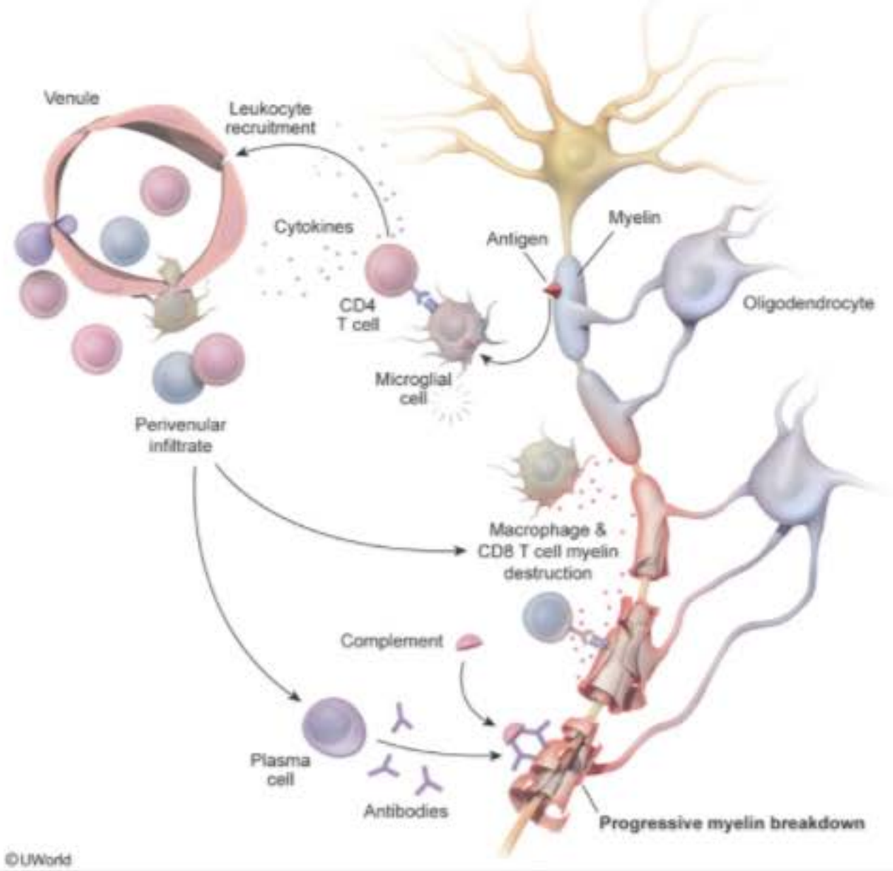

Zoom In | Zoom Out | Reset | Add To New Card | Existing Card

©UWorld

Block Time Remaining: 00:00:05
TUTOR

3 | Feedback | Suspend | End Block

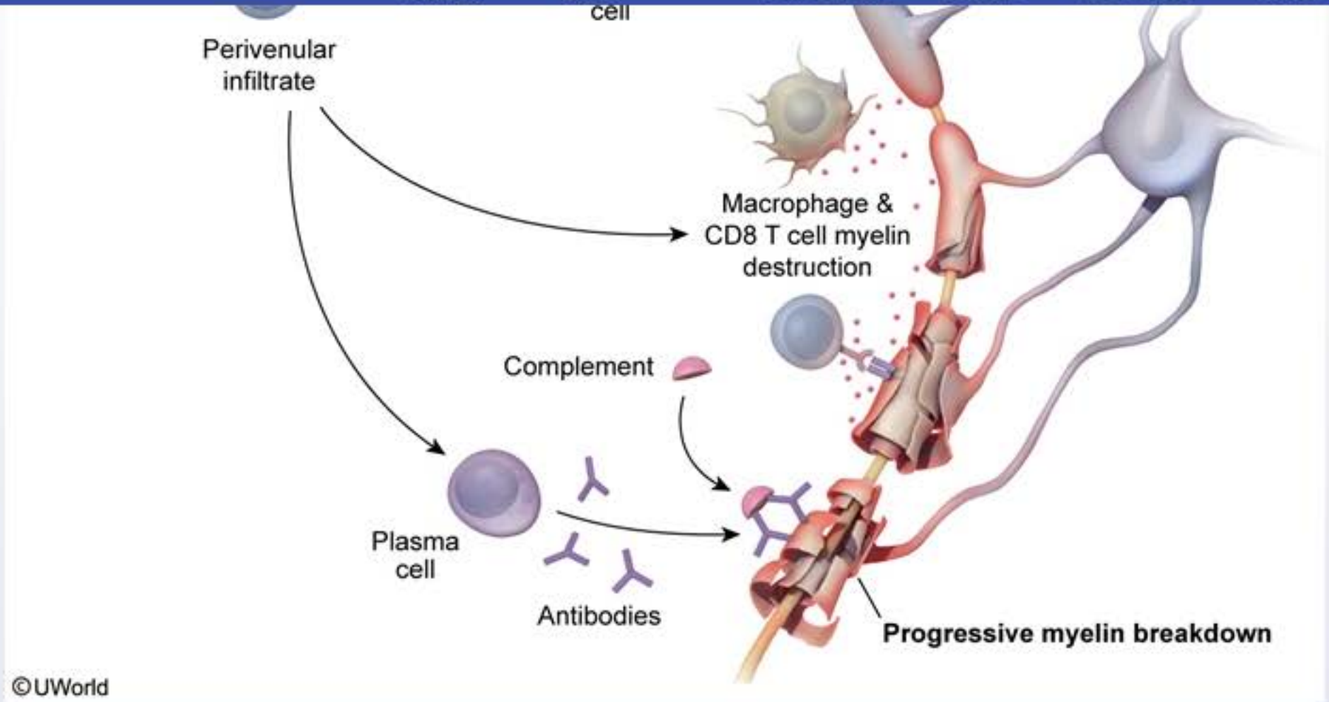

Reduced sensation and spasticity in the lower extremities suggest a lesion in the spinal cord. This, in conjunction with this patient's prior episode of blurred vision and her severe fatigue with exercise (Uhthoff's phenomenon), makes **multiple sclerosis** (MS) a likely diagnosis. MS is an immune-mediated disorder of the central nervous system (CNS), characterized by focal lesions of demyelination. Patients have various neurologic deficits that wax and wane (symptoms are disseminated across time and space).

Histologically, active MS plaques are characterized by **perivenular inflammatory infiltrates** made up primarily of autoreactive T lymphocytes and macrophages directed against myelin components. Extensive inflammation damages the blood-brain barrier, increasing inflammatory cell recruitment into the CNS (with the vessel wall remaining intact, unlike in CNS vasculitis). Infiltrating **macrophages containing myelin debris** are seen throughout the lesion, and recruitment of B lymphocytes to the perivascular spaces leads to the formation of myelin-specific antibodies. **Patchy demyelination** occurs, and while axons are typically spared, significant or prolonged disease may result in neuron death. Residual

of blurred vision and her severe fatigue with exercise (Uhthoff's phenomenon), makes **multiple sclerosis** (MS) a likely diagnosis. MS is an immune-mediated disorder of the central nervous system (CNS), characterized by focal lesions of demyelination. Patients have various neurologic deficits that wax and wane (symptoms are disseminated across time and space).

Histologically, active MS plaques are characterized by **perivenular inflammatory infiltrates** made up primarily of autoreactive T lymphocytes and macrophages directed against myelin components. Extensive inflammation damages the blood-brain barrier, increasing inflammatory cell recruitment into the CNS (with the vessel wall remaining intact, unlike in CNS vasculitis). Infiltrating **macrophages containing myelin debris** are seen throughout the lesion, and recruitment of B lymphocytes to the perivascular spaces leads to the formation of myelin-specific antibodies. **Patchy demyelination** occurs, and while axons are typically spared, significant or prolonged disease may result in neuron death. Residual chronic findings include hypertrophy and hyperplasia of astrocytes (glial scarring).

(Choice A) Microglial nodules are nonspecific findings that can be seen in patients with MS, as well as in those with HIV encephalopathy and other viral infections. They are thought to be reactive lesions that occur in the setting of inflammation, rather than a specific pathologic finding.

(Choice B) Neuritic plaques and neurofibrillary tangles (tau protein) are characteristic findings in Alzheimer disease, which presents with memory impairment, not focal neurologic deficits, and is rare in young patients.

(Choice D) Spongiform encephalopathy is seen in prion diseases (eg, bovine spongiform encephalopathy, Creutzfeldt-Jakob disease). Patients present with rapid-onset dementia, myoclonus, and ataxia. Episodic or waxing and waning symptoms are more consistent with MS.

(Choice E) Negri bodies are viral inclusions in the cytoplasm of nerve cells in patients with rabies. Rabies occurs after a bite from an infected animal and presents with tingling or irritation at the inoculation site followed by hydrophobia, delirium, coma, and death. This disease is typically fatal within days of symptom presentation and would not be expected to cause focal abnormalities over a period of months.

Educational objective:
Multiple sclerosis is an immune-mediated disorder of the central nervous system characterized by focal demyelination (plaques). Histologically, plaques contain foci of perivenular inflammatory infiltrates made up primarily of autoreactive T lymphocytes and macrophages. Patchy demyelination occurs followed by astrocyte hyperplasia (glial scarring).

Histologically, active MS plaques are characterized by **perivenular inflammatory infiltrates** made up primarily of autoreactive T lymphocytes and macrophages directed against myelin components. Extensive inflammation damages the blood-brain barrier, increasing inflammatory cell recruitment into the CNS (with the vessel wall remaining intact, unlike in CNS vasculitis). Infiltrating **macrophages containing myelin debris** are seen throughout the lesion, and recruitment of B lymphocytes to the perivascular spaces leads to the formation of myelin-specific antibodies. **Patchy demyelination** occurs, and while axons are typically spared, significant or prolonged disease may result in neuron death. Residual chronic findings include hypertrophy and hyperplasia of astrocytes (glial scarring).

(Choice A) Microglial nodules are nonspecific findings that can be seen in patients with MS, as well as in those with HIV encephalopathy and other viral infections. They are thought to be reactive lesions that occur in the setting of inflammation, rather than a specific pathologic finding.

(Choice B) Neuritic plaques and neurofibrillary tangles (tau protein) are characteristic findings in Alzheimer disease, which presents with memory impairment, not focal neurologic deficits, and is rare in young patients.

(Choice D) Spongiform encephalopathy is seen in prion diseases (eg, bovine spongiform encephalopathy, Creutzfeldt-Jakob disease). Patients present with rapid-onset dementia, myoclonus, and ataxia. Episodic or waxing and waning symptoms are more consistent with MS.

(Choice E) Negri bodies are viral inclusions in the cytoplasm of nerve cells in patients with rabies. Rabies occurs after a bite from an infected animal and presents with tingling or irritation at the inoculation site followed by hydrophobia, delirium, coma, and death. This disease is typically fatal within days of symptom presentation and would not be expected to cause focal abnormalities over a period of months.

Educational objective:
Multiple sclerosis is an immune-mediated disorder of the central nervous system characterized by focal demyelination (plaques). Histologically, plaques contain foci of perivenular inflammatory infiltrates made up primarily of autoreactive T lymphocytes and macrophages. Patchy demyelination occurs followed by astrocyte hyperplasia (glial scarring).

Pathology	Nervous System	Multiple sclerosis
Subject	System	Topic

Copyright © UWorld. All rights reserved.

Settings

1 2 3 4 5 6 7 8 9 10 11 12 13 14 15 16 17 18 19 20 21 22 23 24 25 26 27 28 29 30

Item 2 of 40
Question Id: 919

Mark | Previous | Next | Full Screen | Tutorial | Lab Values | Notes | Calculator | Reverse Color | Text Zoom | Settings

Histologically, active MS plaques are characterized by **perivenular inflammatory infiltrates** made up primarily of autoreactive T lymphocytes and

Exhibit Display

Alzheimer disease

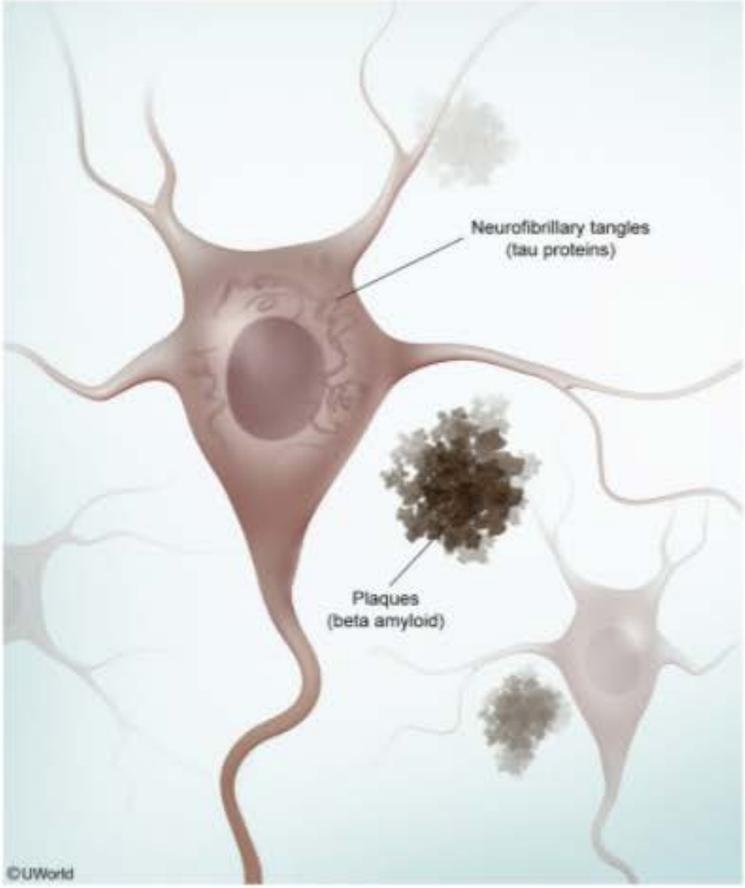

Zoom In | Zoom Out | Reset | Add To New Card | Existing Card

Block Time Remaining: 00:00:05
TUTOR

3 | Feedback | Suspend | End Block

Settings

1 2 3 4 5 6 7 8 9 10 11 12 13 14 15 16 17 18 19 20 21 22 23 24 25 26 27 28 29 30

Item 3 of 40
Question Id: 15659

Mark | Previous | Next | Full Screen | Tutorial | Lab Values | Notes | Calculator | Reverse Color | Text Zoom | Settings

A 56-year-old woman is brought to the emergency department after a generalized tonic-clonic seizure witnessed by her husband. The patient has no history of seizures or other medical conditions but has been having recurrent headaches for the past several months. Physical examination shows mild weakness with increased deep tendon reflexes in the left upper extremity. MR imaging of the brain reveals a large mass in the right frontal lobe. Stereotactic biopsy of the mass yields hypercellular white matter with extensive astrocytic aberration, microvascular proliferation, and areas of necrosis lined by tumor cells. Molecular studies of the abnormal cells are most likely to demonstrate which of the following findings?

A. Abnormal tuberin and hamartin proteins

B. Constitutively active RET protein

C. Lack of merlin tumor suppressor protein

D. Overexpression of epidermal growth factor receptor

E. Presence of Epstein-Barr virus genome

Submit

Block Time Remaining: 00:00:06
TUTOR

4 | Feedback | Suspend | End Block

A 56-year-old woman is brought to the emergency department after a generalized tonic-clonic seizure witnessed by her husband. The patient has no history of seizures or other medical conditions but has been having recurrent headaches for the past several months. Physical examination shows mild weakness with increased deep tendon reflexes in the left upper extremity. MR imaging of the brain reveals a large mass in the right frontal lobe. Stereotactic biopsy of the mass yields hypercellular white matter with extensive astrocytic aberration, microvascular proliferation, and areas of necrosis lined by tumor cells. Molecular studies of the abnormal cells are most likely to demonstrate which of the following findings?

A. Abnormal tuberin and hamartin proteins (14%)

B. Constitutively active RET protein (16%)

C. Lack of merlin tumor suppressor protein (19%)

✓ D. Overexpression of epidermal growth factor receptor (45%)

E. Presence of Epstein-Barr virus genome (4%)

Omitted
Correct answer
D

45%
Answered correctly

02 secs
Time Spent

02/01/2020
Last Updated

Explanation

This patient's seizure, headache, motor weakness, and brain mass composed of abnormal astrocytes raises strong suspicion for **glioblastoma** (GBM), a highly aggressive tumor that stems from **glial** or pluripotent neural stem cells. A number of characteristic oncogenic mutations are usually present in GBM, but >95% of cases are associated with the overexpression of **epidermal growth factor receptor** (EGFR) on the surface of neoplastic cells.

Explanation

This patient's seizure, headache, motor weakness, and brain mass composed of abnormal astrocytes raises strong suspicion for **glioblastoma** (GBM), a highly aggressive tumor that stems from **glial** or pluripotent neural stem cells. A number of characteristic oncogenic mutations are usually present in GBM, but >95% of cases are associated with the overexpression of **epidermal growth factor receptor** (EGFR) on the surface of neoplastic cells.

EGFR is a tyrosine-kinase signal transduction system that conducts external growth signals into the nucleus, thereby **promoting cellular survival** and proliferation. Mutations that enhance this pathway (eg, overexpression of EGFR or EGFR-ligand) are associated with uncontrolled cellular proliferation and are seen in GBM and other cancer types (eg, non–small cell lung cancer, breast cancer, prostate cancer). Therefore, drugs that inhibit the EGFR/EGFR-ligand interaction (eg, erlotinib) are often used as part of treatment.

(Choice A) Tuberous sclerosis is an autosomal dominant disorder associated with abnormal tuberin and hamartin. It generally causes benign tumors in the skin (eg, ash-leaf lesions, angiofibromas), central nervous system (hamartomas), and other tissues. Histopathology usually reveals large, elongated glial cells; necrosis and microvascular proliferation would be less typical.

(Choice B) Multiple endocrine neoplasia type 2 is an autosomal dominant disorder associated with constitutive activation to the RET proto-oncogene, leading to increased risk for medullary thyroid cancer, pheochromocytoma, and hyperparathyroidism. GBM is not classically linked to RET protein alterations.

(Choice C) Neurofibromatosis type 2 is due to mutations that inactivate the merlin tumor suppressor protein. It is associated with vestibular schwannomas and meningiomas; patients may also have eye and skin lesions. A frontal lobe mass would be unusual.

(Choice E) Primary CNS lymphoma often expresses Epstein-Barr virus (EBV) genes and is thought to be linked to EBV reactivation in B lymphocytes (the site of latent infection). However, biopsy would reveal immature lymphocytes, not astrocyte aberration.

Educational objective:
Glioblastoma is an aggressive primary brain neoplasm that generally presents with slowly worsening headache, seizure, and/or focal neurologic issues. Most cases are associated with oncogenic mutations that increase epidermal growth factor receptor expression on the tumor cells, leading to increased transduction of growth signals that promote cellular survival and proliferation.

Settings

1
2
3
4
5
6
7
8
9
10
11
12
13
14
15
16
17
18
19
20
21
22
23
24
25
26
27
28
29
30

Item 3 of 40
Question Id: 15659

Mark | Previous | Next | Full Screen | Tutorial | Lab Values | Notes | Calculator | Reverse Color | Text Zoom | Settings

Explanation

Exhibit Display

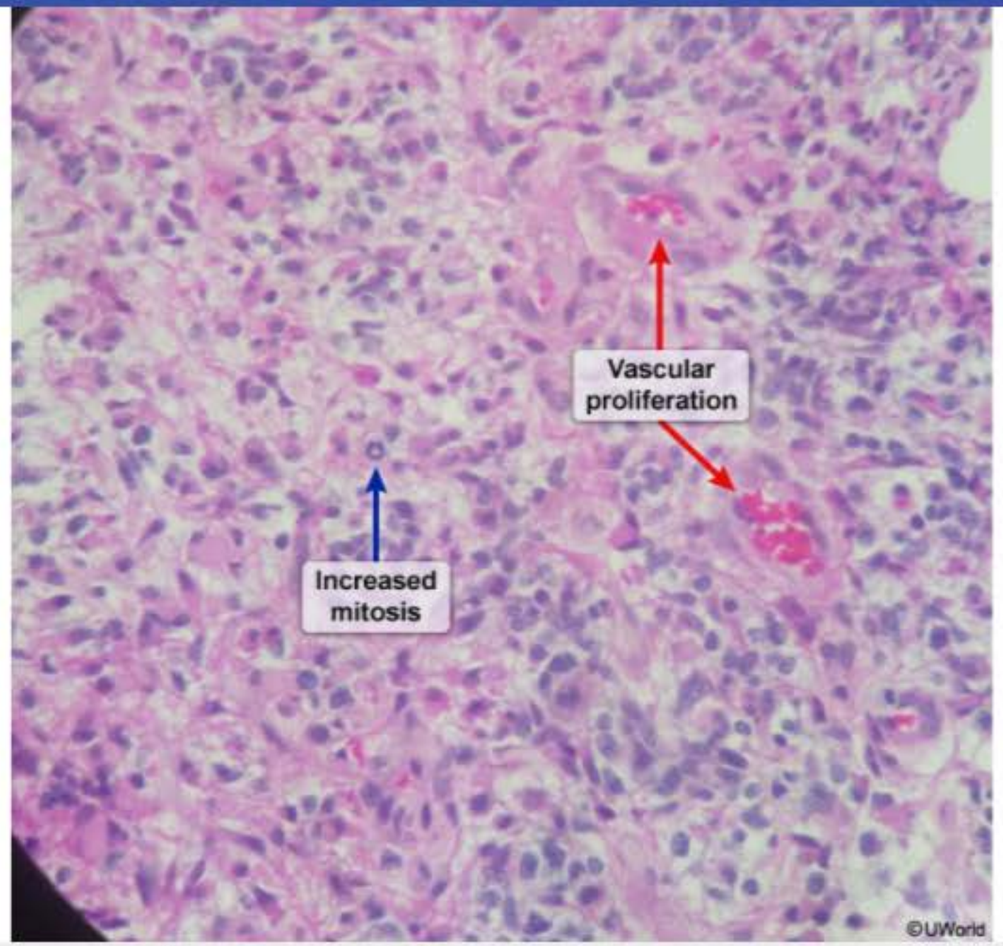

Zoom In | Zoom Out | Reset | Add To New Card | Existing Card

to increased transduction of growth signals that promote cellular survival and proliferation.

Block Time Remaining: 00:00:07
TUTOR

4 | Feedback | Suspend | End Block

Settings

1
2
3
4
5
6
7
8
9
10
11
12
13
14
15
16
17
18
19
20
21
22
23
24
25
26
27
28
29

Item 3 of 40
Question Id: 15659

Mark | Previous | Next | Full Screen | Tutorial | Lab Values | Notes | Calculator | Reverse Color | Text Zoom | Settings

Exhibit Display

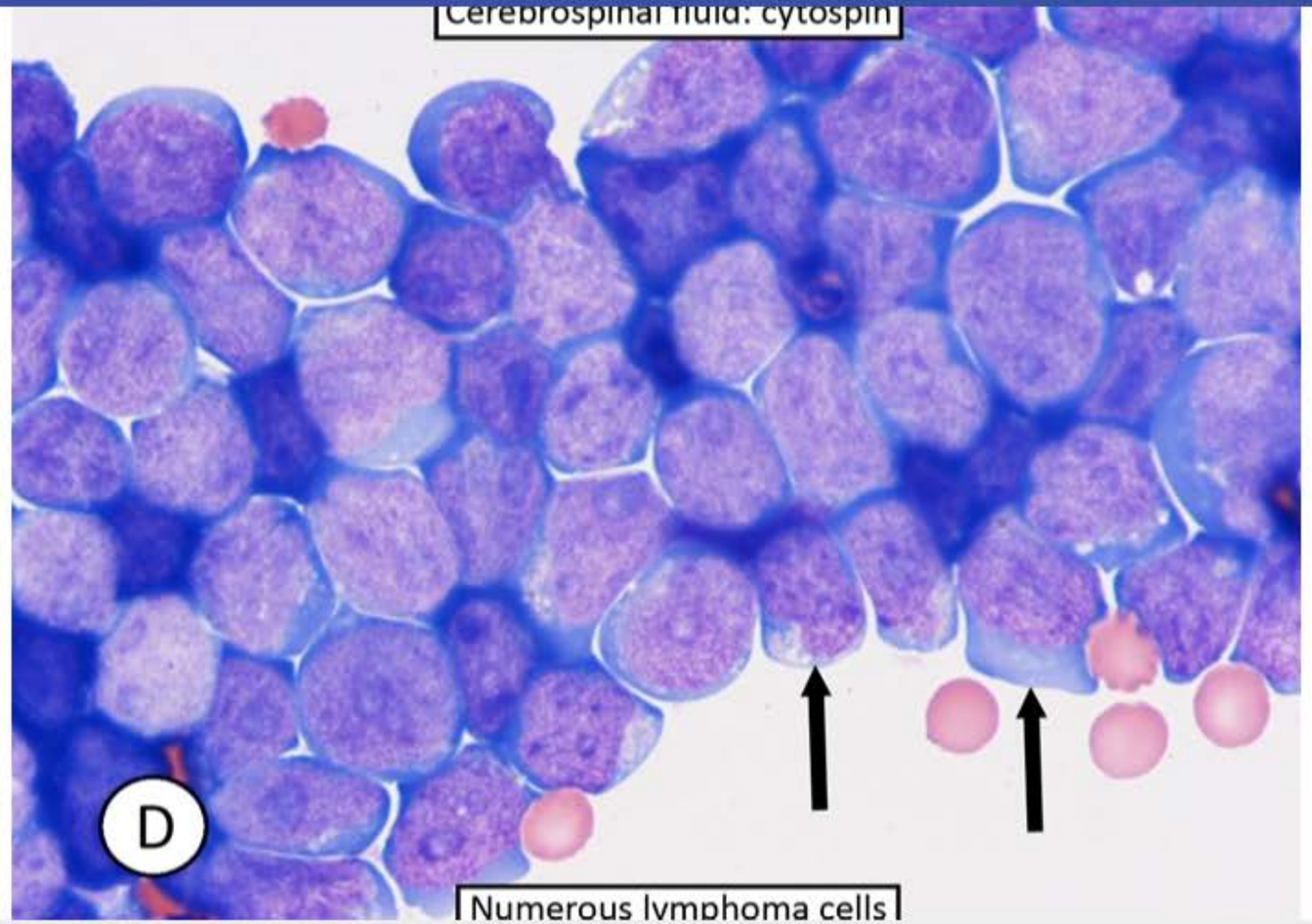

Zoom In | Zoom Out | Reset | Add To New Card | Existing Card

Block Time Remaining: 00:00:07
TUTOR

4 | Feedback | Suspend | End Block

EGFR is a tyrosine-kinase signal transduction system that conducts external growth signals into the nucleus, thereby **promoting cellular survival** and proliferation. Mutations that enhance this pathway (eg, overexpression of EGFR or EGFR-ligand) are associated with uncontrolled cellular proliferation and are seen in GBM and other cancer types (eg, non–small cell lung cancer, breast cancer, prostate cancer). Therefore, drugs that inhibit the EGFR/EGFR-ligand interaction (eg, erlotinib) are often used as part of treatment.

(Choice A) Tuberous sclerosis is an autosomal dominant disorder associated with abnormal tuberin and hamartin. It generally causes benign tumors in the skin (eg, ash-leaf lesions, angiofibromas), central nervous system (hamartomas), and other tissues. Histopathology usually reveals large, elongated glial cells; necrosis and microvascular proliferation would be less typical.

(Choice B) Multiple endocrine neoplasia type 2 is an autosomal dominant disorder associated with constitutive activation to the RET proto-oncogene, leading to increased risk for medullary thyroid cancer, pheochromocytoma, and hyperparathyroidism. GBM is not classically linked to RET protein alterations.

(Choice C) Neurofibromatosis type 2 is due to mutations that inactivate the merlin tumor suppressor protein. It is associated with vestibular schwannomas and meningiomas; patients may also have eye and skin lesions. A frontal lobe mass would be unusual.

(Choice E) Primary CNS lymphoma often expresses Epstein-Barr virus (EBV) genes and is thought to be linked to EBV reactivation in B lymphocytes (the site of latent infection). However, biopsy would reveal immature lymphocytes, not astrocyte aberration.

Educational objective:
Glioblastoma is an aggressive primary brain neoplasm that generally presents with slowly worsening headache, seizure, and/or focal neurologic issues. Most cases are associated with oncogenic mutations that increase epidermal growth factor receptor expression on the tumor cells, leading to increased transduction of growth signals that promote cellular survival and proliferation.

Pathology	Nervous System	Brain tumors
Subject	System	Topic

Copyright © UWorld. All rights reserved.

A 71-year-old woman is brought to the physician by her daughter. She says that her mother went shopping yesterday and could not find her way back home. Two years ago, her mother "started forgetting things like where she put her keys" and "began to have problems remembering the right words." Now she has trouble keeping up with her activities of daily living and refuses to pay her bills because "it's a waste of money." The patient's past medical history is unremarkable. Brain magnetic resonance imaging (MRI) is most likely to show atrophy of which of the following structures?

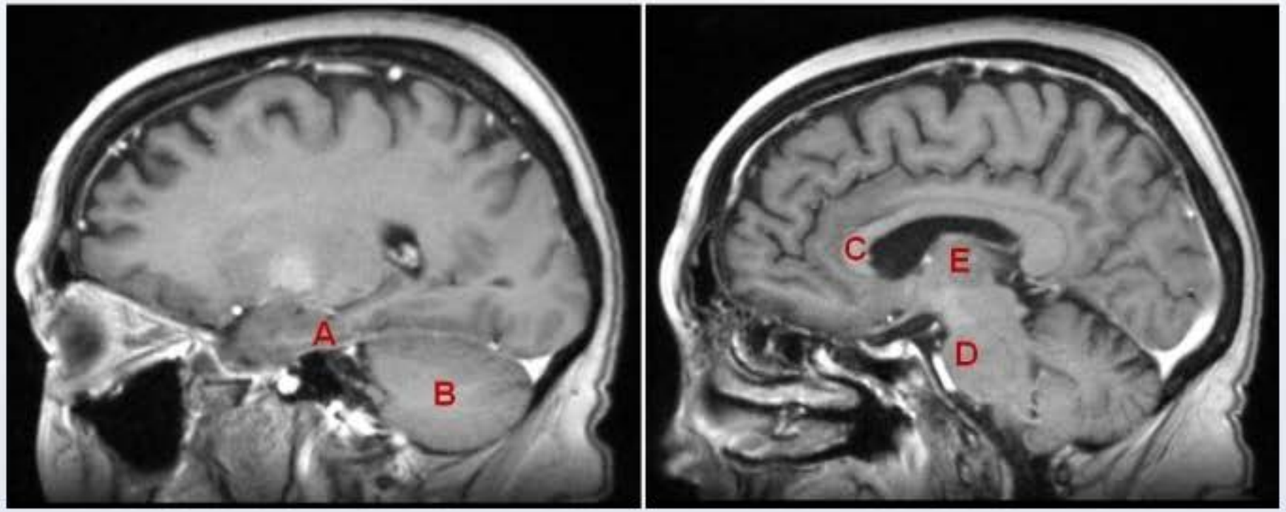

- A. A
- B. B
- C. C
- D. D
- E. E

Settings

1 2 3 4 5 6 7 8 9 10 11 12 13 14 15 16 17 18 19 20 21 22 23 24 25 26 27 28 29 30

Item 4 of 40
Question Id: 794

Mark | Previous | Next | Full Screen | Tutorial | Lab Values | Notes | Calculator | Reverse Color | Text Zoom | Settings

patient's past medical history is unremarkable. Brain magnetic resonance imaging (MRI) is most likely to show atrophy of which of the following structures?

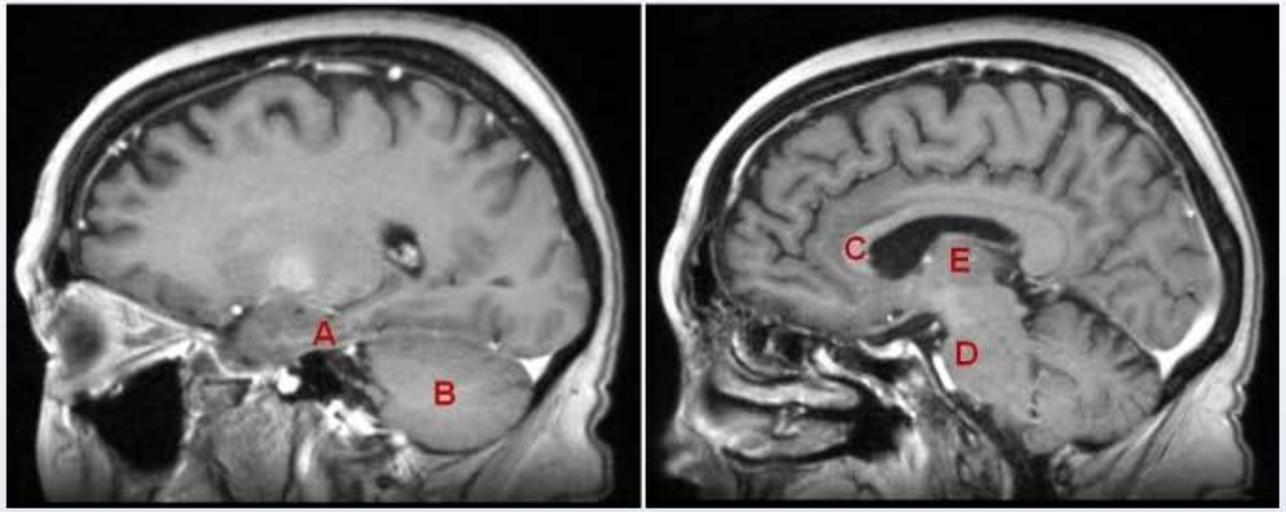

A. A
B. B
C. C
D. D
E. E

Submit

Block Time Remaining: 00:00:10
TUTOR

3 | Feedback | Suspend | End Block

Settings

1 2 3 4 5 6 7 8 9 10 11 12 13 14 15 16 17 18 19 20 21 22 23 24 25 26 27 28 29 30

Item 4 of 40
Question Id: 794

Mark | Previous | Next | Full Screen | Tutorial | Lab Values | Notes | Calculator | Reverse Color | Text Zoom | Settings

patient's past medical history is unremarkable. Brain magnetic resonance imaging (MRI) is most likely to show atrophy of which of the following structures?

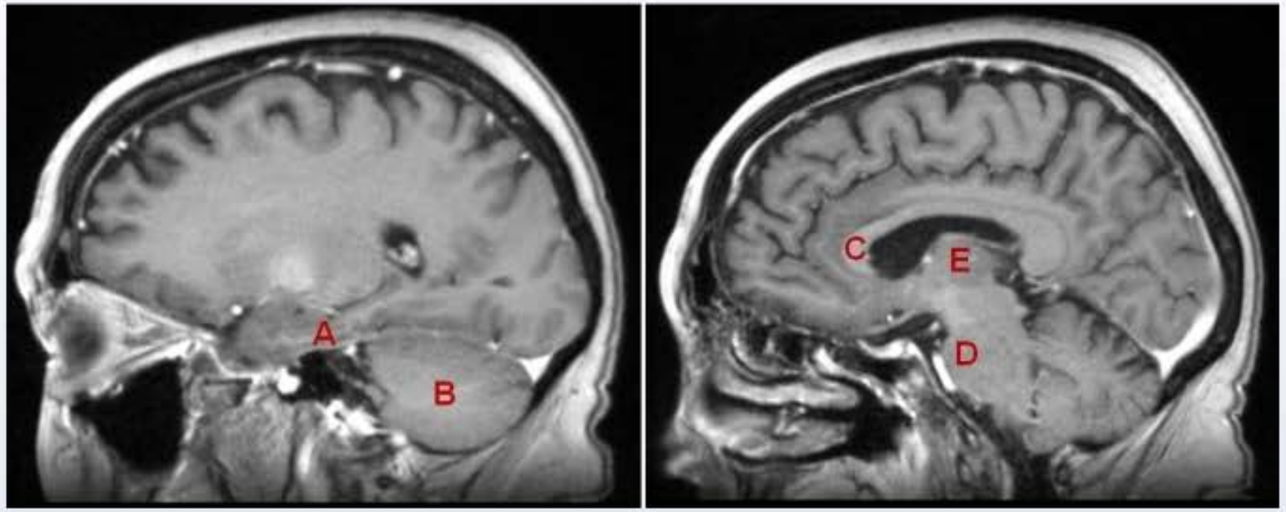

- ✓ A. A (57%)
- B. B (1%)
- C. C (19%)
- D. D (3%)
- E. E (17%)

Omitted
Correct answer

57%
Answered correctly

05 secs
Time Spent

02/12/2020
Last Updated

Block Time Remaining: 00:00:12
TUTOR

3 | Feedback | Suspend | End Block

Settings

1
2
3
4
5
6
7
8
9
10
11
12
13
14
15
16
17
18
19
20
21
22
23
24
25
26
27
28
29
30

Item 4 of 40
Question Id: 794

Mark | Previous | Next | Full Screen | Tutorial | Lab Values | Notes | Calculator | Reverse Color | Text Zoom | Settings

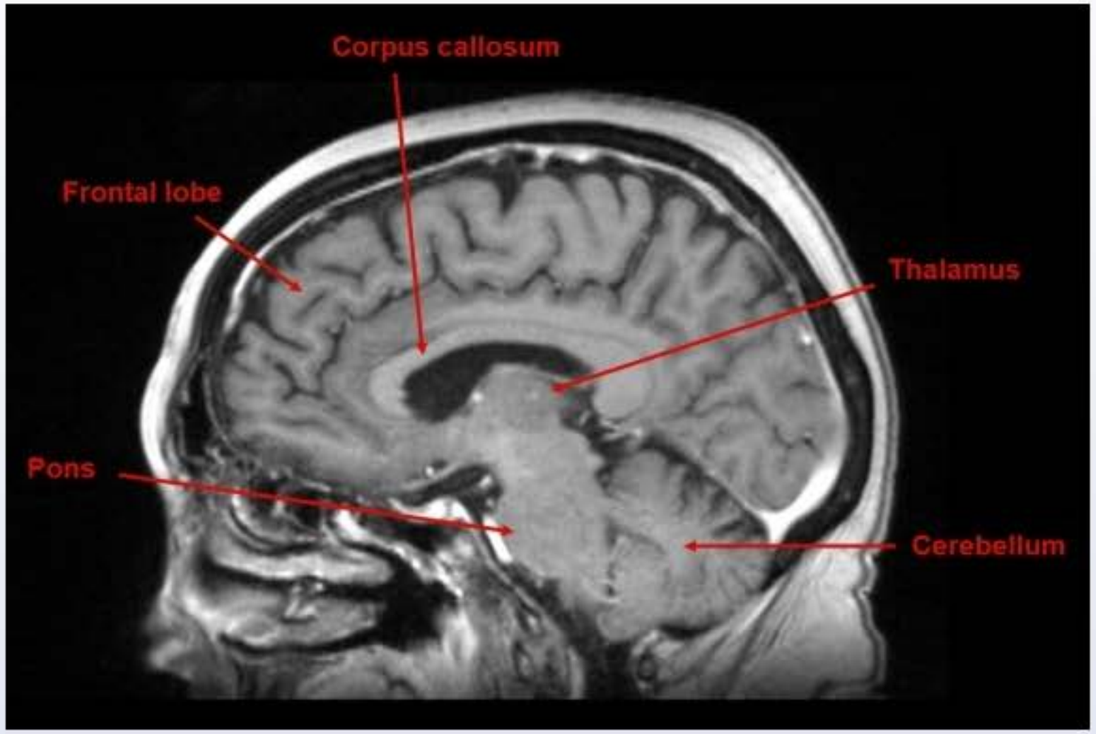

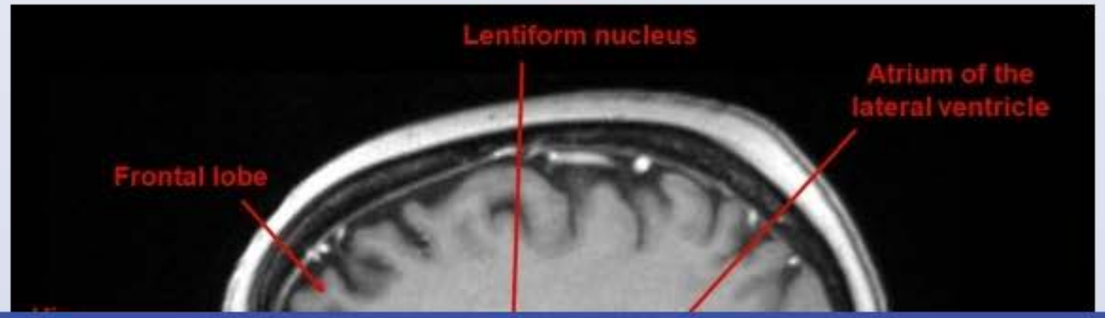

Block Time Remaining: 00:00:12
TUTOR

3 | Feedback | Suspend | End Block

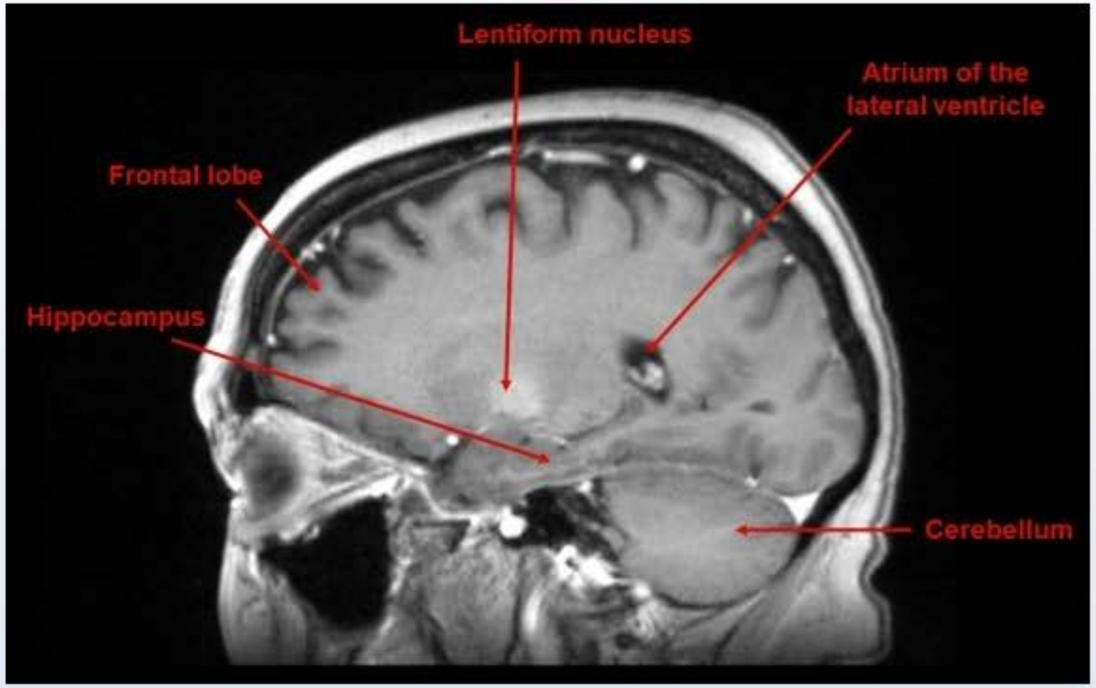

Alzheimer's disease is a neurodegenerative disorder that presents with insidiously progressive memory loss. It is the most common cause of dementia and usually affects people > 60 years of age. Language deficits (word-finding difficulty) and impaired visuospatial ability (misplacement of items) can occur early in the course of the disease. Later, as impairment in executive function and associated behavioral abnormalities become more pronounced, patients can have trouble performing everyday functions (eg, shopping, cooking, and managing money).

Advanced Alzheimer's disease is associated with diffuse brain atrophy. Atrophy is most pronounced in the temporoparietal lobes and hippocampus. Hippocampal atrophy is evident even in the early stages of the disease and can be detected by brain MRI.

The cerebellum **(Choice B)**, corpus callosum **(Choice C)**, pons **(Choice D)**, and thalamus **(Choice E)** are not obviously atrophied in Alzheimer's disease.

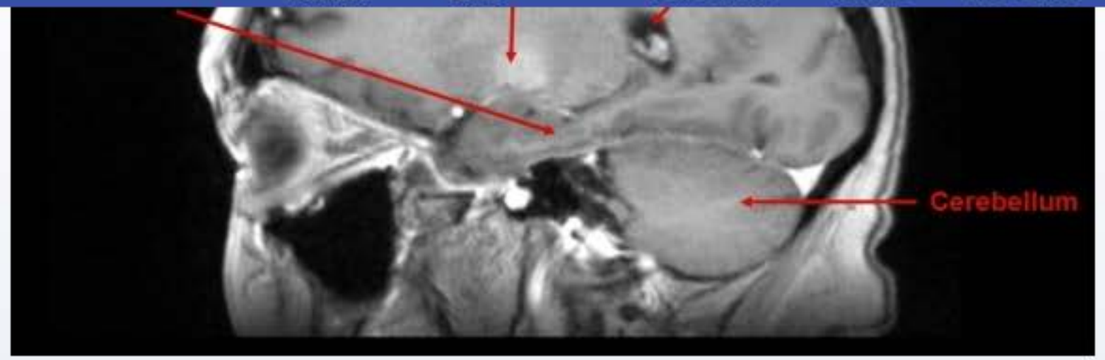

Alzheimer's disease is a neurodegenerative disorder that presents with insidiously progressive memory loss. It is the most common cause of dementia and usually affects people > 60 years of age. Language deficits (word-finding difficulty) and impaired visuospatial ability (misplacement of items) can occur early in the course of the disease. Later, as impairment in executive function and associated behavioral abnormalities become more pronounced, patients can have trouble performing everyday functions (eg, shopping, cooking, and managing money).

Advanced Alzheimer's disease is associated with diffuse brain atrophy. Atrophy is most pronounced in the temporoparietal lobes and hippocampus. Hippocampal atrophy is evident even in the early stages of the disease and can be detected by brain MRI.

The cerebellum **(Choice B)**, corpus callosum **(Choice C)**, pons **(Choice D)**, and thalamus **(Choice E)** are not obviously atrophied in Alzheimer's disease.

Educational objective:
The hippocampus is the area of the brain demonstrating the greatest degree of atrophy in Alzheimer's disease. Hippocampal atrophy on MRI is highly suggestive of the diagnosis.

Pathology	Nervous System	Alzheimer disease
Subject	System	Topic

Copyright © UWorld. All rights reserved.

Settings

1 2 3 4 5 6 7 8 9 10 11 12 13 14 15 16 17 18 19 20 21 22 23 24 25 26 27 28 29 30

Item 5 of 40
Question Id: 503

Mark | Previous | Next | Full Screen | Tutorial | Lab Values | Notes | Calculator | Reverse Color | Text Zoom | Settings

A 20-year-old woman comes to the physician because of multiple burns on her hands. She says that she gets burned quite often when she cooks, particularly while operating the oven. She also has burned herself when picking up her morning cup of coffee and when testing the water temperature in the shower. The patient is concerned because she cannot feel when objects are "really hot" and often does not notice that she has burns until she looks at her hands. She has no significant past medical history, no recent illnesses, and no sick contacts. Her surgical history is significant only for removal of impacted wisdom teeth 1 year ago. The patient has never smoked, drinks alcohol occasionally, and does not use illicit drugs. Her family history is significant for multiple sclerosis in her mother. Examination shows diminished pinprick and temperature sensation across the upper back, shoulders, and arms bilaterally. Light touch, position, and vibration sense are preserved. Examination of the lower extremities is unremarkable. Damage to which of the following spinal cord areas is most likely responsible for this patient's symptoms?

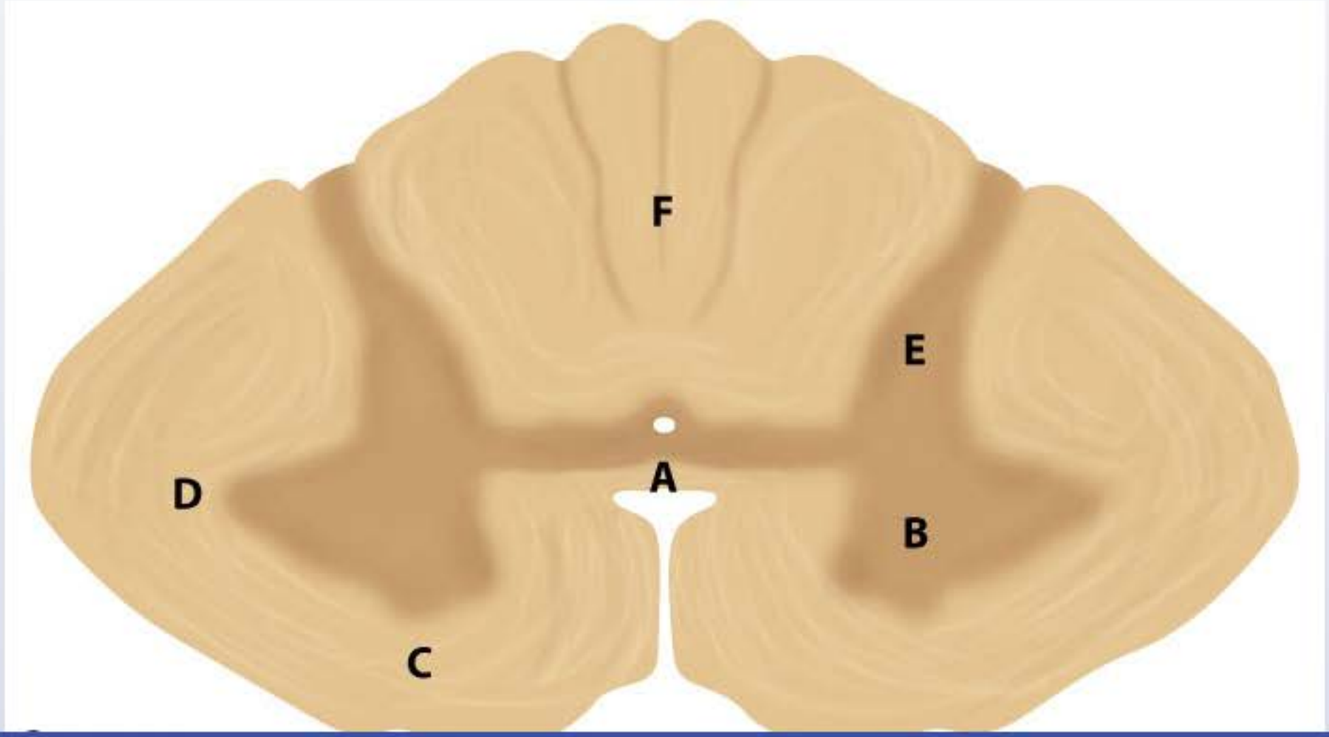

Block Time Remaining: 00:00:12
TUTOR

2 | Feedback | Suspend | End Block

Settings

1 2 3 4 5 6 7 8 9 10 11 12 13 14 15 16 17 18 19 20 21 22 23 24 25 26 27 28 29 30

Item 5 of 40
Question Id: 503

Mark | Previous | Next | Full Screen | Tutorial | Lab Values | Notes | Calculator | Reverse Color | Text Zoom | Settings

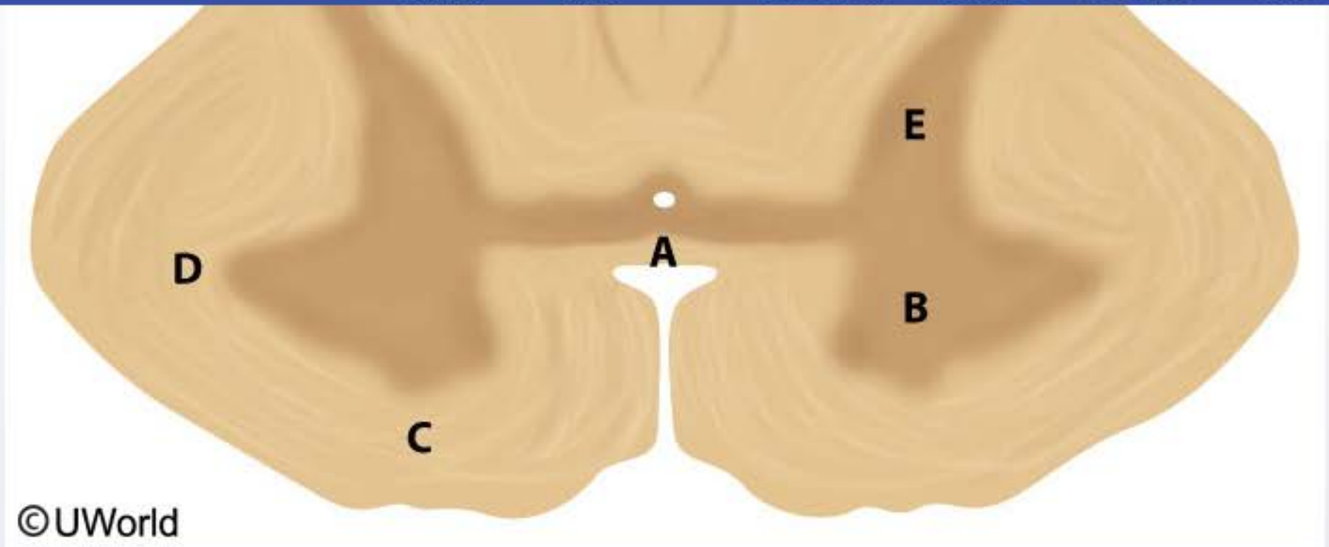

A. A
B. B
C. C
D. D
E. E
F. F

Submit

Block Time Remaining: 00:00:14
TUTOR

2 | Feedback | Suspend | End Block

burns until she looks at her hands. She has no significant past medical history, no recent illnesses, and no sick contacts. Her surgical history is significant only for removal of impacted wisdom teeth 1 year ago. The patient has never smoked, drinks alcohol occasionally, and does not use illicit drugs. Her family history is significant for multiple sclerosis in her mother. Examination shows diminished pinprick and temperature sensation across the upper back, shoulders, and arms bilaterally. Light touch, position, and vibration sense are preserved. Examination of the lower extremities is unremarkable. Damage to which of the following spinal cord areas is most likely responsible for this patient's symptoms?

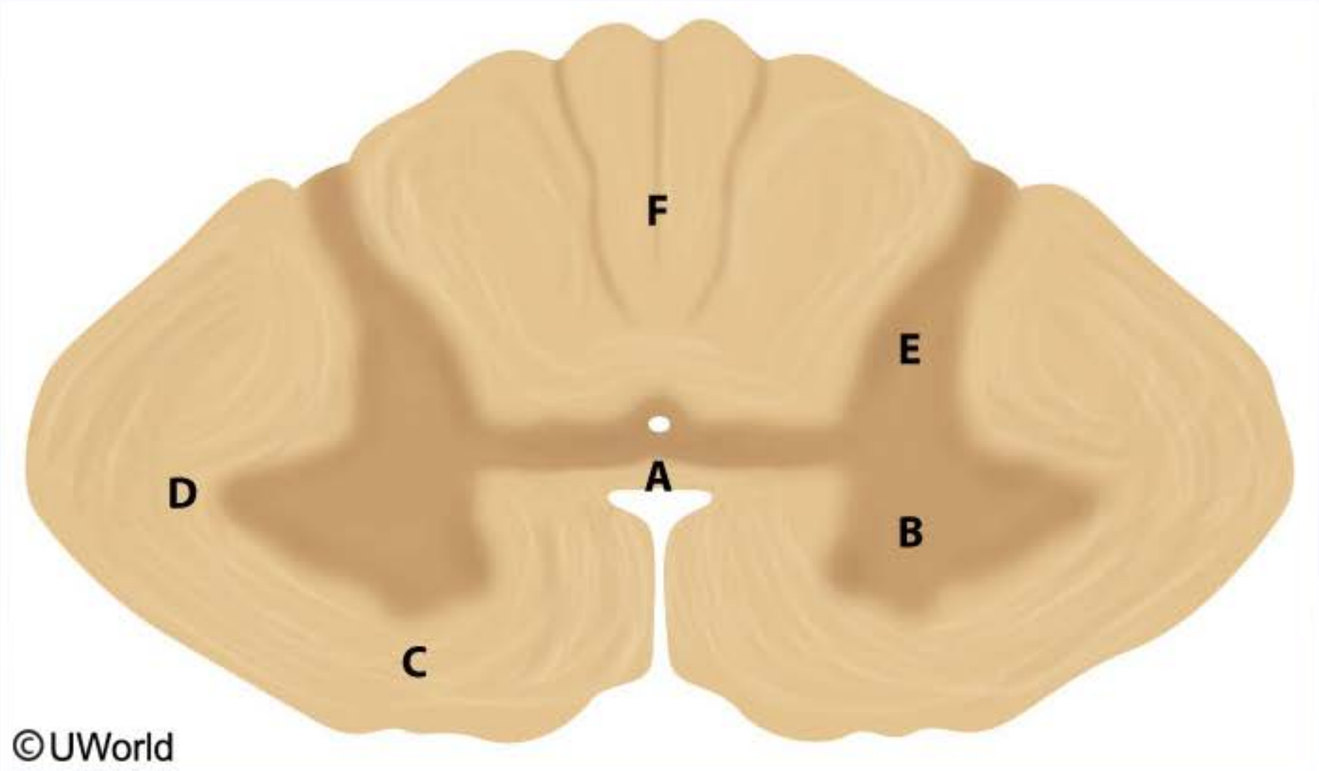

- A. A (62%)
- B. B (3%)

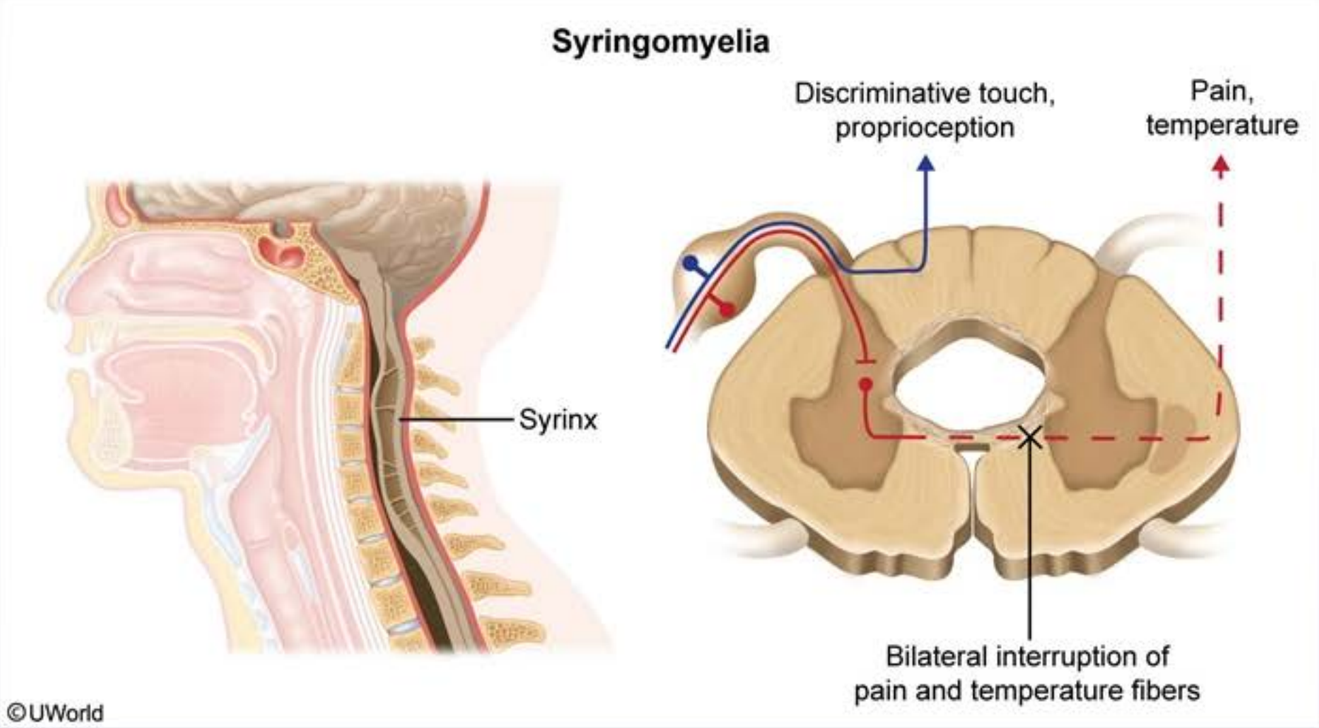

This patient most likely has **syringomyelia**, which classically presents with disproportionate **loss of pain and temperature sensation** (dissociated anesthesia) involving the **arms and hands**. In syringomyelia, a cerebrospinal fluid-filled cavity called a syrinx usually forms in the cervical region of the spinal cord. These cavities can enlarge over time and destroy adjacent portions of the spinal cord. The areas most commonly damaged are the ventral white commissure and ventral horns.

The ventral white commissure is located just anterior to the gray commissure. It is the area of decussation for the fibers of the lateral spinothalamic tract, which transmits pain and temperature sensation from peripheral receptors to the somatosensory cortex. Destruction of the **ventral white commissure** leads to loss of pain and temperature sensation bilaterally over the affected dermatomes (starting 1 to 2 levels below

©UWorld

This patient most likely has **syringomyelia**, which classically presents with disproportionate **loss of pain and temperature sensation** (dissociated anesthesia) involving the **arms and hands**. In syringomyelia, a cerebrospinal fluid-filled cavity called a syrinx usually forms in the cervical region of the spinal cord. These cavities can enlarge over time and destroy adjacent portions of the spinal cord. The areas most commonly damaged are the ventral white commissure and ventral horns.

The ventral white commissure is located just anterior to the gray commissure. It is the area of decussation for the fibers of the lateral spinothalamic tract, which transmits pain and temperature sensation from peripheral receptors to the somatosensory cortex. Destruction of the **ventral white commissure** leads to loss of pain and temperature sensation bilaterally over the affected dermatomes (starting 1 to 2 levels below the lesion, as the axons briefly ascend in the zone of Lissauer before decussating). Touch, vibration, and position senses are preserved as the dorsal columns remain intact.

(Choice B) The **ventral horns** contain lower motor neurons that receive impulses from the lateral corticospinal tract. Damage to the ventral horn can occur in syringomyelia, but would cause flaccid paralysis and atrophy of the intrinsic hand muscles (not loss of pain and temperature sensation).

(Choice C) The ventral spinothalamic tract is located in this area and transmits crude touch and pressure sensation. It should not be confused with the lateral spinothalamic tract, which carries pain and temperature sensation.

(Choice D) After decussating in the ventral white commissure, axons of the lateral spinothalamic tract ascend to the brain in the lateral funiculus. Damage to this area would cause contralateral loss of pain and temperature sensation distally, beginning 1 to 2 segments below the lesion. However, bilateral sensory loss would not occur with damage to this area.

(Choice E) The dorsal horn contains first order axons and second order neurons that transmit sensory input from peripheral receptors. Damage to the dorsal horn would likely result in unilateral loss of all sensation over the affected dermatomes.

(Choice F) The dorsal column contains both the gracile and cuneate fasciculi. They are formed by axons of first-order neurons of the dorsal column pathway. This tract is the primary mediator of proprioception, vibration, and tactile sensation.

Educational objective:

Settings

1
2
3
4
5
6
7
8
9
10
11
12
13
14
15
16
17
18
19
20
21
22
23
24
25
26
27
28
29
30

Item 5 of 40
Question Id: 503

Mark | Previous | Next | Full Screen | Tutorial | Lab Values | Notes | Calculator | Reverse Color | Text Zoom | Settings

©UWorld

Exhibit Display

Anterolateral pathway

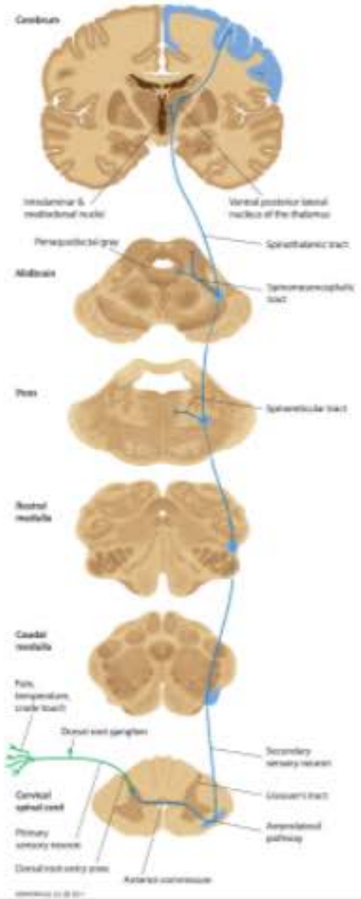

Zoom In | Zoom Out | Reset | Add To New Card | Existing Card

Educational objective:

Block Time Remaining: 00:00:16
TUTOR

2 | Feedback | Suspend | End Block

Settings

Exhibit Display

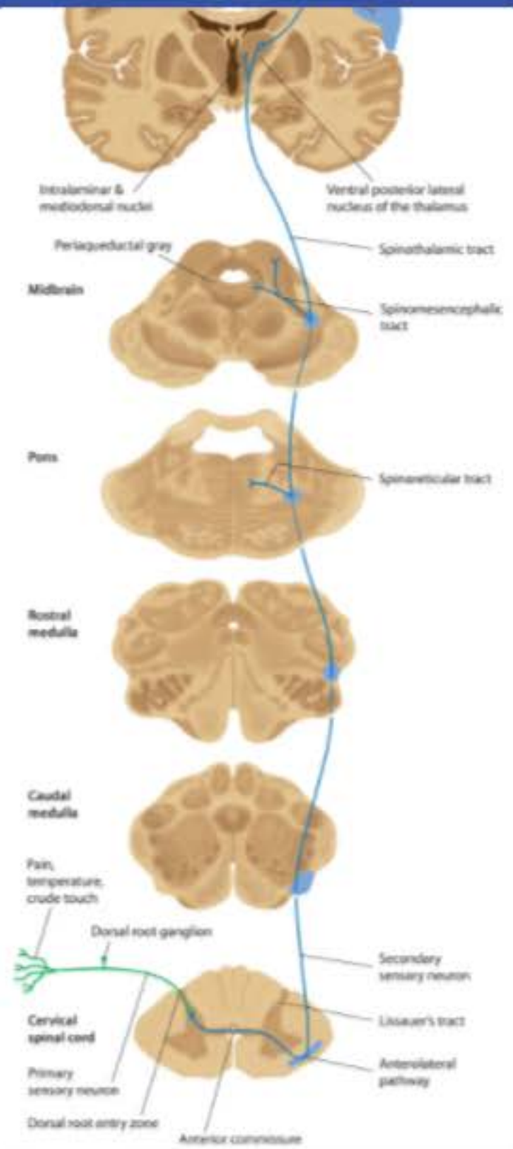

Zoom In | Zoom Out | Reset | Add To New Card | Existing Card

educational objective.

Settings

Item 5 of 40

Question Id: 503

Mark

Previous

Next

Full Screen

Tutorial

Lab Values

Notes

Calculator

Reverse Color

Text Zoom

©UWorld

Exhibit Display

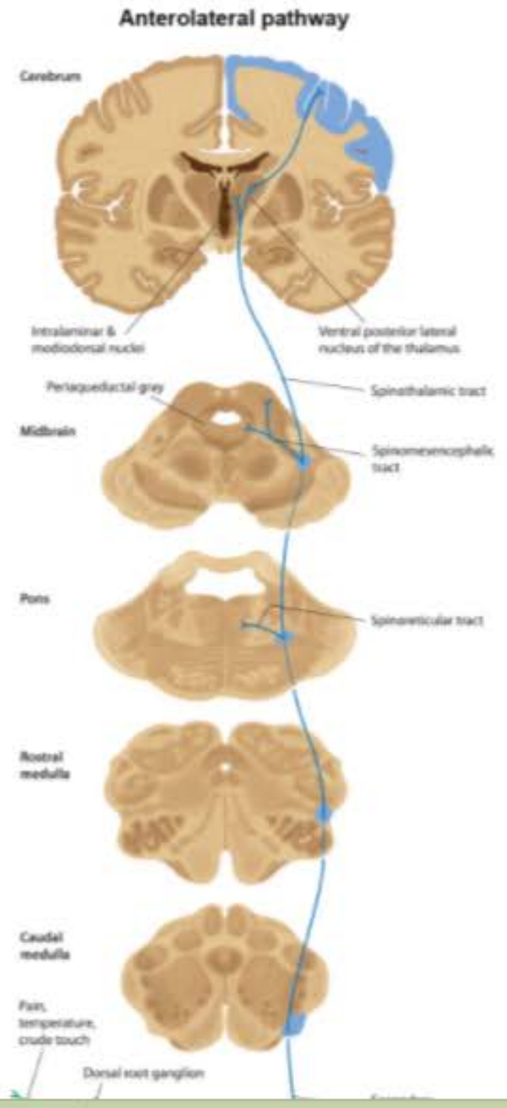

can occur in syringomyelia, but would cause flaccid paralysis and atrophy of the intrinsic hand muscles (not loss of pain and temperature sensation).

(Choice C) The ventral spinothalamic tract is located in this area and transmits crude touch and pressure sensation. It should not be confused with the lateral spinothalamic tract, which carries pain and temperature sensation.

(Choice D) After decussating in the ventral white commissure, axons of the lateral spinothalamic tract ascend to the brain in the lateral funiculus. Damage to this area would cause contralateral loss of pain and temperature sensation distally, beginning 1 to 2 segments below the lesion. However, bilateral sensory loss would not occur with damage to this area.

(Choice E) The dorsal horn contains first order axons and second order neurons that transmit sensory input from peripheral receptors. Damage to the dorsal horn would likely result in unilateral loss of all sensation over the affected dermatomes.

(Choice F) The dorsal column contains both the gracile and cuneate fasciculi. They are formed by axons of first-order neurons of the dorsal column pathway. This tract is the primary mediator of proprioception, vibration, and tactile sensation.

Educational objective:
Syringomyelia is characterized by the formation of a cavity (syrinx) in the cervical region of the spinal cord. The syrinx damages the ventral white commissure, leading to bilateral loss of pain and temperature sensation that is limited to the affected levels (typically the arms and hands); distal sensation is preserved. Destruction of the motor neurons in the ventral horns (due to extension of the syrinx) results in flaccid paralysis and atrophy of the intrinsic muscles of the hand.

References

- Syringomyelia.

Pathology	Nervous System	Syringomyelia
Subject	System	Topic

Copyright © UWorld. All rights reserved.

Settings

1 2 3 4 5 6 7 8 9 10 11 12 13 14 15 16 17 18 19 20 21 22 23 24 25 26 27 28 29 30

Item 6 of 40
Question Id: 504

Mark | Previous | Next | Full Screen | Tutorial | Lab Values | Notes | Calculator | Reverse Color | Text Zoom | Settings

A 21-year-old woman comes to the office due to a long history of episodic headaches, dizziness, and gait imbalance. The headaches are located in the occipital region, are characterized as dull, and last for several hours. Physical examination reveals gait ataxia but no focal weakness or sensory loss. MRI of the brain shows low-lying cerebellar tonsils extending below the plane of the foramen magnum into the vertebral canal. Which of the following is the most likely cause of this patient's condition?

A. Autoimmune disease
B. Congenital malformation
C. Germline mutation
D. Neoplastic disease
E. Sequelae of prior trauma
F. Vascular disease

Submit

Block Time Remaining: 00:00:16
TUTOR

3 | Feedback | Suspend | End Block

1 2 3 4 5 6 7 8 9 10 11 12 13 14 15 16 17 18 19 20 21 22 23 24 25 26 27 28 29 30

A 21-year-old woman comes to the office due to a long history of episodic headaches, dizziness, and gait imbalance. The headaches are located in the occipital region, are characterized as dull, and last for several hours. Physical examination reveals gait ataxia but no focal weakness or sensory loss. MRI of the brain shows low-lying cerebellar tonsils extending below the plane of the foramen magnum into the vertebral canal. Which of the following is the most likely cause of this patient's condition?

- A. Autoimmune disease (1%)
- ✓ B. Congenital malformation (87%)
- C. Germline mutation (0%)
- D. Neoplastic disease (5%)
- E. Sequelae of prior trauma (3%)
- F. Vascular disease (1%)

Omitted
Correct answer
B

87%
Answered correctly

02 secs
Time Spent

06/27/2020
Last Updated

Explanation

Chiari malformations are a group of **congenital** disorders caused by underdevelopment of the posterior fossa. The small size of the fossa causes parts of the **cerebellum** and medulla to **herniate through** the **foramen magnum**. There are 2 types of Chiari malformations. Chiari type I is the most common and benign, and is characterized by low-lying cerebellar tonsils that extend below the foramen magnum into the vertebral

Chiari malformations are a group of **congenital** disorders caused by underdevelopment of the posterior fossa. The small size of the fossa causes parts of the **cerebellum** and medulla to **herniate through** the **foramen magnum**. There are 2 types of Chiari malformations. Chiari type I is the most common and benign, and is characterized by low-lying cerebellar tonsils that extend below the foramen magnum into the vertebral canal. Patients typically present during adolescence/adulthood with paroxysmal occipital headaches (due to meningeal irritation) and cerebellar dysfunction (eg, dizziness, ataxia) due to compression of the cerebellar tonsils.

Chiari type II, Arnold-Chiari malformation, is more severe and typically becomes evident during the neonatal period. It is characterized by downward displacement of the cerebellum (vermis, tonsils) and medulla through the foramen magnum. Non-communicating hydrocephalus almost always occurs due to aqueductal stenosis. Compression of the medulla may result in dysphagia, stridor, and apnea. Patients also often have an associated lumbar myelomeningocele, which can cause lower limb paralysis.

(Choice A) Multiple sclerosis is an autoimmune demyelinating disorder of the central nervous system that typically presents in young adult women with neurologic deficits disseminated in space and time. Neuroimaging typically shows periventricular white matter lesions.

(Choice C) Friedreich ataxia is an autosomal recessive trinucleotide repeat disorder that presents during childhood with ataxia, loss of vibration/proprioception sense, and skeletal abnormalities (eg, kyphoscoliosis, pes cavus).

(Choice D) Cerebellar neoplasms (eg, medulloblastoma, pilocytic astrocytoma) often present in children with symptoms of increased intracranial pressure (eg, headache, vomiting) and cerebellar dysfunction. However, the absence of a cerebellar tumor on neuroimaging makes this unlikely.

(Choice E) Traumatic brain injury can cause headache and neurologic impairment; however, this patient's MRI findings are highly characteristic of Chiari type I malformation.

(Choice F) Cerebellar stroke may present with acute-onset occipital headache, dizziness, and ataxia. However, this patient's young age, absence of cardiovascular risk factors, and long history of episodic symptoms make this less likely.

Educational objective:
Chiari malformations are congenital disorders that result from underdevelopment of the posterior fossa, causing parts of the cerebellum and medulla to herniate through the foramen magnum. Chiari type I is relatively benign and presents during adulthood with occipital headache and cerebellar dysfunction. Chiari type II is a more severe form that affects neonates and is often associated with lumbar myelomeningocele and

Settings

1
2
3
4
5
6
7
8
9
10
11
12
13
14
15
16
17
18
19
20
21
22
23
24
25
26
27
28
29
30

Item 6 of 40
Question Id: 504

Mark | Previous | Next | Full Screen | Tutorial | Lab Values | Notes | Calculator | Reverse Color | Text Zoom | Settings

Chiari malformations are a group of **congenital** disorders caused by underdevelopment of the posterior fossa. The small size of the fossa

Exhibit Display

Zoom In | Zoom Out | Reset | Add To New Card | Existing Card

cerebellar dysfunction. Chiari type II is a more severe form that affects neonates and is often associated with lumbar myelomeningocele and

Block Time Remaining: 00:00:18
TUTOR

3 | Feedback | Suspend | End Block

have an associated lumbar myelomeningocele, which can cause lower limb paralysis.

(Choice A) Multiple sclerosis is an autoimmune demyelinating disorder of the central nervous system that typically presents in young adult women with neurologic deficits disseminated in space and time. Neuroimaging typically shows periventricular white matter lesions.

(Choice C) Friedreich ataxia is an autosomal recessive trinucleotide repeat disorder that presents during childhood with ataxia, loss of vibration/proprioception sense, and skeletal abnormalities (eg, kyphoscoliosis, pes cavus).

(Choice D) Cerebellar neoplasms (eg, medulloblastoma, pilocytic astrocytoma) often present in children with symptoms of increased intracranial pressure (eg, headache, vomiting) and cerebellar dysfunction. However, the absence of a cerebellar tumor on neuroimaging makes this unlikely.

(Choice E) Traumatic brain injury can cause headache and neurologic impairment; however, this patient's MRI findings are highly characteristic of Chiari type I malformation.

(Choice F) Cerebellar stroke may present with acute-onset occipital headache, dizziness, and ataxia. However, this patient's young age, absence of cardiovascular risk factors, and long history of episodic symptoms make this less likely.

Educational objective:
Chiari malformations are congenital disorders that result from underdevelopment of the posterior fossa, causing parts of the cerebellum and medulla to herniate through the foramen magnum. Chiari type I is relatively benign and presents during adulthood with occipital headache and cerebellar dysfunction. Chiari type II is a more severe form that affects neonates and is often associated with lumbar myelomeningocele and hydrocephalus.

References

- The Chiari malformations.

Pathology	Nervous System	Chiari malformation
Subject	System	Topic

Copyright © UWorld. All rights reserved.

Settings

1 2 3 4 5 6 7 8 9 10 11 12 13 14 15 16 17 18 19 20 21 22 23 24 25 26 27 28 29 30

Item 7 of 40
Question Id: 594

Mark | Previous | Next | Full Screen | Tutorial | Lab Values | Notes | Calculator | Reverse Color | Text Zoom | Settings

A 54-year-old man is brought to the office by his daughter. She says that her father has been acting strangely over the past 2 years. He makes inappropriate sexual jokes, has little regard for social rules, is often irritable, and is borderline aggressive at times. The patient denies that his personality is any different from normal. When speaking with the patient, the physician notices that he has minimal verbal output and repeats "it is what it is" when asked questions about his strange behavior. On physical examination, he appears unkempt but otherwise has no significant findings. This patient most likely has a condition that predominantly involves which of the following structures?

- A. Anterior temporal and prefrontal cortices
- B. Caudate nucleus and putamen
- C. Locus ceruleus and substantia nigra
- D. Mamillary bodies and medial thalamus
- E. Medial temporal and parietal cortices
- F. Parietal and occipital cortices

Submit

Block Time Remaining: 00:00:18
TUTOR

5 | Feedback | Suspend | End Block

Settings

1 2 3 4 5 6 7 8 9 10 11 12 13 14 15 16 17 18 19 20 21 22 23 24 25 26 27 28 29 30

Item 7 of 40
Question Id: 594

Mark | Previous | Next | Full Screen | Tutorial | Lab Values | Notes | Calculator | Reverse Color | Text Zoom | Settings

A 54-year-old man is brought to the office by his daughter. She says that her father has been acting strangely over the past 2 years. He makes inappropriate sexual jokes, has little regard for social rules, is often irritable, and is borderline aggressive at times. The patient denies that his personality is any different from normal. When speaking with the patient, the physician notices that he has minimal verbal output and repeats "it is what it is" when asked questions about his strange behavior. On physical examination, he appears unkempt but otherwise has no significant findings. This patient most likely has a condition that predominantly involves which of the following structures?

- ✓ A. Anterior temporal and prefrontal cortices (78%)
- B. Caudate nucleus and putamen (7%)
- C. Locus ceruleus and substantia nigra (1%)
- D. Mamillary bodies and medial thalamus (5%)
- E. Medial temporal and parietal cortices (6%)
- F. Parietal and occipital cortices (0%)

Omitted
Correct answer
A

78%
Answered correctly

01 sec
Time Spent

02/09/2020
Last Updated

Explanation

Differential diagnosis of dementia subtypes	

Block Time Remaining: 00:00:19
TUTOR

5 | Feedback | Suspend | End Block

Differential diagnosis of dementia subtypes	
Alzheimer disease	• Early, insidious short-term memory loss • Language deficits & spatial disorientation • Later personality changes
Vascular dementia	• Stepwise decline • Early executive dysfunction • Cerebral infarction &/or deep white matter changes on neuroimaging
Frontotemporal dementia	• Early personality changes • Apathy, disinhibition & compulsive behavior • Frontotemporal atrophy on neuroimaging
Dementia with Lewy bodies	• Visual hallucinations • Spontaneous parkinsonism • Fluctuating cognition
Normal-pressure hydrocephalus	• Ataxia early in disease • Urinary incontinence • Dilated ventricles on neuroimaging
Prion disease	• Behavioral changes • Rapid progression • Myoclonus &/or seizures

This patient's **personality and behavioral changes** (eg, disinhibition, apathy, social inappropriateness, compulsive behaviors) and altered speech patterns (eg, paucity of speech, repeated phrases) are consistent with a diagnosis of behavioral variant **frontotemporal dementia** (FTD).

- Myoclonus &/or seizures

This patient's **personality and behavioral changes** (eg, disinhibition, apathy, social inappropriateness, compulsive behaviors) and altered speech patterns (eg, paucity of speech, repeated phrases) are consistent with a diagnosis of behavioral variant **frontotemporal dementia** (FTD). Personality and behavioral changes present early in the disease course with neurocognitive deficits occurring later. FTD is highly heritable and a common cause of early-onset dementia.

FTD is characterized by initial **degeneration** of the prefrontal cortex that eventually progresses to include the anterior **temporal cortex**. Loss of function in the **prefrontal cortex** can cause inappropriate behavior, impaired judgment, and poor problem-solving skills (ie, executive dysfunction).

(Choice B) The caudate nucleus and putamen are basal ganglia structures that together form the dorsal striatum, which regulates voluntary movements. Huntington disease causes atrophy of the dorsal striatum (there is greater relative atrophy of the caudate) and presents with choreiform movements, psychiatric symptoms (eg, irritability, depression), and dementia. This patient's prominent personality changes and lack of a movement disorder are not characteristic of Huntington disease.

(Choice C) Neuronal loss in the locus ceruleus and substantia nigra is seen in Parkinson disease, which typically presents with tremor, bradykinesia, and rigidity. The locus ceruleus is a pontine structure that is one of the primary areas of norepinephrine synthesis in the brain. The substantia nigra, located in the midbrain, contains dopaminergic neurons whose axons project to the striatum (nigrostriatal pathway) and participate in regulation of voluntary movements.

(Choice D) Damage to the mammillary bodies and medial thalamus is characteristic of chronic Wernicke encephalopathy and Korsakoff syndrome. Both disorders result from chronic thiamine deficiency, most often in the context of heavy alcohol use.

(Choice E) Medial temporal and parietal cortical atrophy is characteristic of Alzheimer disease. The medial temporal lobe contains the hippocampus, a structure involved in the formation of new memories.

(Choice F) Disproportionate atrophy of the parietal and occipital cortices is seen in posterior cortical atrophy, an atypical variant of Alzheimer disease with prominent visual symptoms.

Educational objective:
Frontotemporal dementia is associated with pronounced atrophy of the prefrontal cortex with later degeneration of the anterior temporal cortex. It

Settings

1 2 3 4 5 6 7 8 9 10 11 12 13 14 15 16 17 18 19 20 21 22 23 24 25 26 27 28 29 30

Item 7 of 40
Question Id: 594

Mark | Previous | Next | Full Screen | Tutorial | Lab Values | Notes | Calculator | Reverse Color | Text Zoom | Settings

- Myoclonus &/or seizures

Exhibit Display

Frontotemporal lobar degeneration Frontotemporal lobar degeneration

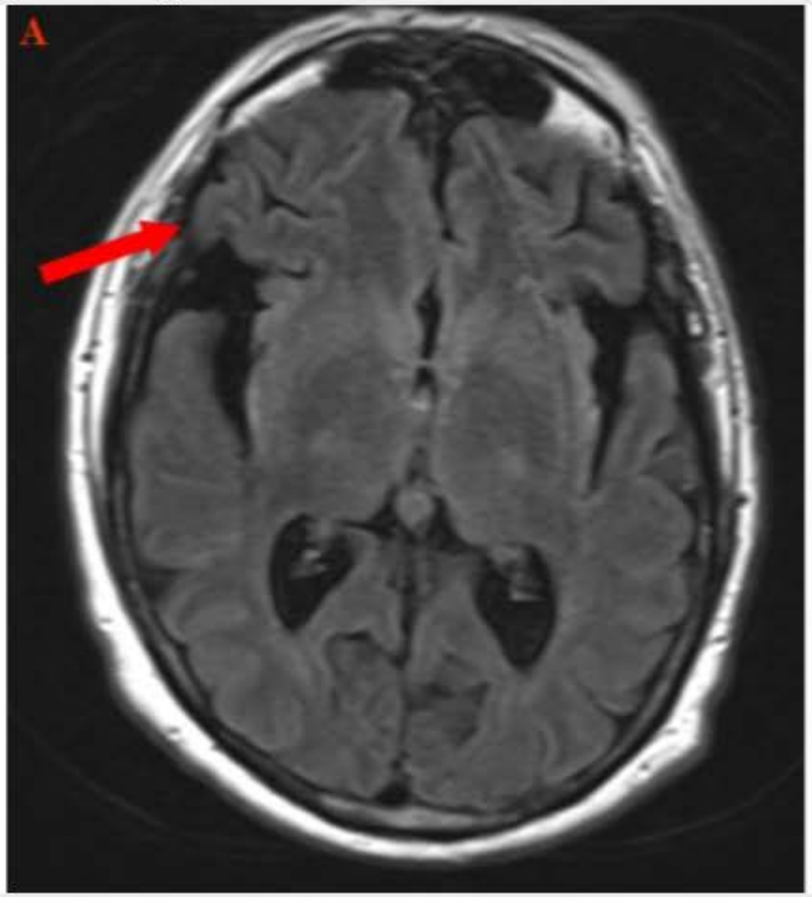

Zoom In | Zoom Out | Reset | Add To New Card | Existing Card

Frontotemporal dementia is associated with pronounced atrophy of the prefrontal cortex with later degeneration of the anterior temporal cortex. It

Block Time Remaining: 00:00:19
TUTOR

5 | Feedback | Suspend | End Block

Settings

1 2 3 4 5 6 7 8 9 10 11 12 13 14 15 16 17 18 19 20 21 22 23 24 25 26 27 28 29 30

Item 7 of 40
Question Id: 594

Mark | Previous | Next | Full Screen | Tutorial | Lab Values | Notes | Calculator | Reverse Color | Text Zoom | Settings

- Myoclonus &/or seizures

Exhibit Display

Frontotemporal lobar degeneration Frontotemporal lobar degeneration

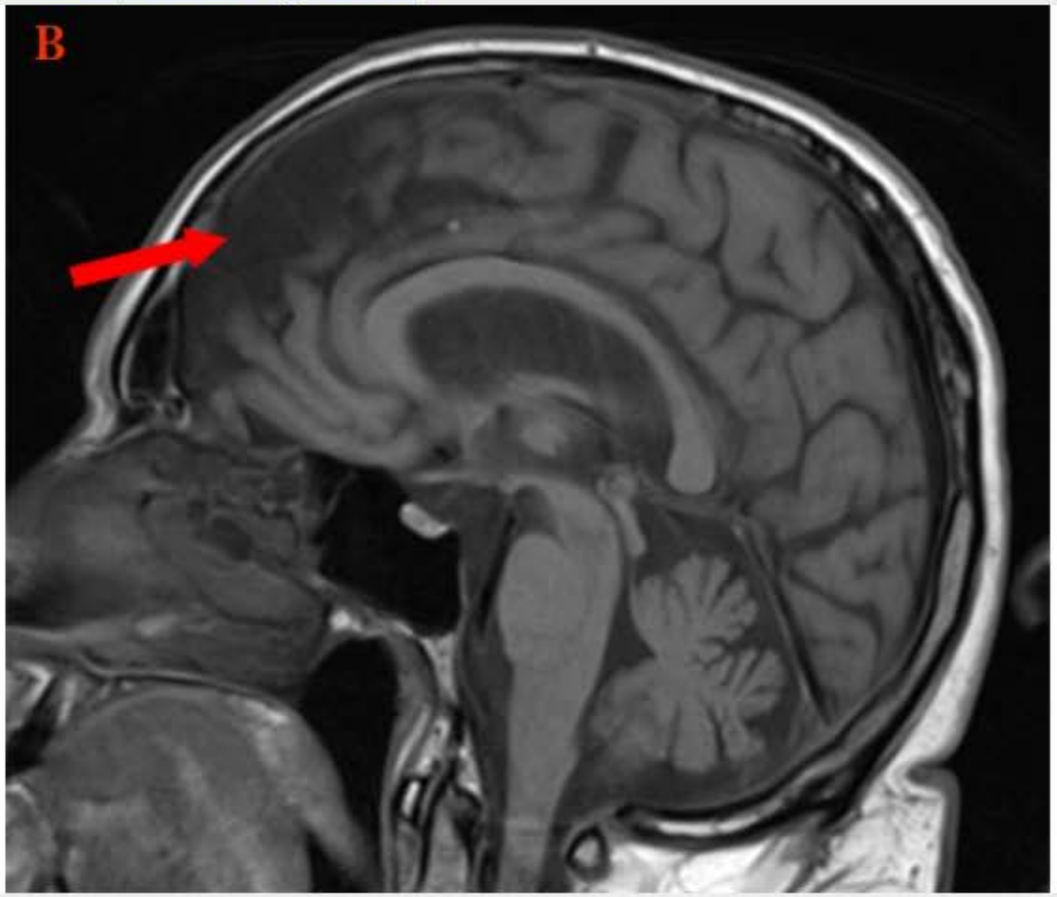

Zoom In | Zoom Out | Reset | Add To New Card | Existing Card

Frontotemporal dementia is associated with pronounced atrophy of the prefrontal cortex with later degeneration of the anterior temporal cortex. It

Block Time Remaining: 00:00:19
TUTOR

5 | Feedback | Suspend | End Block

a movement disorder are not characteristic of Huntington disease.

(Choice C) Neuronal loss in the locus ceruleus and substantia nigra is seen in Parkinson disease, which typically presents with tremor, bradykinesia, and rigidity. The locus ceruleus is a pontine structure that is one of the primary areas of norepinephrine synthesis in the brain. The substantia nigra, located in the midbrain, contains dopaminergic neurons whose axons project to the striatum (nigrostriatal pathway) and participate in regulation of voluntary movements.

(Choice D) Damage to the mammillary bodies and medial thalamus is characteristic of chronic Wernicke encephalopathy and Korsakoff syndrome. Both disorders result from chronic thiamine deficiency, most often in the context of heavy alcohol use.

(Choice E) Medial temporal and parietal cortical atrophy is characteristic of Alzheimer disease. The medial temporal lobe contains the hippocampus, a structure involved in the formation of new memories.

(Choice F) Disproportionate atrophy of the parietal and occipital cortices is seen in posterior cortical atrophy, an atypical variant of Alzheimer disease with prominent visual symptoms.

Educational objective:
Frontotemporal dementia is associated with pronounced atrophy of the prefrontal cortex with later degeneration of the anterior temporal cortex. It manifests initially with changes in personality, social behavior, and language that progress over time to a more global dementia with obvious neurocognitive deficits.

References

- Behavioural-variant frontotemporal dementia: diagnosis, clinical staging, and management.
- Sensitivity of revised diagnostic criteria for the behavioural variant of frontotemporal dementia.

Pathology	Nervous System	Frontotemporal dementia
Subject	System	Topic

Copyright © UWorld. All rights reserved.

Settings

1 2 3 4 5 6 7 8 9 10 11 12 13 14 15 16 17 18 19 20 21 22 23 24 25 26 27 28 29 30

Item 8 of 40
Question Id: 674

Mark | Previous | Next | Full Screen | Tutorial | Lab Values | Notes | Calculator | Reverse Color | Text Zoom | Settings

A 45-year-old man comes to the clinic due to a 2-month history of progressive left arm clumsiness and weakness. The patient initially attributed his symptoms to a left rotator cuff injury he sustained several years ago; however, he has recently developed problems with his gait. The patient's symptoms have interfered with daily activities such as bathing and dressing. He has had no recent injury, headaches, or bowel/bladder symptoms. On physical examination, there is reduced muscle strength in the left upper extremity. Further evaluation with brain MRI reveals a lesion involving the corticospinal tract. Which of the following additional signs is most likely to been seen in this patient?

- A. Hyperactive deep tendon reflexes
- B. Muscle atrophy
- C. Muscle fasciculation
- D. Muscle hypotonia
- E. Resting tremor
- F. Sensory loss in the affected area

Submit

Block Time Remaining: 00:00:19
TUTOR

4 | Feedback | Suspend | End Block

A 45-year-old man comes to the clinic due to a 2-month history of progressive left arm clumsiness and weakness. The patient initially attributed his symptoms to a left rotator cuff injury he sustained several years ago; however, he has recently developed problems with his gait. The patient's symptoms have interfered with daily activities such as bathing and dressing. He has had no recent injury, headaches, or bowel/bladder symptoms. On physical examination, there is reduced muscle strength in the left upper extremity. Further evaluation with brain MRI reveals a lesion involving the corticospinal tract. Which of the following additional signs is most likely to been seen in this patient?

- ✓ A. Hyperactive deep tendon reflexes (74%)
- B. Muscle atrophy (7%)
- C. Muscle fasciculation (7%)
- D. Muscle hypotonia (6%)
- E. Resting tremor (1%)
- F. Sensory loss in the affected area (3%)

Omitted
Correct answer
A

74%
Answered correctly

01 sec
Time Spent

05/24/2020
Last Updated

Explanation

	• Spastic paralysis

1 2 3 4 5 6 7 8 9 10 11 12 13 14 15 16 17 18 19 20 21 22 23 24 25 26 27 28 29 30

Upper motor neuron signs	• Spastic paralysis • Clasp-knife rigidity • Hyperreflexia • Babinski sign
Lower motor neuron signs	• Flaccid paralysis • Hypotonia • Hyporeflexia • Muscle atrophy & fasciculations

©UWorld

Voluntary muscle activity is mediated by the **corticospinal (pyramidal) tracts**. First-order neurons of these tracts are located in the premotor and motor cortex of the frontal lobe (Brodmann areas 6 and 4, respectively). Their efferent fibers descend through the internal capsule, midbrain, and pons, and continue to form the pyramids on the anterior aspect of the medulla. In the medulla, 90% of the fibers decussate (cross) to form the lateral corticospinal tract. Fibers that do not decussate descend as the anterior corticospinal tract. The axons of both tracts synapse on the motor neurons of the anterior horn (second-order neurons). Damage to the corticospinal tract is divided into upper and lower motor neuron lesions:

1. **Upper motor neuron** (UMN) refers to anything above the anterior horn. Lesions to UMNs (eg, due to stroke, brain tumor) cause a combination of **spastic paralysis**, clasp-knife **rigidity, hyperreflexia** (including clonus), and upgoing plantar reflexes (**Babinski sign**). This likely occurs due to loss of descending inhibition over second-order neurons in the anterior horn.
2. Damage to the motor neurons of the anterior horn is considered a lower motor neuron (LMN) lesion. This type of injury leads to flaccid paralysis, hypotonia, hyporeflexia, muscle atrophy, and fasciculations. Poliomyelitis and infantile spinal muscular atrophy are examples of LMN lesions **(Choices B, C, and D)**.

Combined UMN and LMN lesions are characteristic of amyotrophic lateral sclerosis (Lou Gehrig disease).

Voluntary muscle activity is mediated by the **corticospinal (pyramidal) tracts**. First-order neurons of these tracts are located in the premotor and motor cortex of the frontal lobe (Brodmann areas 6 and 4, respectively). Their efferent fibers descend through the internal capsule, midbrain, and pons, and continue to form the pyramids on the anterior aspect of the medulla. In the medulla, 90% of the fibers decussate (cross) to form the lateral corticospinal tract. Fibers that do not decussate descend as the anterior corticospinal tract. The axons of both tracts synapse on the motor neurons of the anterior horn (second-order neurons). Damage to the corticospinal tract is divided into upper and lower motor neuron lesions:

1. **Upper motor neuron** (UMN) refers to anything above the anterior horn. Lesions to UMNs (eg, due to stroke, brain tumor) cause a combination of **spastic paralysis**, clasp-knife **rigidity, hyperreflexia** (including clonus), and upgoing plantar reflexes (**Babinski sign**). This likely occurs due to loss of descending inhibition over second-order neurons in the anterior horn.
2. Damage to the motor neurons of the anterior horn is considered a lower motor neuron (LMN) lesion. This type of injury leads to flaccid paralysis, hypotonia, hyporeflexia, muscle atrophy, and fasciculations. Poliomyelitis and infantile spinal muscular atrophy are examples of LMN lesions **(Choices B, C, and D)**.

Combined UMN and LMN lesions are characteristic of amyotrophic lateral sclerosis (Lou Gehrig disease).

(Choice E) Resting tremor is characteristic of Parkinson disease, which occurs due to loss of dopaminergic neurons in the substantia nigra.

(Choice F) Sensory information is transmitted by the spinothalamic tract (pain and temperature) and dorsal column pathway (vibration and proprioception). Lesions to the corticospinal tract do not cause sensory deficits.

Educational objective:
Upper motor neuron damage leads to spastic paralysis, hyperreflexia, and an upgoing plantar reflex (Babinski sign) due to loss of descending inhibition over lower motor neurons in the anterior horn. Conversely, lower motor neuron lesions cause flaccid paralysis, hypotonia, hyporeflexia, muscle atrophy, and fasciculations.

References

- Spastic hypertonia and movement disorders: pathophysiology, clinical presentation, and quantification.
- The pathophysiology of spasticity.

Settings

1
2
3
4
5
6
7
8
9
10
11
12
13
14
15
16
17
18
19
20
21
22
23
24
25
26
27
28
29
30

Item 8 of 40
Question Id: 674

Mark | Previous | Next | Full Screen | Tutorial | Lab Values | Notes | Calculator | Reverse Color | Text Zoom | Settings

Exhibit Display

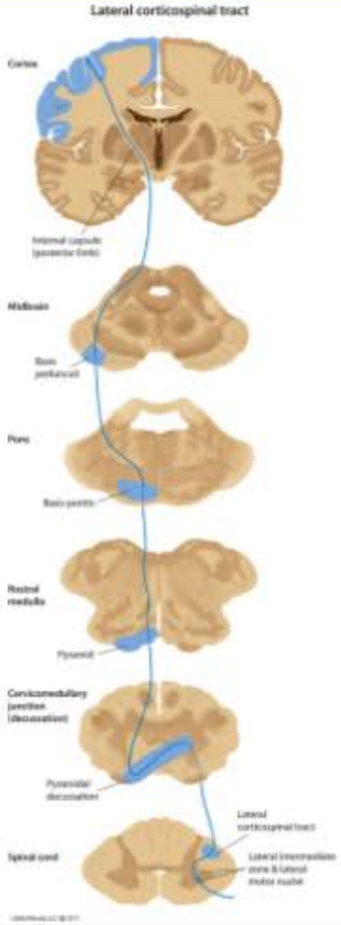

Zoom In | Zoom Out | Reset | Add To New Card | Existing Card

Block Time Remaining: 00:00:20
TUTOR

4 | Feedback | Suspend | End Block

Settings

1
2
3
4
5
6
7
8
9
10
11
12
13
14
15
16
17
18
19
20
21
22
23
24
25
26
27
28
29
30

Item 8 of 40
Question Id: 674

Mark | Previous | Next | Full Screen | Tutorial | Lab Values | Notes | Calculator | Reverse Color | Text Zoom | Settings

Exhibit Display

Anterior corticospinal tract

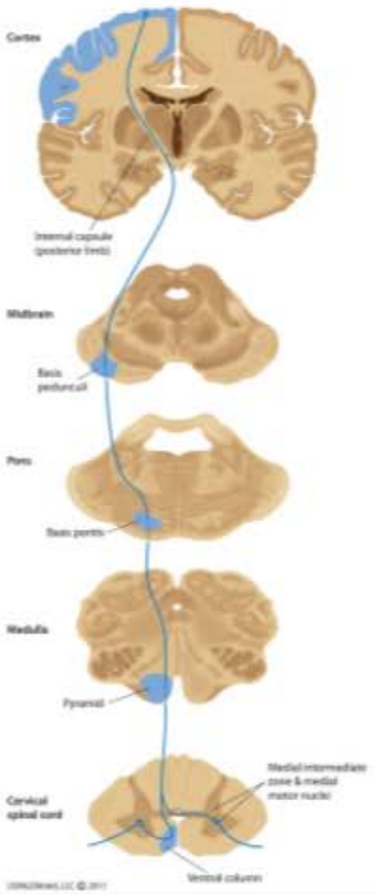

Zoom In | Zoom Out | Reset | Add To New Card | Existing Card

Block Time Remaining: 00:00:20
TUTOR

4 | Feedback | Suspend | End Block

neurons of the anterior horn (second-order neurons). Damage to the corticospinal tract is divided into upper and lower motor neuron lesions:

1. **Upper motor neuron** (UMN) refers to anything above the anterior horn. Lesions to UMNs (eg, due to stroke, brain tumor) cause a combination of **spastic paralysis**, clasp-knife **rigidity, hyperreflexia** (including clonus), and upgoing plantar reflexes (**Babinski sign**). This likely occurs due to loss of descending inhibition over second-order neurons in the anterior horn.
2. Damage to the motor neurons of the anterior horn is considered a lower motor neuron (LMN) lesion. This type of injury leads to flaccid paralysis, hypotonia, hyporeflexia, muscle atrophy, and fasciculations. Poliomyelitis and infantile spinal muscular atrophy are examples of LMN lesions **(Choices B, C, and D)**.

Combined UMN and LMN lesions are characteristic of amyotrophic lateral sclerosis (Lou Gehrig disease).

(Choice E) Resting tremor is characteristic of Parkinson disease, which occurs due to loss of dopaminergic neurons in the substantia nigra.

(Choice F) Sensory information is transmitted by the spinothalamic tract (pain and temperature) and dorsal column pathway (vibration and proprioception). Lesions to the corticospinal tract do not cause sensory deficits.

Educational objective:
Upper motor neuron damage leads to spastic paralysis, hyperreflexia, and an upgoing plantar reflex (Babinski sign) due to loss of descending inhibition over lower motor neurons in the anterior horn. Conversely, lower motor neuron lesions cause flaccid paralysis, hypotonia, hyporeflexia, muscle atrophy, and fasciculations.

References

- Spastic hypertonia and movement disorders: pathophysiology, clinical presentation, and quantification.
- The pathophysiology of spasticity.

Pathology	Nervous System	Amyotrophic lateral sclerosis
Subject	System	Topic

Copyright © UWorld. All rights reserved.

Settings

1
2
3
4
5
6
7
8
9
10
11
12
13
14
15
16
17
18
19
20
21
22
23
24
25
26
27
28
29
30

Item 9 of 40
Question Id: 614

Mark | Previous | Next | Full Screen | Tutorial | Lab Values | Notes | Calculator | Reverse Color | Text Zoom | Settings

A 64-year-old man is being evaluated for nausea and a new-onset headache that worsens when he bends over. Brain imaging shows a hemispheric cerebral mass that is subsequently biopsied. Light microscopy of the tissue specimen is shown in the image below.

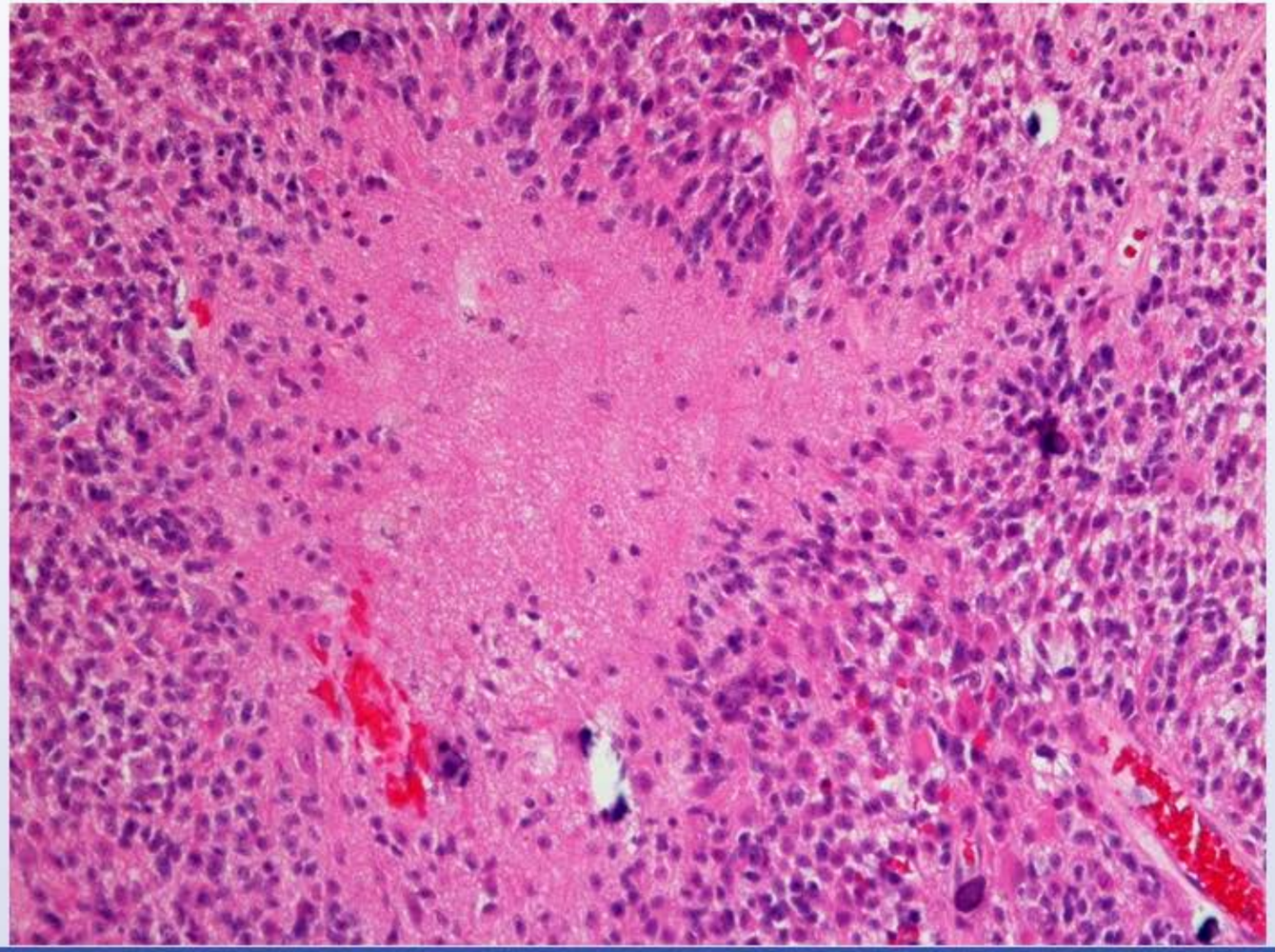

Block Time Remaining: 00:00:21
TUTOR

5 | Feedback | Suspend | End Block

Settings

1 2 3 4 5 6 7 8 9 10 11 12 13 14 15 16 17 18 19 20 21 22 23 24 25 26 27 28 29 30

Item 9 of 40
Question Id: 614

Mark | Previous | Next | Full Screen | Tutorial | Lab Values | Notes | Calculator | Reverse Color | Text Zoom | Settings

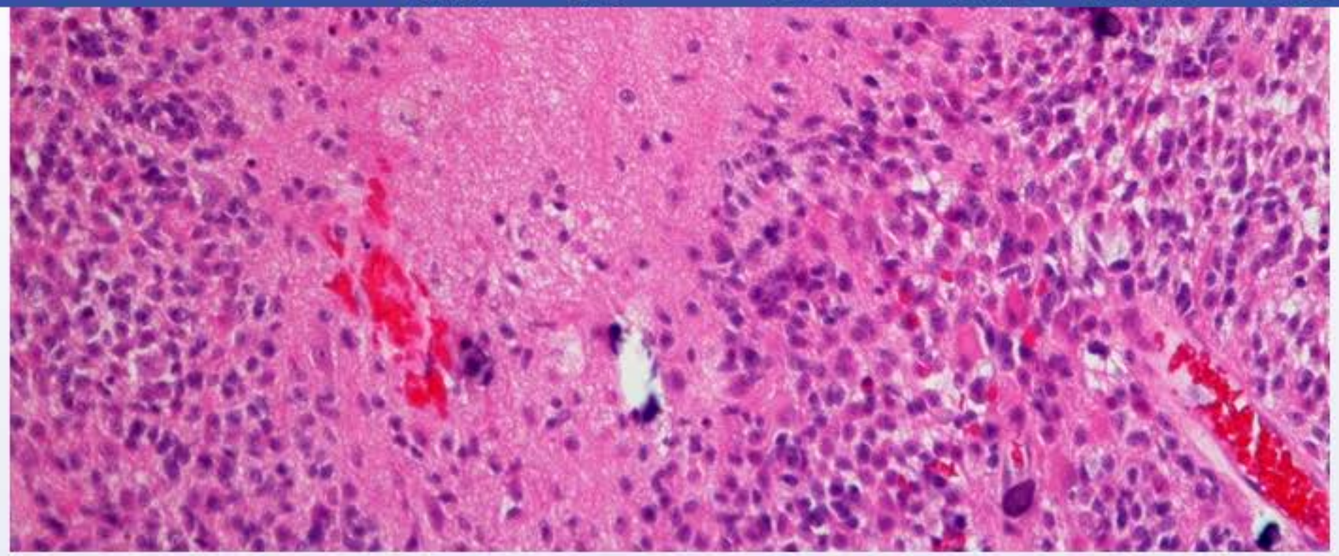

Which of the following histologic findings is most characteristic of this lesion?

- A. Cyst formation and rare mitoses
- B. Inflammatory cell infiltrate and reticulin deposits
- C. Microscopic laminar calcium deposition
- D. Necrosis and vascular proliferation
- E. Proliferating cells surrounding blood vessels

Submit

Block Time Remaining: 00:00:23
TUTOR

5 | Feedback | Suspend | End Block

Settings

Item 9 of 40
Question Id: 614

Mark | Previous | Next | Full Screen | Tutorial | Lab Values | Notes | Calculator | Reverse Color | Text Zoom | Settings

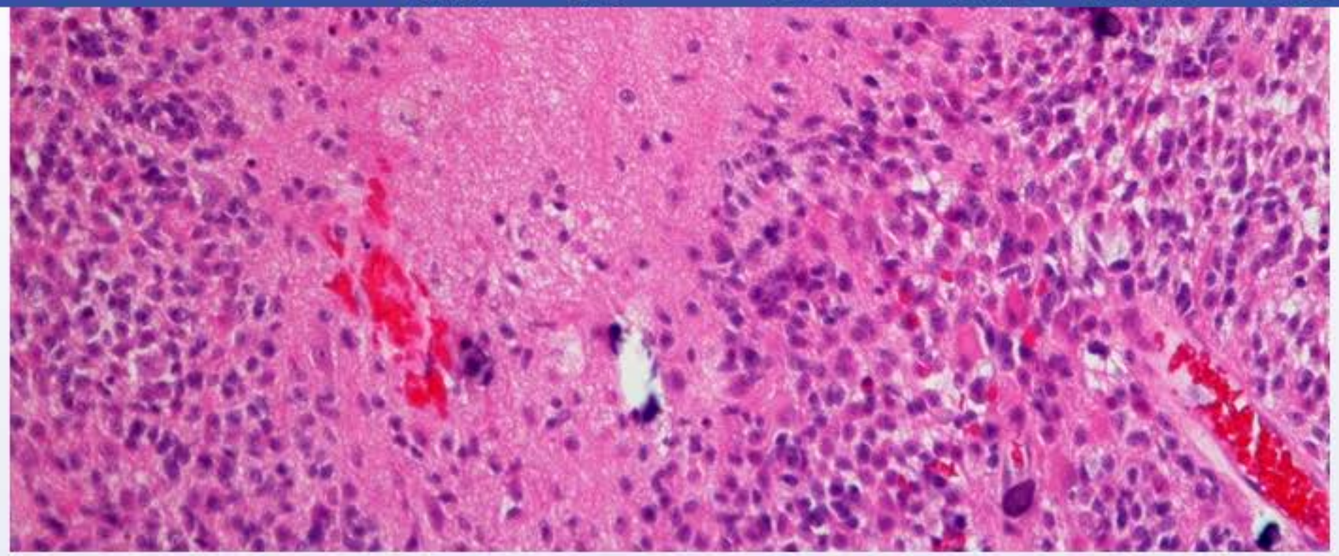

Which of the following histologic findings is most characteristic of this lesion?

A. Cyst formation and rare mitoses (3%)

B. Inflammatory cell infiltrate and reticulin deposits (13%)

C. Microscopic laminar calcium deposition (3%)

✓ D. Necrosis and vascular proliferation (62%)

E. Proliferating cells surrounding blood vessels (17%)

Omitted
Correct answer

62%
Answered correctly

04 secs
Time Spent

06/08/2020
Last Updated

Block Time Remaining: 00:00:24
TUTOR

5 | Feedback | Suspend | End Block

1 2 3 4 5 6 7 8 9 10 11 12 13 14 15 16 17 18 19 20 21 22 23 24 25 26 27 28 29 30

Glioblastoma multiforme

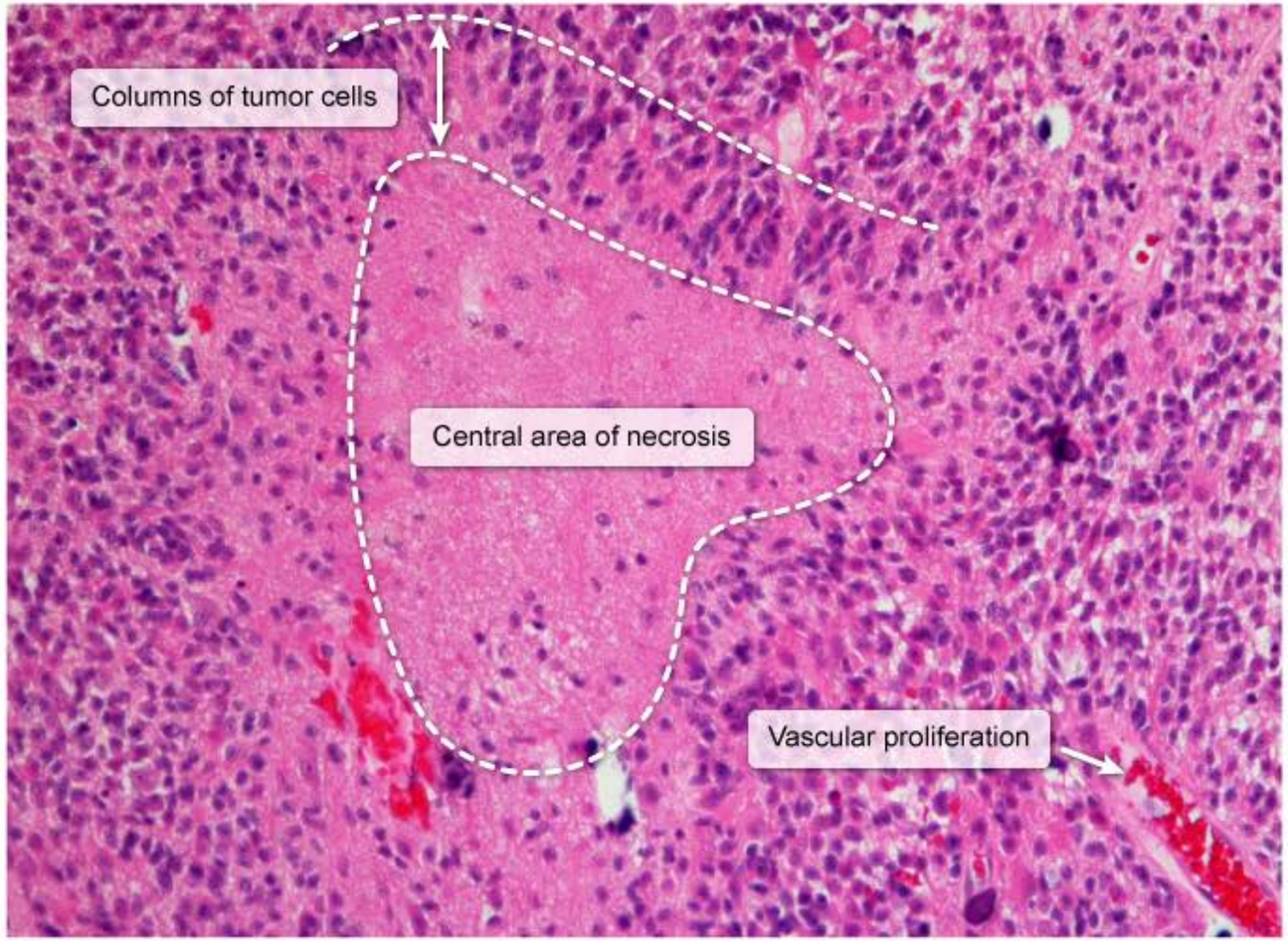

©UWorld

This image shows an area of necrosis surrounded by columns of tumor cells (ie, **pseudopalisading necrosis**) with capillaries at the periphery (**vascular proliferation**). These histologic features are characteristic of glioblastoma multiforme (GBM), a malignant glioma that is the most

This image shows an area of necrosis surrounded by columns of tumor cells (ie, **pseudopalisading necrosis**) with capillaries at the periphery (**vascular proliferation**). These histologic features are characteristic of glioblastoma multiforme (GBM), a malignant glioma that is the most common primary brain neoplasm in adults. GBM is usually located within the cerebral hemispheres (eg, frontal lobe, temporal lobe) and often presents with **new-onset headache** that worsens with bending over (increases intracranial pressure). Nausea/vomiting, focal neurological defects, and/or seizures are also frequently seen. The prognosis for patients with GBM is poor, with median survival at 10-12 months.

(Choice A) Cyst formation and rare mitoses indicate a colloid cyst, a pathologically benign tumor usually found in the third ventricle. Although colloid cysts are usually asymptomatic, they can cause lethal obstructive hydrocephalus.

(Choice B) Reticulin deposits and chronic inflammatory infiltrates are seen in pleomorphic xanthoastrocytomas. Although they can rarely progress to GBM, these tumors are usually found in children and young adults.

(Choice C) Meningiomas are tumors of the meninges that have a whorled pattern of growth. Although they are not always present, laminar calcifications called psammoma bodies are characteristic of benign meningiomas.

(Choice E) Ependymomas also display prominent vascular proliferation. However, these tumors are usually infratentorial (eg, fourth ventricle, spinal cord), rare in adults, and characterized histologically by proliferating ependymal cells surrounding blood vessels (perivascular pseudorosettes) rather than prominent areas of necrosis.

Educational objective:
Glioblastoma multiforme is the most common primary brain tumor in adults. Histopathology showing increased vascularity and pseudopalisading tumor cells around areas of necrosis is diagnostic.

References

- 'Pseudopalisading' necrosis in glioblastoma: a familiar morphologic feature that links vascular pathology, hypoxia, and angiogenesis.

Pathology	Nervous System	Brain tumors
Subject	System	Topic

Copyright © UWorld. All rights reserved.

This image shows an area of necrosis surrounded by columns of tumor cells (ie, **pseudopalisading necrosis**) with capillaries at the periphery (**vascular proliferation**)
common primary brain n
presents with **new-onset**
defects, and/or seizures

(Choice A) Cyst formati
colloid cysts are usually

(Choice B) Reticulin de
progress to GBM, these

(Choice C) Meningioma
calcifications called psan

(Choice E) Ependymom
spinal cord), rare in adult
pseudorosettes) rather th

Educational objective:
Glioblastoma multiforme
tumor cells around areas

References

- 'Pseudopalisading' n

Pathology
Subject

Nervou
System

Exhibit Display

Glioblastoma multiforme	
Onset	Age 40-70
Cell of origin	Astrocyte
Location	• Frontal & temporal lobes, basal ganglia • Commonly **crosses the midline** (butterfly distribution)
Macroscopic appearance	• Areas of necrosis & hemorrhage (variegated appearance, thus termed multiforme) • Poorly demarcated from surrounding tissue
Microscopic appearance	• **Pseudopalisading necrosis** (foci of necrosis surrounded by tumor cells) • New vessel formation • Small round cells, bizarre giant cells, large number of mitoses
Symptoms	• Headache • Seizure • Mental status change • Focal neurologic symptoms
Prognosis	• Highly malignant • Death within 1 year of diagnosis

Add To New Card | Existing Card

Copyright © UWorld. All rights reserved.

Settings

1
2
3
4
5
6
7
8
9
10
11
12
13
14
15
16
17
18
19
20
21
22
23
24
25
26
27
28
29
30

Item 9 of 40
Question Id: 614

Mark | Previous | Next | Full Screen | Tutorial | Lab Values | Notes | Calculator | Reverse Color | Text Zoom | Settings

Exhibit Display

Colloid cyst of the third ventricle

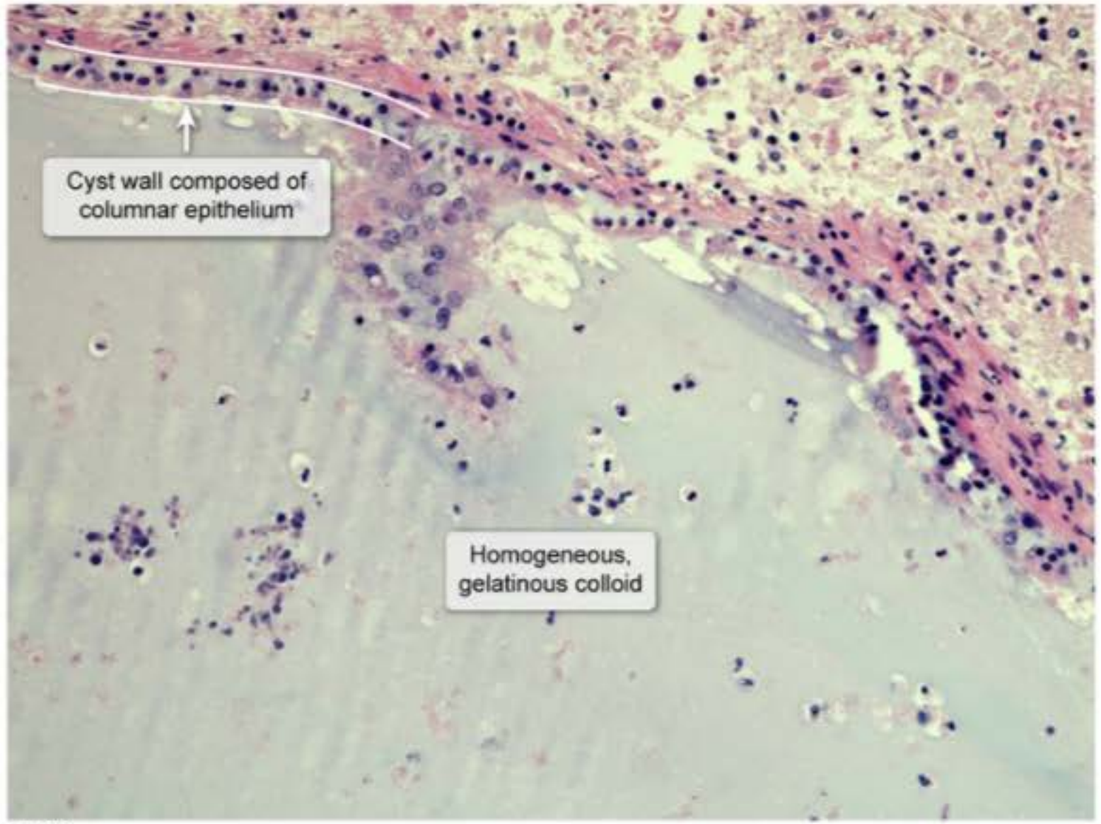

©UWorld

Zoom In | Zoom Out | Reset | Add To New Card | Existing Card

Copyright © UWorld. All rights reserved.

Block Time Remaining: 00:00:24
TUTOR

5 | Feedback | Suspend | End Block

Settings

1 2 3 4 5 6 7 8 9 10 11 12 13 14 15 16 17 18 19 20 21 22 23 24 25 26 27 28 29 30

Item 9 of 40
Question Id: 614

Mark | Previous | Next | Full Screen | Tutorial | Lab Values | Notes | Calculator | Reverse Color | Text Zoom | Settings

Exhibit Display

Meningioma

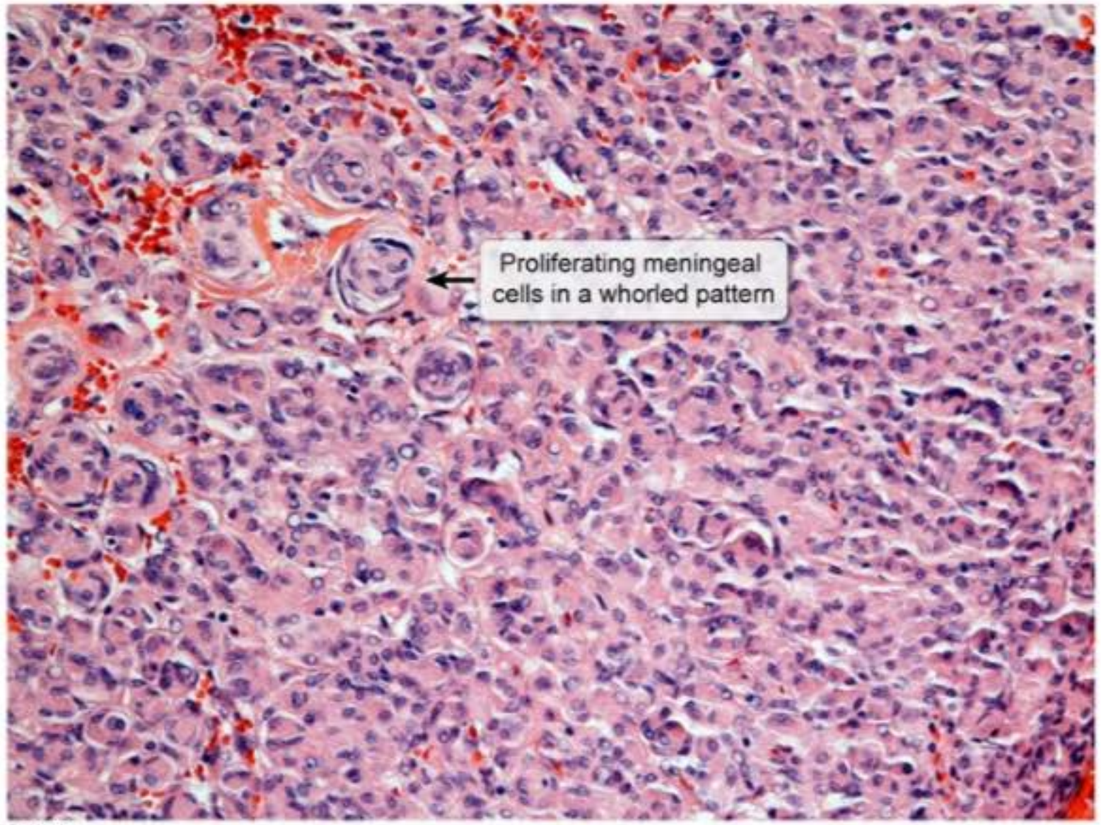

©UWorld

Zoom In | Zoom Out | Reset | Add To New Card | Existing Card

Copyright © UWorld. All rights reserved.

Block Time Remaining: 00:00:24
TUTOR

5 | Feedback | Suspend | End Block

Settings

1 2 3 4 5 6 7 8 9 10 11 12 13 14 15 16 17 18 19 20 21 22 23 24 25 26 27 28 29 30

Item 9 of 40
Question Id: 614

Mark | Previous | Next | Full Screen | Tutorial | Lab Values | Notes | Calculator | Reverse Color | Text Zoom | Settings

Exhibit Display

Ependymoma

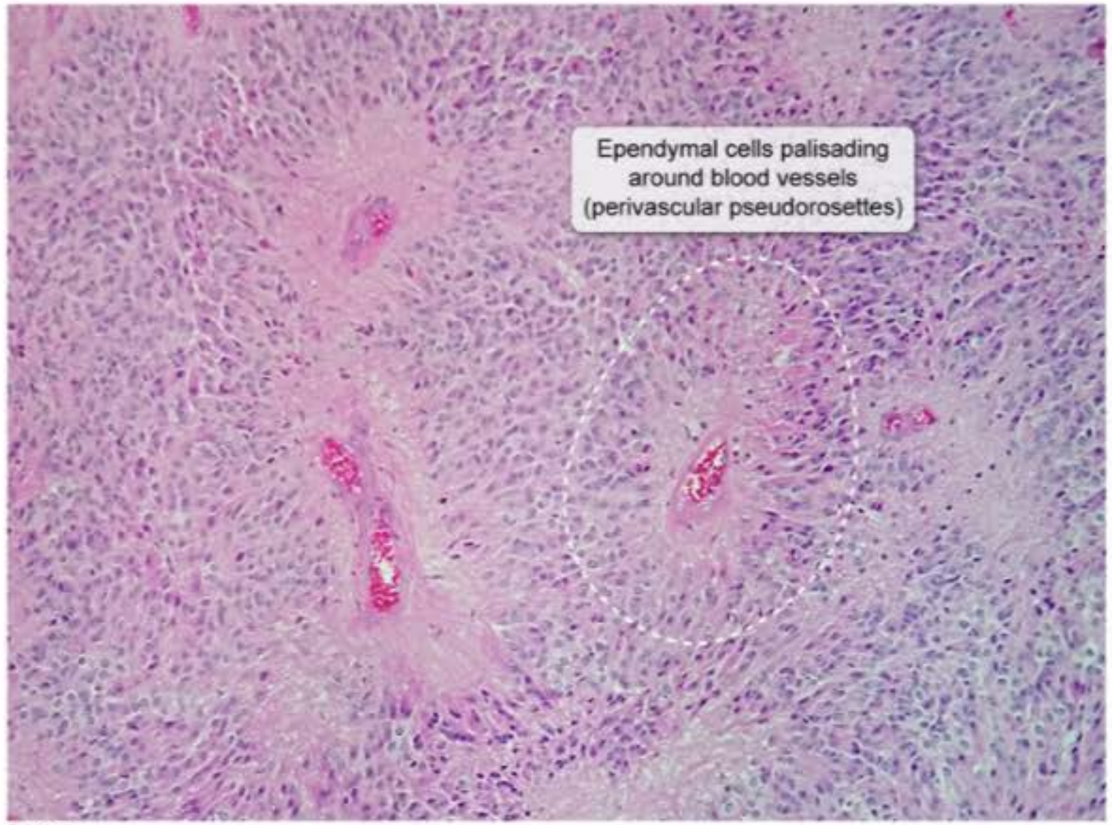

©UWorld

Zoom In | Zoom Out | Reset | Add To New Card | Existing Card

Copyright © UWorld. All rights reserved.

Block Time Remaining: 00:00:24
TUTOR

5 | Feedback | Suspend | End Block

Settings

1 2 3 4 5 6 7 8 9 10 11 12 13 14 15 16 17 18 19 20 21 22 23 24 25 26 27 28 29 30

Item 10 of 40
Question Id: 66

Mark | Previous | Next | Full Screen | Tutorial | Lab Values | Notes | Calculator | Reverse Color | Text Zoom | Settings

Experimental animals are immunized to protein fragments derived from peripheral nerve myelin. Subsequent analysis finds evidence of a T-cell response as well as production of autoantibodies against nonprotein antigens. This leads to segmental demyelination of peripheral nerves in the animals. The experimentally induced condition is most analogous to which of the following?

A. Duchenne muscular dystrophy

B. Guillain-Barré syndrome

C. Lambert-Eaton syndrome

D. Neuropathic beriberi

E. Subacute combined degeneration

F. Werdnig-Hoffman syndrome

Submit

Block Time Remaining: 00:00:24
TUTOR

2 | Feedback | Suspend | End Block

Settings

1 2 3 4 5 6 7 8 9 10 11 12 13 14 15 16 17 18 19 20 21 22 23 24 25 26 27 28 29 30

Item 10 of 40
Question Id: 66

Mark | Previous | Next | Full Screen | Tutorial | Lab Values | Notes | Calculator | Reverse Color | Text Zoom | Settings

Experimental animals are immunized to protein fragments derived from peripheral nerve myelin. Subsequent analysis finds evidence of a T-cell response as well as production of autoantibodies against nonprotein antigens. This leads to segmental demyelination of peripheral nerves in the animals. The experimentally induced condition is most analogous to which of the following?

- A. Duchenne muscular dystrophy (0%)
- ✓ B. Guillain-Barré syndrome (92%)
- C. Lambert-Eaton syndrome (2%)
- D. Neuropathic beriberi (0%)
- E. Subacute combined degeneration (2%)
- F. Werdnig-Hoffman syndrome (1%)

Omitted
Correct answer
B

92%
Answered correctly

01 sec
Time Spent

03/16/2020
Last Updated

Explanation

Pathogenesis of Guillain-Barré Syndrome

Infection → Immune activation

Block Time Remaining: 00:00:25
TUTOR

2 | Feedback | Suspend | End Block

Settings

Item 10 of 40
Question Id: 66

Mark | Previous | Next | Full Screen | Tutorial | Lab Values | Notes | Calculator | Reverse Color | Text Zoom | Settings

Pathogenesis of Guillain-Barré Syndrome

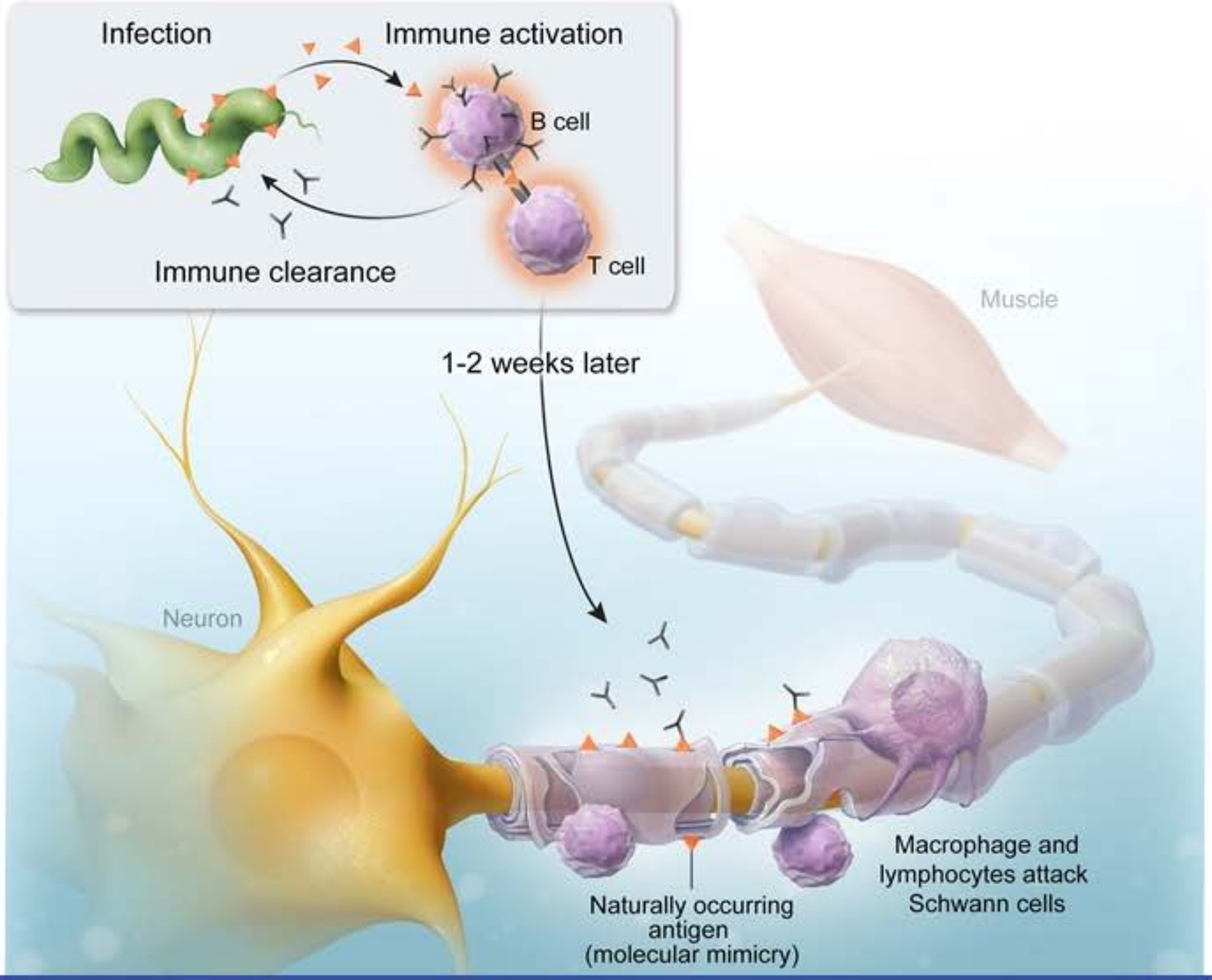

Block Time Remaining: 00:00:25
TUTOR

2 | Feedback | Suspend | End Block

1 2 3 4 5 6 7 8 9 10 11 12 13 14 15 16 17 18 19 20 21 22 23 24 25 26 27 28 29 30

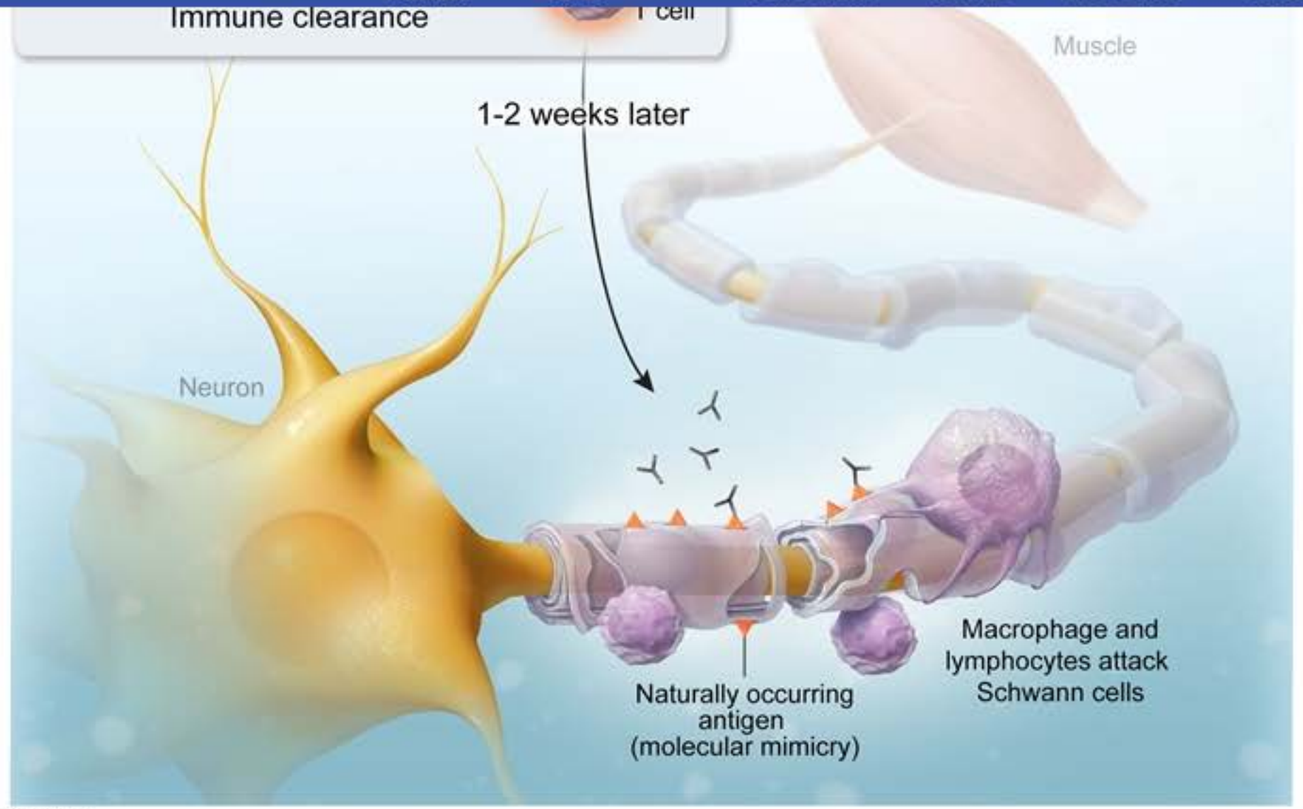

©UWorld

Demyelination of peripheral nerves in response to immune challenge with a myelin-like substance is a pathogenic mechanism similar to **Guillain-Barré syndrome** (GBS). GBS is thought to be due to **molecular mimicry**, in which an infectious agent contains a ganglioside-like substance in its lipopolysaccharide layer. Antibodies formed against this substance and activated T-cells cross-react with the ganglioside components of myelin and Schwann cells. **Segmental demyelination** and an **endoneurial inflammatory infiltrate** composed of lymphocytes and macrophages are seen on light microscopy.

GBS manifests as **ascending, symmetric muscle weakness** that often occurs after a gastrointestinal (eg, *Campylobacter jejuni*) or upper

Demyelination of peripheral nerves in response to immune challenge with a myelin-like substance is a pathogenic mechanism similar to **Guillain-Barré syndrome** (GBS). GBS is thought to be due to **molecular mimicry**, in which an infectious agent contains a ganglioside-like substance in its lipopolysaccharide layer. Antibodies formed against this substance and activated T-cells cross-react with the ganglioside components of myelin and Schwann cells. **Segmental demyelination** and an **endoneurial inflammatory infiltrate** composed of lymphocytes and macrophages are seen on light microscopy.

GBS manifests as **ascending, symmetric muscle weakness** that often occurs after a gastrointestinal (eg, *Campylobacter jejuni*) or upper respiratory infection. Deep tendon reflexes are decreased or absent (areflexia), and the paralysis may ascend to the cranial nerves (particularly cranial nerve VII). Paralysis of respiratory muscles is fatal without supportive care.

(Choice A) Duchenne muscular dystrophy is an X-linked muscular dystrophy that affects boys and is caused by a frameshift mutation of the dystrophin gene. Clinical features include progressive weakness and a waddling gait with onset in childhood. Muscle biopsy shows degeneration of muscle fibers and replacement with fat and connective tissue; peripheral nerves are not involved.

(Choice C) Lambert-Eaton syndrome, often seen as a paraneoplastic syndrome in patients with small cell carcinoma of the lung, presents with weakness that improves with muscular repetition. It is caused by autoantibodies that react with the voltage-gated calcium channels on the presynaptic membrane, hampering the release of acetylcholine. The axons are not affected.

(Choice D) Beriberi (thiamine deficiency) is characterized by weakness, areflexia, pain, and paresthesias that are worse in the distal lower limbs. Beriberi can cause demyelination of peripheral nerves; however, unlike Guillain-Barré syndrome, no endoneurial inflammation is present.

(Choice E) Subacute combined degeneration occurs due to vitamin B_{12} deficiency and leads to degeneration of dorsal columns and lateral cerebrospinal tracts. Patients develop distal, progressive weakness and ataxia but the symptoms are slowly progressive (unlike GBS, which progresses rapidly). In addition, subacute combined degeneration is associated with spasticity, paresthesia, and a macrocytic anemia.

(Choice F) Werdnig-Hoffman syndrome (spinal muscle atrophy type 1) is due to degeneration of the anterior horn cells that is caused by a mutation in the *SMN1* gene. Werdnig-Hoffman syndrome causes symmetric progressive weakness, but the weakness is more prominent proximal>distal and typically occurs in childhood.

Educational objective:

GBS manifests as **ascending, symmetric muscle weakness** that often occurs after a gastrointestinal (eg, *Campylobacter jejuni*) or upper respiratory infection. Deep tendon reflexes are decreased or absent (areflexia), and the paralysis may ascend to the cranial nerves (particularly cranial nerve VII). Paralysis of respiratory muscles is fatal without supportive care.

(Choice A) Duchenne muscular dystrophy is an X-linked muscular dystrophy that affects boys and is caused by a frameshift mutation of the dystrophin gene. Clinical features include progressive weakness and a waddling gait with onset in childhood. Muscle biopsy shows degeneration of muscle fibers and replacement with fat and connective tissue; peripheral nerves are not involved.

(Choice C) Lambert-Eaton syndrome, often seen as a paraneoplastic syndrome in patients with small cell carcinoma of the lung, presents with weakness that improves with muscular repetition. It is caused by autoantibodies that react with the voltage-gated calcium channels on the presynaptic membrane, hampering the release of acetylcholine. The axons are not affected.

(Choice D) Beriberi (thiamine deficiency) is characterized by weakness, areflexia, pain, and paresthesias that are worse in the distal lower limbs. Beriberi can cause demyelination of peripheral nerves; however, unlike Guillain-Barré syndrome, no endoneurial inflammation is present.

(Choice E) Subacute combined degeneration occurs due to vitamin B_{12} deficiency and leads to degeneration of dorsal columns and lateral cerebrospinal tracts. Patients develop distal, progressive weakness and ataxia but the symptoms are slowly progressive (unlike GBS, which progresses rapidly). In addition, subacute combined degeneration is associated with spasticity, paresthesia, and a macrocytic anemia.

(Choice F) Werdnig-Hoffman syndrome (spinal muscle atrophy type 1) is due to degeneration of the anterior horn cells that is caused by a mutation in the *SMN1* gene. Werdnig-Hoffman syndrome causes symmetric progressive weakness, but the weakness is more prominent proximal>distal and typically occurs in childhood.

Educational objective:
Guillain-Barré syndrome is an acute, demyelinating polyneuropathy thought to be caused by molecular mimicry. Antibodies formed against infectious agents cross-react with myelin and Schwann cells, leading to immune-mediated demyelination. Light microscopy shows segmental demyelination and an endoneurial inflammatory infiltrate composed of lymphocytes and macrophages.

Pathology Nervous System Guillain Barre syndrome

1 2 3 4 5 6 7 8 9 10 11 12 13 14 15 16 17 18 19 20 21 22 23 24 25 26 27 28 29 30

(Choice A) Duchenne muscular dystrophy is an X-linked muscular dystrophy that affects boys and is caused by a frameshift mutation of the dystrophin gene. Clinical features include progressive weakness and a waddling gait with onset in childhood. Muscle biopsy shows degeneration of muscle fibers and replacement with fat and connective tissue; peripheral nerves are not involved.

(Choice C) Lambert-Eaton syndrome, often seen as a paraneoplastic syndrome in patients with small cell carcinoma of the lung, presents with weakness that improves with muscular repetition. It is caused by autoantibodies that react with the voltage-gated calcium channels on the presynaptic membrane, hampering the release of acetylcholine. The axons are not affected.

(Choice D) Beriberi (thiamine deficiency) is characterized by weakness, areflexia, pain, and paresthesias that are worse in the distal lower limbs. Beriberi can cause demyelination of peripheral nerves; however, unlike Guillain-Barré syndrome, no endoneurial inflammation is present.

(Choice E) Subacute combined degeneration occurs due to vitamin B_{12} deficiency and leads to degeneration of dorsal columns and lateral cerebrospinal tracts. Patients develop distal, progressive weakness and ataxia but the symptoms are slowly progressive (unlike GBS, which progresses rapidly). In addition, subacute combined degeneration is associated with spasticity, paresthesia, and a macrocytic anemia.

(Choice F) Werdnig-Hoffman syndrome (spinal muscle atrophy type 1) is due to degeneration of the anterior horn cells that is caused by a mutation in the *SMN1* gene. Werdnig-Hoffman syndrome causes symmetric progressive weakness, but the weakness is more prominent proximal>distal and typically occurs in childhood.

Educational objective:
Guillain-Barré syndrome is an acute, demyelinating polyneuropathy thought to be caused by molecular mimicry. Antibodies formed against infectious agents cross-react with myelin and Schwann cells, leading to immune-mediated demyelination. Light microscopy shows segmental demyelination and an endoneurial inflammatory infiltrate composed of lymphocytes and macrophages.

Pathology	Nervous System	Guillain Barre syndrome
Subject	System	Topic

Copyright © UWorld. All rights reserved.

Settings

1 2 3 4 5 6 7 8 9 10 11 12 13 14 15 16 17 18 19 20 21 22 23 24 25 26 27 28 29 30

Item 11 of 40
Question Id: 871

Mark | Previous | Next | Full Screen | Tutorial | Lab Values | Notes | Calculator | Reverse Color | Text Zoom | Settings

A 70-year-old woman with a history of unilateral extremity weakness and seizures is found unresponsive at home by her home health care nurse. On arrival of emergency medical services, she is found to have no pulse or spontaneous respirations and is declared dead. Autopsy shows a large thrombus occluding the left anterior descending coronary artery. Additional cerebral findings are shown in the exhibit. Which of the following most accurately describes the pathogenesis of this patient's brain lesion?

A. Fibroblast proliferation in the affected area

B. Granulomatous reaction against parasites

C. Immune-mediated focal demyelination

D. Necrosis of rapidly dividing, anaplastic astrocytes

E. Tissue destruction by lysosomal enzymes

Submit

Block Time Remaining: 00:00:25
TUTOR

5 | Feedback | Suspend | End Block

1 2 3 4 5 6 7 8 9 10 11 12 13 14 15 16 17 18 19 20 21 22 23 24 25 26 27 28 29 30

A 70-year-old woman with a history of unilateral extremity weakness and seizures is found unresponsive at home by her home health care nurse. On arrival of emergency medical services, she is found to have no pulse or spontaneous respirations and is declared dead. Autopsy shows a large thrombus occluding the left anterior descending coronary artery. Additional cerebral findings are shown in the exhibit. Which of the following most accurately describes the pathogenesis of this patient's brain lesion?

A. Fibroblast proliferation in the affected area (7%)

B. Granulomatous reaction against parasites (0%)

C. Immune-mediated focal demyelination (1%)

D. Necrosis of rapidly dividing, anaplastic astrocytes (16%)

✓ E. Tissue destruction by lysosomal enzymes (73%)

Omitted
Correct answer
E

73%
Answered correctly

02 secs
Time Spent

01/25/2020
Last Updated

Explanation

Settings

1
2
3
4
5
6
7
8
9
10
11
12
13
14
15
16
17
18
19
20
21
22
23
24
25
26
27
28
29
30

Item 11 of 40
Question Id: 871

Mark | Previous | Next | Full Screen | Tutorial | Lab Values | Notes | Calculator | Reverse Color | Text Zoom | Settings

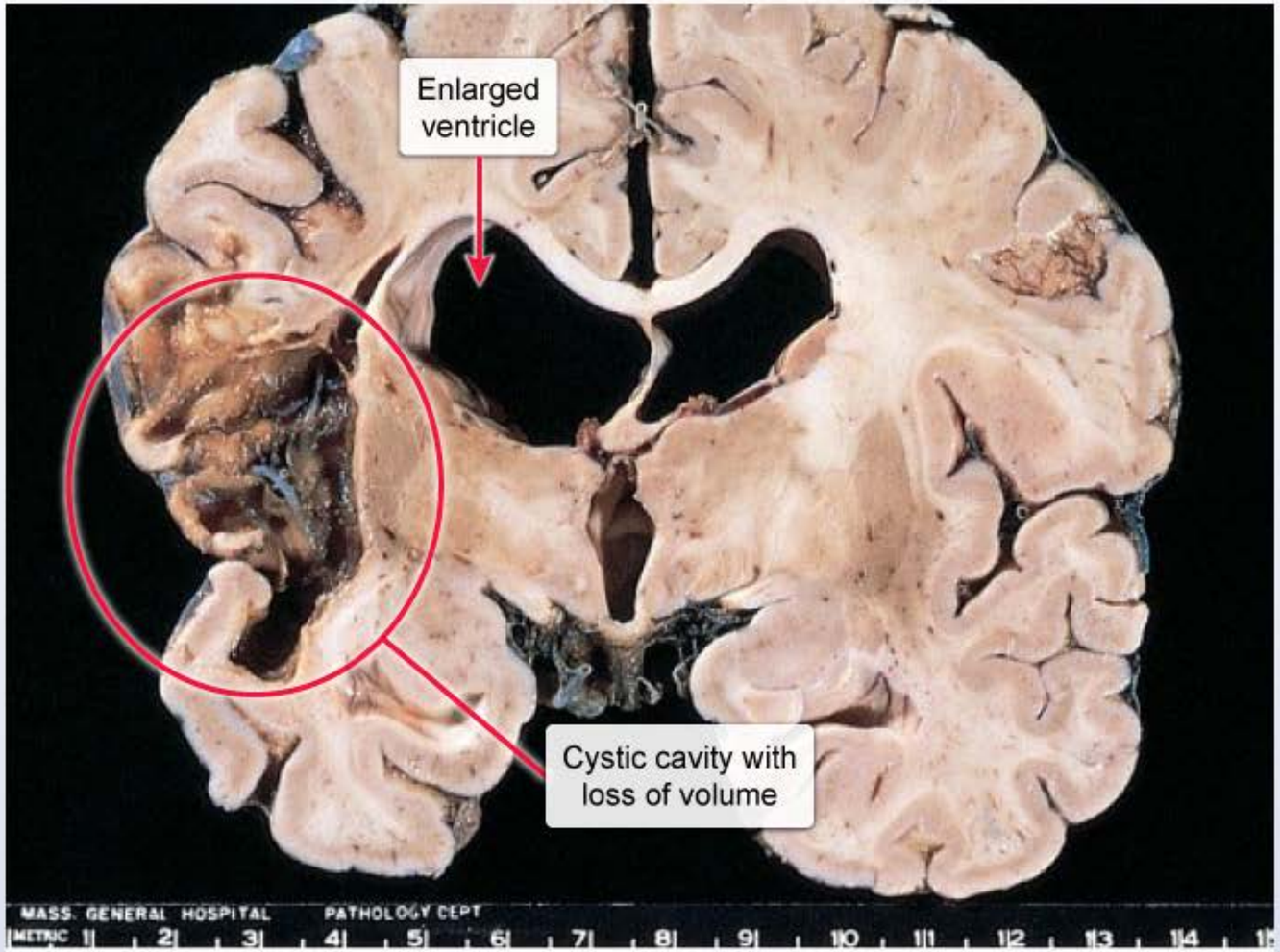

Displayed with permission from Springer Healthcare Ltd. © Copyright 2002 by Current Medicine

The autopsy image shows a coronal section of the brain with evidence of past necrosis (eg, cystic cavity, volume loss, and enlarged ventricle).

Block Time Remaining: 00:00:27
TUTOR

5 | Feedback | Suspend | End Block

Displayed with permission from Springer Healthcare Ltd. © Copyright 2002 by Current Medicine

The autopsy image shows a coronal section of the brain with evidence of past necrosis (eg, cystic cavity, volume loss, and enlarged ventricle). These findings are consistent with an **old cerebral infarct**, which was likely responsible for this patient's chronic neurologic symptoms (eg, extremity weakness and seizures).

Interruption in blood supply to an area of the brain, such as by thrombosis or embolism, induces irreversible ischemic changes in neurons. Release of **lysosomal enzymes** from ischemic neurons and responding inflammatory cells (eg, neutrophils, macrophages) results in tissue degradation in the affected region **(liquefactive necrosis)**. Over time, phagocytic cells remove the necrotic tissue, leaving a cavity, while astrocytes proliferate around the periphery to form a scar (gliosis).

Liquefactive necrosis is characteristic of irreversible CNS injury because of the brain's high cholesterol content and lack of supporting architecture. It also occurs in other body tissues in the setting of severe infection/inflammation (eg, bacterial abscess, fungal infection) because of the release of hydrolytic enzymes from reacting inflammatory cells.

(Choice A) Early fibroblast migration to an area of injury occurs outside of the CNS and results in the formation of granulation tissue and fibrous scarring. In the CNS, tissue repair and scar formation are performed by astrocytes.

(Choice B) A granulomatous reaction against parasites within the CNS occurs in neurocysticercosis. However, multiple cystic lesions or residual calcified granulomas would be expected.

(Choice C) Multiple sclerosis is a chronic inflammatory demyelinating disease characterized grossly by multiple periventricular lesions (ie, demyelinating plaques). Cystic cavity formation does not occur.

(Choice D) Although glioblastoma multiforme can present with areas of cystic necrosis on gross examination, these areas classically are part of a diffuse, poorly delineated, heterogenous mass with midline shift away from the affected tissue.

Educational objective:
Liquefactive necrosis is characterized by complete digestion and removal of necrotic tissue with formation of a cystic cavity. Irreversible ischemic CNS injury is typically followed by liquefactive necrosis due to the release of lysosomal enzymes from inflammatory cells and damaged neurons.

Interruption in blood supply to an area of the brain, such as by thrombosis or embolism, induces irreversible ischemic changes in neurons. Release of **lysosomal enzymes** from ischemic neurons and responding inflammatory cells (eg, neutrophils, macrophages) results in tissue degradation in the affected region **(liquefactive necrosis)**. Over time, phagocytic cells remove the necrotic tissue, leaving a cavity, while astrocytes proliferate around the periphery to form a scar (gliosis).

Liquefactive necrosis is characteristic of irreversible CNS injury because of the brain's high cholesterol content and lack of supporting architecture. It also occurs in other body tissues in the setting of severe infection/inflammation (eg, bacterial abscess, fungal infection) because of the release of hydrolytic enzymes from reacting inflammatory cells.

(Choice A) Early fibroblast migration to an area of injury occurs outside of the CNS and results in the formation of granulation tissue and fibrous scarring. In the CNS, tissue repair and scar formation are performed by astrocytes.

(Choice B) A granulomatous reaction against parasites within the CNS occurs in neurocysticercosis. However, multiple cystic lesions or residual calcified granulomas would be expected.

(Choice C) Multiple sclerosis is a chronic inflammatory demyelinating disease characterized grossly by multiple periventricular lesions (ie, demyelinating plaques). Cystic cavity formation does not occur.

(Choice D) Although glioblastoma multiforme can present with areas of cystic necrosis on gross examination, these areas classically are part of a diffuse, poorly delineated, heterogenous mass with midline shift away from the affected tissue.

Educational objective:
Liquefactive necrosis is characterized by complete digestion and removal of necrotic tissue with formation of a cystic cavity. Irreversible ischemic CNS injury is typically followed by liquefactive necrosis due to the release of lysosomal enzymes from inflammatory cells and damaged neurons.

Pathology	Nervous System	Necrosis
Subject	System	Topic

Copyright © UWorld. All rights reserved.

Settings

1 2 3 4 5 6 7 8 9 10 11 12 13 14 15 16 17 18 19 20 21 22 23 24 25 26 27 28 29 30

Item 11 of 40
Question Id: 871

Mark | Previous | Next | Full Screen | Tutorial | Lab Values | Notes | Calculator | Reverse Color | Text Zoom | Settings

Interruption in blood supply to an area of the brain, such as by thrombosis or embolism, induces irreversible ischemic changes in neurons.

Exhibit Display

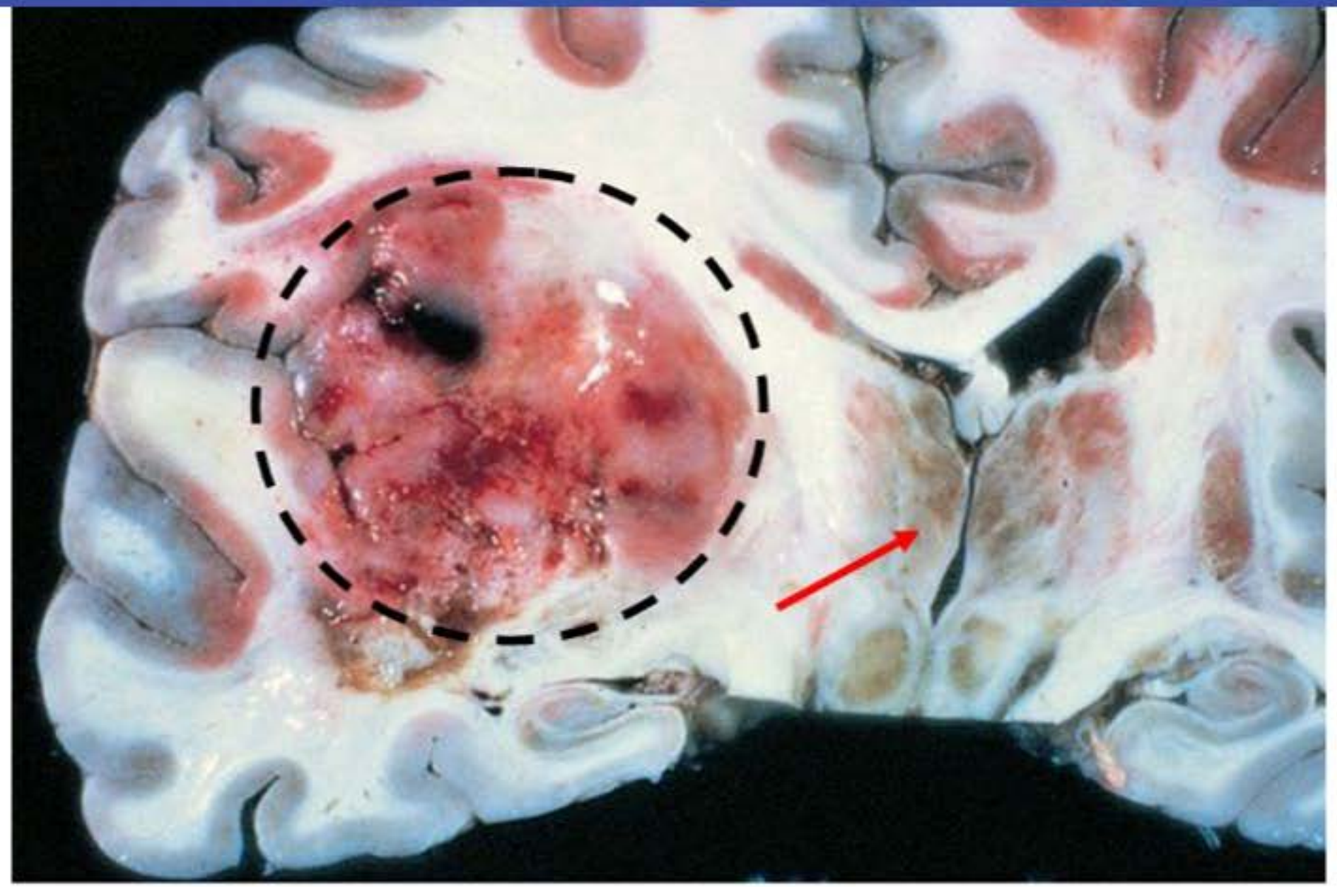

Displayed with permission from Springer Healthcare Ltd. © Copyright 2002 by Current Medicine

Zoom In | Zoom Out | Reset | Add To New Card | Existing Card

Block Time Remaining: 00:00:27
TUTOR

5 | Feedback | Suspend | End Block

Settings

1 2 3 4 5 6 7 8 9 10 11 12 13 14 15 16 17 18 19 20 21 22 23 24 25 26 27 28 29 30

Item 12 of 40
Question Id: 492

Mark | Previous | Next | Full Screen | Tutorial | Lab Values | Notes | Calculator | Reverse Color | Text Zoom | Settings

A researcher is studying neuronal changes in various physiologic and pathologic states. Microscopic examination of neural tissue obtained from experimental animals reveals neurons with shrunken nuclei and eosinophilic cytoplasm lacking Nissl bodies. Which of the following is the most likely cause of these findings?

A. Accumulation of abnormal proteins
B. Age-related physiologic changes
C. Defective lysosomal autophagy
D. Irreversible ischemic injury
E. Transection injury of the nerve fiber
F. Transient neural compression

Submit

Block Time Remaining: 00:00:27
TUTOR

5 | Feedback | Suspend | End Block

1 2 3 4 5 6 7 8 9 10 11 12 13 14 15 16 17 18 19 20 21 22 23 24 25 26 27 28 29 30

A researcher is studying neuronal changes in various physiologic and pathologic states. Microscopic examination of neural tissue obtained from experimental animals reveals neurons with shrunken nuclei and eosinophilic cytoplasm lacking Nissl bodies. Which of the following is the most likely cause of these findings?

- A. Accumulation of abnormal proteins (4%)
- B. Age-related physiologic changes (5%)
- C. Defective lysosomal autophagy (2%)
- ✓ D. Irreversible ischemic injury (66%)
- E. Transection injury of the nerve fiber (19%)
- F. Transient neural compression (1%)

Omitted
Correct answer
D

66%
Answered correctly

02 secs
Time Spent

04/05/2020
Last Updated

Explanation

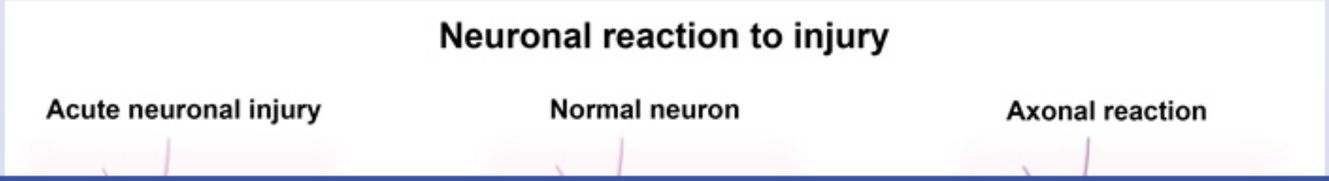

1 2 3 4 5 6 7 8 9 10 11 12 13 14 15 16 17 18 19 20 21 22 23 24 25 26 27 28 29 30

Neuronal reaction to injury

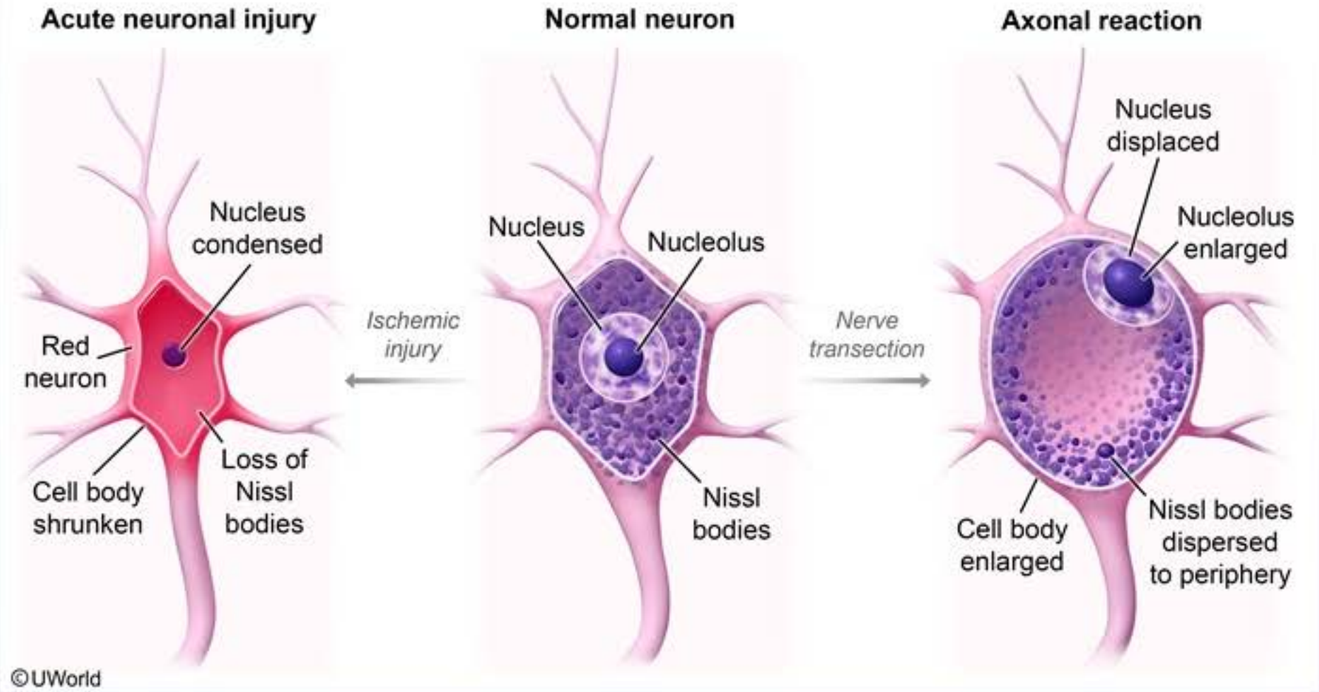

Neurons are the major functional unit of the nervous system and are characterized histologically by large, round, centrally located nuclei and basophilic cytoplasmic granules composed of rough endoplasmic reticulum (Nissl bodies). When neurons are injured, they undergo distinct histopathologic changes depending on the type of underlying injury.

In response to an **acute irreversible injury** (eg, severe hypoglycemia, **ischemia**), neurons begin to display characteristic morphologic changes 12-24 hours after the inciting event, appearing as shrunken cells separated from the surrounding tissue. The **nucleus** becomes **pyknotic** (shrunken and basophilic with loss of the nucleolus), and the basophilic **Nissl bodies disappear**, resulting in cytoplasm that stains deeply eosinophilic **(red neurons)**.

Neurons are the major functional unit of the nervous system and are characterized histologically by large, round, centrally located nuclei and basophilic cytoplasmic granules composed of rough endoplasmic reticulum (Nissl bodies). When neurons are injured, they undergo distinct histopathologic changes depending on the type of underlying injury.

In response to an **acute irreversible injury** (eg, severe hypoglycemia, **ischemia**), neurons begin to display characteristic morphologic changes 12-24 hours after the inciting event, appearing as shrunken cells separated from the surrounding tissue. The **nucleus** becomes **pyknotic** (shrunken and basophilic with loss of the nucleolus), and the basophilic **Nissl bodies disappear**, resulting in cytoplasm that stains deeply eosinophilic **(red neurons)**.

In the brain, in contrast to most other tissues, ischemia ultimately results in liquefactive necrosis due to the breakdown of neural architecture by hydrolytic enzymes released from reacting inflammatory cells and damaged neurons. The necrotic neuronal remnants are then phagocytized by microglia, and astrocytes proliferate at the site of the injury to form a glial scar.

(Choice A) Several neurodegenerative diseases (eg, Alzheimer disease, frontotemporal lobar degeneration) are characterized by intracellular and/or extracellular accumulation of abnormal proteins in neural tissue. Histologic examination of affected areas demonstrates proteinaceous plaques, tangles, and/or inclusions with reactive gliosis and loss of neurons.

(Choice B) Normal aging is associated with progressive atrophy and neuronal loss. However, red neuron changes are not characteristic of age-related physiologic changes.

(Choice C) Lysosomal storage diseases (eg, Tay-Sachs, Niemann-Pick) cause the accumulation of improperly digested substances in lysosomes, leading to neural degeneration through free radical damage and apoptosis. Expected histopathologic changes include enlarged neuronal cells with a foamy appearance due to accumulated undigested macromolecules.

(Choice E) Extensive axon damage or transection results in an axonal reaction characterized by cell body swelling, movement of the nucleus to the periphery, and dispersion of Nissl bodies. This response occurs due to increased protein and lipid synthesis during axon regeneration.

(Choice F) Transient neural compression can lead to a temporary loss of function due to ischemia but would not lead to significant histopathologic changes unless the compression was sustained. Neural compression may occur in the CNS due to increased intracranial pressure or a mass lesion.

Neurons are the major fu
basophilic cytoplasmic g
histopathologic changes

In response to an **acute**
12-24 hours after the inc
(shrunken and basophilic
eosinophilic **(red neuron**

In the brain, in contrast t
hydrolytic enzymes relea
microglia, and astrocytes

(Choice A) Several neu
and/or extracellular accu
plaques, tangles, and/or

(Choice B) Normal agin
related physiologic chang

(Choice C) Lysosomal s
leading to neural degene
with a foamy appearance

(Choice E) Extensive ax
the periphery, and disper

(Choice F) Transient ne
changes unless the comp

Exhibit Display

Type of response	Type of injury	Histopathologic changes
Acute neuronal injury	• Severe insult (eg, ischemia) leading to cell death	• Shrinkage of the cell body • Pyknosis of the nucleus • Loss of Nissl bodies • Eosinophilic cytoplasm (red neuron)
Axonal reaction (regeneration)	• Axon transection	• Enlargement of the cell body • Eccentrically placed nucleus • Enlargement of the nucleolus • Dispersion of Nissl bodies
Chronic neuronal injury	• Progressive degenerative disease (eg, ALS, Parkinson disease)	• Loss of functionally related neurons • Reactive gliosis

ALS = amyotrophic lateral sclerosis.

Add To New Card | Existing Card

Settings

1 2 3 4 5 6 7 8 9 10 11 12 13 14 15 16 17 18 19 20 21 22 23 24 25 26 27 28 29 30

Item 12 of 40
Question Id: 492

Mark | Previous | Next | Full Screen | Tutorial | Lab Values | Notes | Calculator | Reverse Color | Text Zoom | Settings

12-24 hours after the inciting event, appearing as shrunken cells separated from the surrounding tissue. The **nucleus** becomes **pyknotic**

Exhibit Display

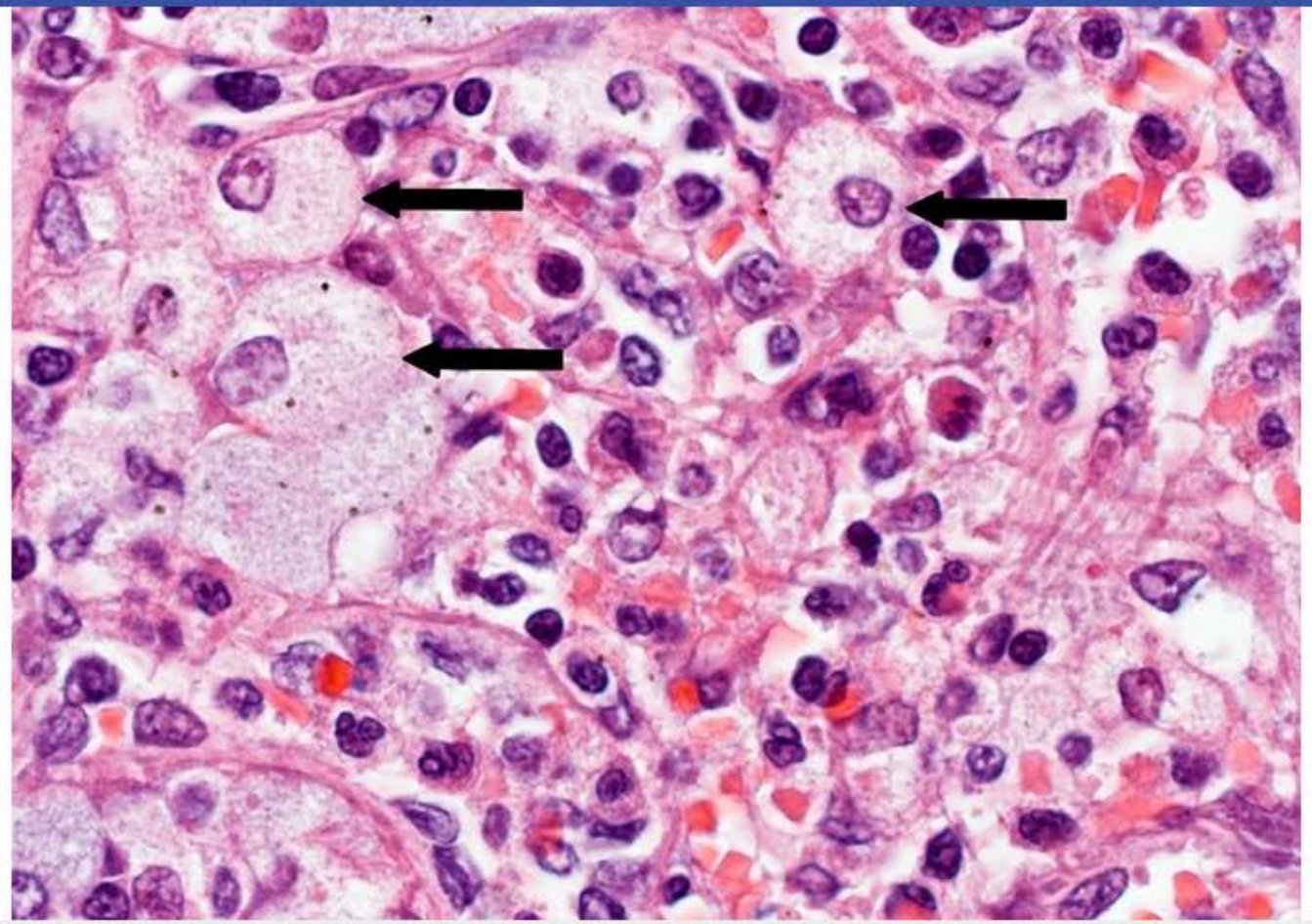

Zoom In | Zoom Out | Reset | Add To New Card | Existing Card

Block Time Remaining: 00:00:29
TUTOR

5 | Feedback | Suspend | End Block

hydrolytic enzymes released from reacting inflammatory cells and damaged neurons. The necrotic neuronal remnants are then phagocytized by microglia, and astrocytes proliferate at the site of the injury to form a glial scar.

(Choice A) Several neurodegenerative diseases (eg, Alzheimer disease, frontotemporal lobar degeneration) are characterized by intracellular and/or extracellular accumulation of abnormal proteins in neural tissue. Histologic examination of affected areas demonstrates proteinaceous plaques, tangles, and/or inclusions with reactive gliosis and loss of neurons.

(Choice B) Normal aging is associated with progressive atrophy and neuronal loss. However, red neuron changes are not characteristic of age-related physiologic changes.

(Choice C) Lysosomal storage diseases (eg, Tay-Sachs, Niemann-Pick) cause the accumulation of improperly digested substances in lysosomes, leading to neural degeneration through free radical damage and apoptosis. Expected histopathologic changes include enlarged neuronal cells with a foamy appearance due to accumulated undigested macromolecules.

(Choice E) Extensive axon damage or transection results in an axonal reaction characterized by cell body swelling, movement of the nucleus to the periphery, and dispersion of Nissl bodies. This response occurs due to increased protein and lipid synthesis during axon regeneration.

(Choice F) Transient neural compression can lead to a temporary loss of function due to ischemia but would not lead to significant histopathologic changes unless the compression was sustained. Neural compression may occur in the CNS due to increased intracranial pressure or a mass lesion.

Educational objective:
Neurons that sustain irreversible ischemic injury begin to develop characteristic histopathologic changes 12-24 hours after the inciting event. These changes include shrinkage of the cell body, pyknosis of the nucleus, loss of Nissl bodies, and cytoplasmic eosinophilia (red neurons).

Pathology	Nervous System	Ischemic stroke
Subject	System	Topic

Copyright © UWorld. All rights reserved.

Settings

1 2 3 4 5 6 7 8 9 10 11 12 13 14 15 16 17 18 19 20 21 22 23 24 25 26 27 28 29 30

Item 13 of 40
Question Id: 1263

Mark | Previous | Next | Full Screen | Tutorial | Lab Values | Notes | Calculator | Reverse Color | Text Zoom | Settings

An 11-month-old boy is brought to the office due to irregular jerking movements. His mother states that for 2 weeks he has looked pale and tired, and he has been more fussy and less playful than usual. Temperature is 36.7 C (98 F), blood pressure is 100/60 mm Hg, pulse is 114/min, and respirations are 16/min. Physical examination reveals spontaneous bursts of nonrhythmic conjugate eye movements in various directions. The patient also has myoclonus involving the trunk and limbs as well as generalized hypotonia. A right-sided, nontender, immobile abdominal mass is palpated. There is no hepatosplenomegaly, and bowel sounds are normal. Complete blood count reveals anemia, and urine is positive for elevated levels of catecholamine breakdown products. Which of the following is the most likely diagnosis?

- A. Carcinoid tumor
- B. Ewing sarcoma
- C. Medulloblastoma
- D. Neuroblastoma
- E. Non-Hodgkin lymphoma
- F. Pheochromocytoma
- G. Wilms tumor

Submit

Block Time Remaining: 00:00:31
TUTOR

6 | Feedback | Suspend | End Block

Settings

1 2 3 4 5 6 7 8 9 10 11 12 13 14 15 16 17 18 19 20 21 22 23 24 25 26 27 28 29 30

Item 13 of 40
Question Id: 1263

Mark | Previous | Next | Full Screen | Tutorial | Lab Values | Notes | Calculator | Reverse Color | Text Zoom | Settings

An 11-month-old boy is brought to the office due to irregular jerking movements. His mother states that for 2 weeks he has looked pale and tired, and he has been more fussy and less playful than usual. Temperature is 36.7 C (98 F), blood pressure is 100/60 mm Hg, pulse is 114/min, and respirations are 16/min. Physical examination reveals spontaneous bursts of nonrhythmic conjugate eye movements in various directions. The patient also has myoclonus involving the trunk and limbs as well as generalized hypotonia. A right-sided, nontender, immobile abdominal mass is palpated. There is no hepatosplenomegaly, and bowel sounds are normal. Complete blood count reveals anemia, and urine is positive for elevated levels of catecholamine breakdown products. Which of the following is the most likely diagnosis?

- A. Carcinoid tumor (4%)
- B. Ewing sarcoma (1%)
- C. Medulloblastoma (5%)
- ✓ D. Neuroblastoma (50%)
- E. Non-Hodgkin lymphoma (0%)
- F. Pheochromocytoma (21%)
- G. Wilms tumor (14%)

Omitted
Correct answer
D

50%
Answered correctly

04 secs
Time Spent

04/03/2020
Last Updated

Explanation

Block Time Remaining: 00:00:33
TUTOR

6 | Feedback | Suspend | End Block

Neuroblastoma	
Pathogenesis	• Neural crest origin • Involves adrenal medulla, sympathetic chain
Clinical features	• Median age <2 • Abdominal mass • Periorbital ecchymoses (orbital metastases) • Spinal cord compression from epidural invasion ("dumbbell tumor") • Opsoclonus-myoclonus syndrome
Diagnostic findings	• Elevated catecholamine metabolites • Small, round blue cells on histology • *N-myc* gene amplification

Nonrhythmic conjugate eye movements and involuntary jerking movements of the trunk and limbs (**opsoclonus-myoclonus syndrome**) in a young patient should prompt evaluation for **neuroblastoma**. This is the most common extracranial solid neoplasm of childhood and arises from neural crest cells of the adrenal medulla or sympathetic ganglia.

Patients typically present at age <2 with a firm **abdominal mass**, most often involving the adrenal gland, and constitutional symptoms (eg, weight loss, fatigue). Bone marrow infiltration can cause anemia or pancytopenia, and orbital metastases may result in proptosis and/or **periorbital ecchymoses**. Although rare, opsoclonus-myoclonus is a paraneoplastic syndrome highly associated with neuroblastoma and is believed to be an autoantibody response to central nervous system antigens.

The majority of patients with neuroblastoma have **elevated catecholamine metabolites** (eg, HVA, VMA) due to the neural crest origin. Biopsy of the mass is diagnostic and will reveal small round blue cells and Homer Wright rosettes. Tumor tissue is subsequently tested for ***N-myc* amplification**, which predicts a poor prognosis.

(Choice A) Carcinoid tumor is a neuroendocrine tumor that is rare in children. Tumor secretion of serotonin causes carcinoid syndrome (eg,

Nonrhythmic conjugate eye movements and involuntary jerking movements of the trunk and limbs (**opsoclonus-myoclonus syndrome**) in a young patient should prompt evaluation for **neuroblastoma**. This is the most common extracranial solid neoplasm of childhood and arises from neural crest cells of the adrenal medulla or sympathetic ganglia.

Patients typically present at age <2 with a firm **abdominal mass**, most often involving the adrenal gland, and constitutional symptoms (eg, weight loss, fatigue). Bone marrow infiltration can cause anemia or pancytopenia, and orbital metastases may result in proptosis and/or **periorbital ecchymoses**. Although rare, opsoclonus-myoclonus is a paraneoplastic syndrome highly associated with neuroblastoma and is believed to be an autoantibody response to central nervous system antigens.

The majority of patients with neuroblastoma have **elevated catecholamine metabolites** (eg, HVA, VMA) due to the neural crest origin. Biopsy of the mass is diagnostic and will reveal small round blue cells and Homer Wright rosettes. Tumor tissue is subsequently tested for ***N-myc* amplification**, which predicts a poor prognosis.

(Choice A) Carcinoid tumor is a neuroendocrine tumor that is rare in children. Tumor secretion of serotonin causes carcinoid syndrome (eg, flushing, diarrhea, bronchospasm) and increased 5-hydroxyindoleacetic acid (serotonin metabolite) in the urine.

(Choice B) Ewing sarcoma is a malignant bone tumor that arises predominantly in long bones. This neoplasm typically presents in older children and teenagers with pain and swelling over the mass.

(Choice C) Medulloblastoma is the most common malignant brain tumor in children. It arises in the cerebellum and causes ataxia, not opsoclonus-myoclonus. As in neuroblastoma, Homer Wright rosettes may be identified; however, urine catecholamine metabolites would not be present.

(Choice E) Non-Hodgkin lymphoma can present as an abdominal mass but is rare in infants and not associated with opsoclonus-myoclonus or increased urine catecholamines.

(Choice F) Pheochromocytoma is an adrenal tumor that also secretes catecholamines; however, this neoplasm occurs more commonly in adults and is not associated with opsoclonus-myoclonus.

(Choice G) Wilms tumor is a renal cancer that presents in early childhood (median age 3-4) with an abdominal/flank mass. In contrast to neuroblastoma, Wilms tumor does not cause opsoclonus-myoclonus or result in catecholamines in the urine.

Settings

1 2 3 4 5 6 7 8 9 10 11 12 13 14 15 16 17 18 19 20 21 22 23 24 25 26 27 28 29 30

Item 13 of 40
Question Id: 1263

Mark | Previous | Next | Full Screen | Tutorial | Lab Values | Notes | Calculator | Reverse Color | Text Zoom | Settings

Nonrhythmic conjugate eye movements and involuntary jerking movements of the trunk and limbs (opsoclonus-myoclonus syndrome) in a

Exhibit Display

Neuroblastoma Neuroblastoma

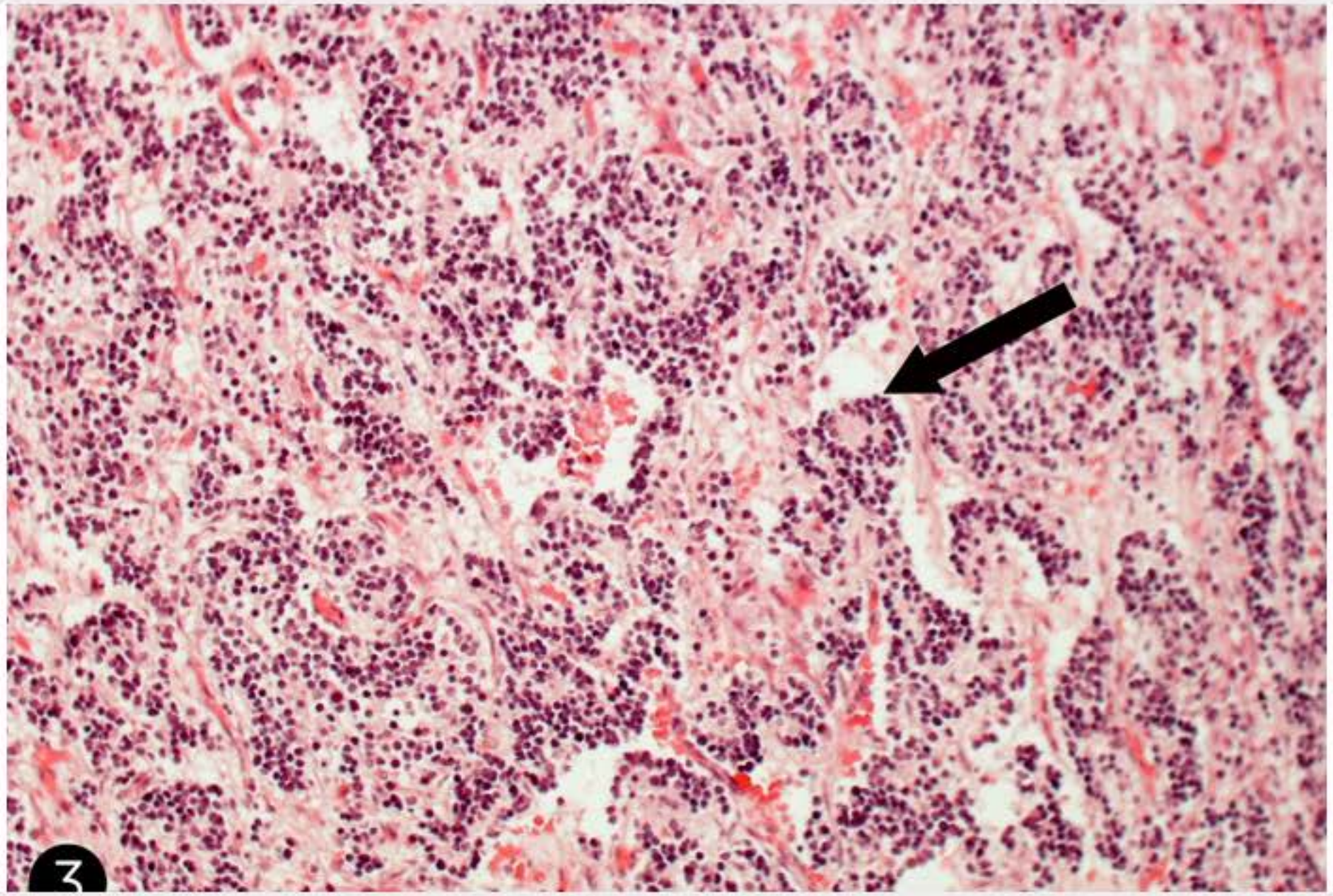

Zoom In | Zoom Out | Reset | Add To New Card | Existing Card

neuroblastoma. Wilms tumor does not cause opsoclonus-myoclonus or result in catecholamines in the urine.

Block Time Remaining: 00:00:33
TUTOR

6 | Feedback | Suspend | End Block

Settings

1 2 3 4 5 6 7 8 9 10 11 12 13 14 15 16 17 18 19 20 21 22 23 24 25 26 27 28 29 30

Item 13 of 40
Question Id: 1263

Mark | Previous | Next | Full Screen | Tutorial | Lab Values | Notes | Calculator | Reverse Color | Text Zoom | Settings

Nonrhythmic conjugate eye movements and involuntary jerking movements of the trunk and limbs (**opsoclonus-myoclonus syndrome**) in a

Exhibit Display

Neuroblastoma Neuroblastoma

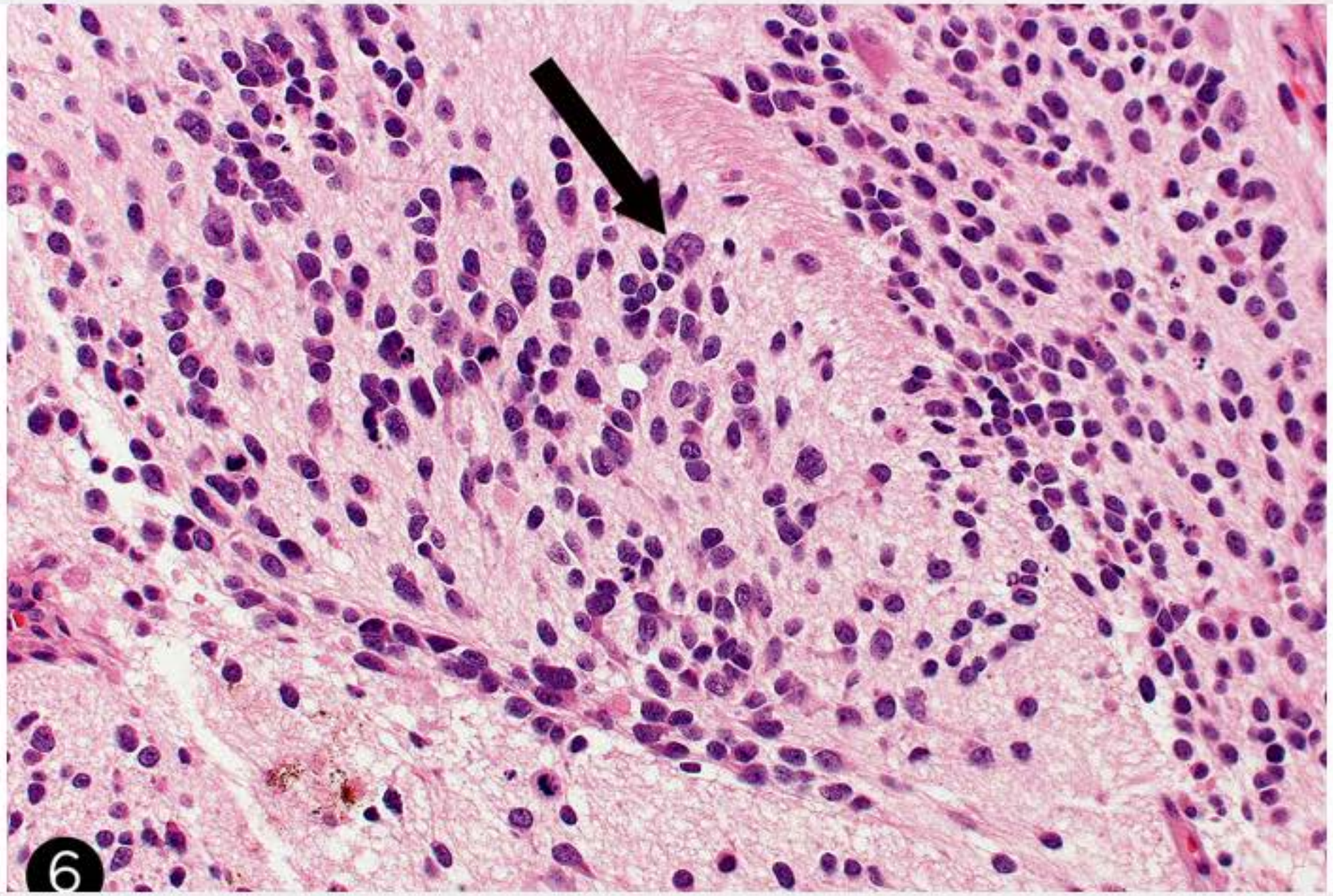

Zoom In | Zoom Out | Reset | Add To New Card | Existing Card

neuroblastoma. Wilms tumor does not cause opsoclonus-myoclonus or result in catecholamines in the urine.

Block Time Remaining: 00:00:33
TUTOR

6 | Feedback | Suspend | End Block

Settings

1 2 3 4 5 6 7 8 9 10 11 12 13 14 15 16 17 18 19 20 21 22 23 24 25 26 27 28 29 30

Item 13 of 40
Question Id: 1263

Mark | Previous | Next | Full Screen | Tutorial | Lab Values | Notes | Calculator | Reverse Color | Text Zoom | Settings

Nonrhythmic conjugate eye movements and involuntary jerking movements of the trunk and limbs (**opsoclonus-myoclonus syndrome**) in a

Exhibit Display

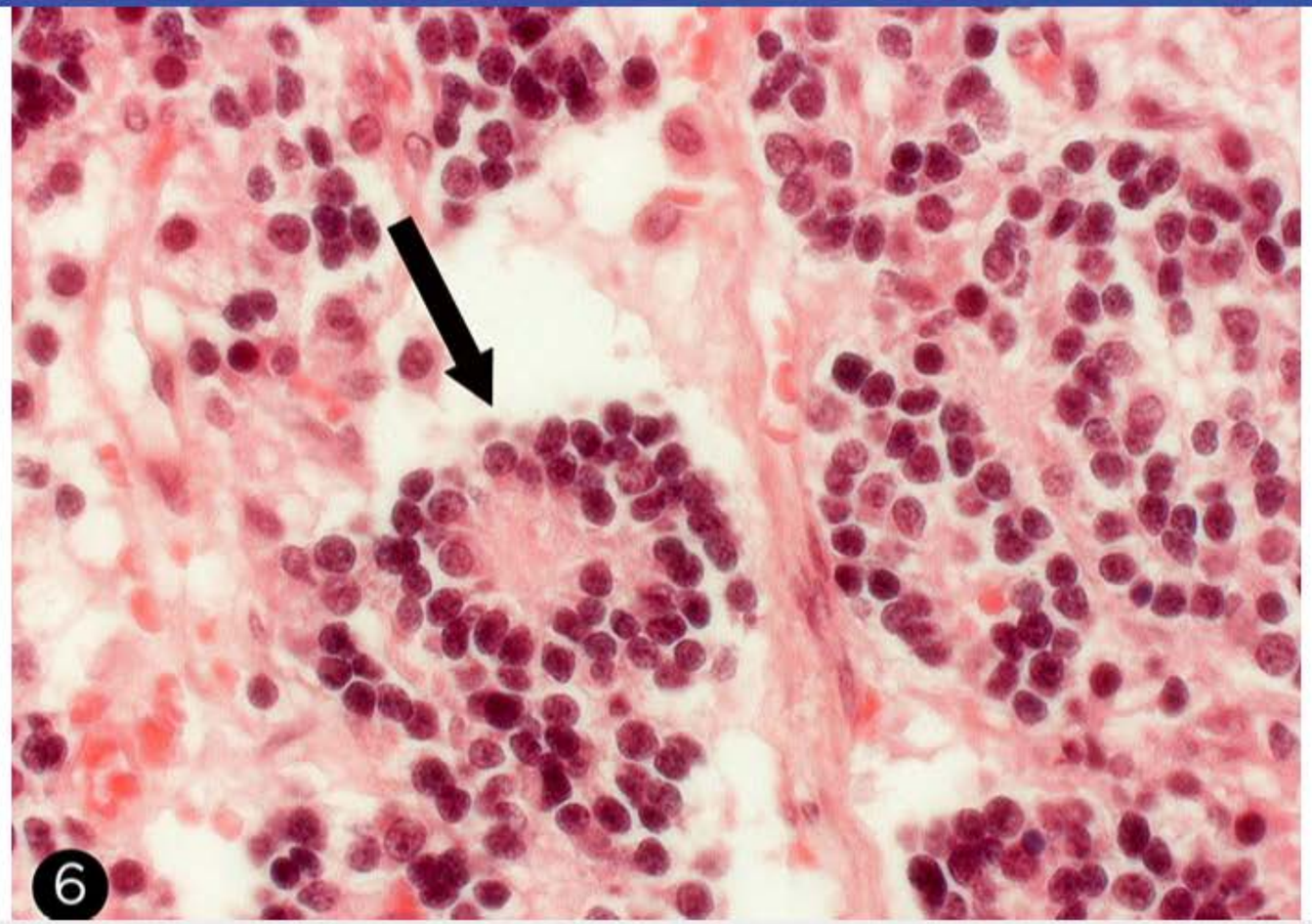

Zoom In | Zoom Out | Reset | Add To New Card | Existing Card

neuroblastoma. Wilms tumor does not cause opsoclonus-myoclonus or result in catecholamines in the urine.

Block Time Remaining: 00:00:33
TUTOR

6 | Feedback | Suspend | End Block

1 2 3 4 5 6 7 8 9 10 11 12 13 14 15 16 17 18 19 20 21 22 23 24 25 26 27 28 29 30

(Choice B) Ewing sarcoma is a malignant bone tumor that arises predominantly in long bones. This neoplasm typically presents in older children and teenagers with pain and swelling over the mass.

(Choice C) Medulloblastoma is the most common malignant brain tumor in children. It arises in the cerebellum and causes ataxia, not opsoclonus-myoclonus. As in neuroblastoma, Homer Wright rosettes may be identified; however, urine catecholamine metabolites would not be present.

(Choice E) Non-Hodgkin lymphoma can present as an abdominal mass but is rare in infants and not associated with opsoclonus-myoclonus or increased urine catecholamines.

(Choice F) Pheochromocytoma is an adrenal tumor that also secretes catecholamines; however, this neoplasm occurs more commonly in adults and is not associated with opsoclonus-myoclonus.

(Choice G) Wilms tumor is a renal cancer that presents in early childhood (median age 3-4) with an abdominal/flank mass. In contrast to neuroblastoma, Wilms tumor does not cause opsoclonus-myoclonus or result in catecholamines in the urine.

Educational objective:
Opsoclonus-myoclonus is a paraneoplastic syndrome associated with neuroblastoma, the most common extracranial solid neoplasm in children. The tumor typically arises from the neural crest cells of the adrenal medulla and presents with an abdominal mass and elevated catecholamine breakdown products.

References

- Neuroblastoma presenting as opsoclonus-myoclonus: a series of six cases and review of literature.
- Update on pediatric opsoclonus myoclonus syndrome.

Pathology	Nervous System	Neuroblastoma
Subject	System	Topic

Copyright © UWorld. All rights reserved.

Settings

1 2 3 4 5 6 7 8 9 10 11 12 13 14 15 16 17 18 19 20 21 22 23 24 25 26 27 28 29 30

Item 14 of 40
Question Id: 494

Mark | Previous | Next | Full Screen | Tutorial | Lab Values | Notes | Calculator | Reverse Color | Text Zoom | Settings

Anterior horn cells of the spinal cord of an experimental animal demonstrate cell body rounding, peripheral displacement of the nuclei and dispersion of Nissl substance to the periphery of the cells. The findings described most likely indicate:

A. Degenerative disease

B. Irreversible cell injury

C. Axonal reaction

D. Compression atrophy

E. Normal aging

Submit

Block Time Remaining: 00:00:33
TUTOR

2 | Feedback | Suspend | End Block

1 2 3 4 5 6 7 8 9 10 11 12 13 14 15 16 17 18 19 20 21 22 23 24 25 26 27 28 29 30

Anterior horn cells of the spinal cord of an experimental animal demonstrate cell body rounding, peripheral displacement of the nuclei and dispersion of Nissl substance to the periphery of the cells. The findings described most likely indicate:

- A. Degenerative disease (17%)
- B. Irreversible cell injury (29%)
- ✓ C. Axonal reaction (36%)
- D. Compression atrophy (8%)
- E. Normal aging (8%)

Omitted
Correct answer
C

36%
Answered correctly

02 secs
Time Spent

02/03/2020
Last Updated

Explanation

Sometimes axons become severed due to trauma. Such injury causes specific changes in both the proximal and distal segments of the axon, as well as in the neuronal body.

Wallerian degeneration occurs in the segment of axon that has lost connection with the cell body. It represents the degeneration of axon and myelin distal to a point of injury. First, swelling and irregularity are noted in the distal segment of the axon. Within a week the axon is destroyed and its fragments are digested by Schwann cells and macrophages. Similar degenerative changes occur in the segment of axon that lies proximal to the injury. Degeneration of the proximal segment extends to the closest node of Ranvier.

Sometimes axons become severed due to trauma. Such injury causes specific changes in both the proximal and distal segments of the axon, as well as in the neuronal body.

Wallerian degeneration occurs in the segment of axon that has lost connection with the cell body. It represents the degeneration of axon and myelin distal to a point of injury. First, swelling and irregularity are noted in the distal segment of the axon. Within a week the axon is destroyed and its fragments are digested by Schwann cells and macrophages. Similar degenerative changes occur in the segment of axon that lies proximal to the injury. Degeneration of the proximal segment extends to the closest node of Ranvier.

The changes seen in the neuronal body after the axon is severed are called ***axonal reaction.*** The cell body shows signs of cellular edema. It becomes swollen and rounded, with the nucleus displaced to the periphery. Nissl substance becomes fine, granular and dispersed throughout the cytoplasm (central chromatolysis). Axonal reaction becomes visible in 24-48 hours after the injury. Maximal changes in the neuronal body occur approximately 12 days after the injury. These changes reflect an increased synthesis of protein by the cells in order to regenerate the severed axon.

(Choice A) Degenerative diseases are characterized by progressive loss of neurons with associated reactive glial changes. Neuronal loss in these conditions is selective: it affects one or more well-defined neuronal groups. Alzheimer's, Pick's, and Huntington's disease are all examples of degenerative disorders.

(Choice B) Transient but profound hypoxia, ischemia or toxic injury may lead to the loss of neurons. Irreversible neuronal injury manifests with shrinkage of the neuronal body, deep eosinophilia of the cytoplasm, pyknosis of the nucleus and loss of Nissl substance.

(Choice D) Compression atrophy may occur due to increased intracranial pressure or a mass lesion. A decrease in the size and number of neurons is characteristic of compression atrophy.

(Choice E) Normal aging is characterized by atrophy and gradual neuronal loss. Axonal reaction is not associated with this process.

Educational Objective:
The changes in the body of a neuron after the axon has been severed are called axonal reaction. This process reflects an increased protein synthesis that facilitates axon repair. Enlarged, rounded cells with peripherally located nuclei and dispersed finely granular Nissl substance are

to the injury. Degeneration of the proximal segment extends to the closest node of Ranvier.

The changes seen in the neuronal body after the axon is severed are called ***axonal reaction.*** The cell body shows signs of cellular edema. It becomes swollen and rounded, with the nucleus displaced to the periphery. Nissl substance becomes fine, granular and dispersed throughout the cytoplasm (central chromatolysis). Axonal reaction becomes visible in 24-48 hours after the injury. Maximal changes in the neuronal body occur approximately 12 days after the injury. These changes reflect an increased synthesis of protein by the cells in order to regenerate the severed axon.

(Choice A) Degenerative diseases are characterized by progressive loss of neurons with associated reactive glial changes. Neuronal loss in these conditions is selective: it affects one or more well-defined neuronal groups. Alzheimer's, Pick's, and Huntington's disease are all examples of degenerative disorders.

(Choice B) Transient but profound hypoxia, ischemia or toxic injury may lead to the loss of neurons. Irreversible neuronal injury manifests with shrinkage of the neuronal body, deep eosinophilia of the cytoplasm, pyknosis of the nucleus and loss of Nissl substance.

(Choice D) Compression atrophy may occur due to increased intracranial pressure or a mass lesion. A decrease in the size and number of neurons is characteristic of compression atrophy.

(Choice E) Normal aging is characterized by atrophy and gradual neuronal loss. Axonal reaction is not associated with this process.

Educational Objective:
The changes in the body of a neuron after the axon has been severed are called axonal reaction. This process reflects an increased protein synthesis that facilitates axon repair. Enlarged, rounded cells with peripherally located nuclei and dispersed finely granular Nissl substance are seen.

Pathology	Nervous System	Neuronal physiology
Subject	System	Topic

Copyright © UWorld. All rights reserved.

Settings

1 2 3 4 5 6 7 8 9 10 11 12 13 14 15 16 17 18 19 20 21 22 23 24 25 26 27 28 29 30

Item 15 of 40
Question Id: 593

Mark | Previous | Next | Full Screen | Tutorial | Lab Values | Notes | Calculator | Reverse Color | Text Zoom | Settings

A 72-year-old woman comes to the office for a routine follow-up visit accompanied by her son. The patient has experienced progressive memory loss over the last 2 years. She now needs help with her daily activities, such as shopping and housekeeping. The patient's son says, "She used to be such an independent person, but now she needs help with most things. She even forgot my name the other day!" Medical history includes hypertension, hyperlipidemia, and type 2 diabetes mellitus. Family history includes major depressive disorder in her father. MRI reveals diffuse cortical and hippocampal atrophy. Which of the following biochemical changes is most likely contributing to this patient's condition?

- A. Decreased choline acetyltransferase activity in the nucleus basalis
- B. Decreased dopa decarboxylase activity in the substantia nigra
- C. Decreased tryptophan hydroxylase activity in the raphe nuclei
- D. Increased acetylcholinesterase activity in the caudate nucleus
- E. Increased dopamine beta-hydroxylase activity in the locus ceruleus

Submit

Block Time Remaining: 00:00:35
TUTOR

3 | Feedback | Suspend | End Block

1 2 3 4 5 6 7 8 9 10 11 12 13 14 15 16 17 18 19 20 21 22 23 24 25 26 27 28 29 30

A 72-year-old woman comes to the office for a routine follow-up visit accompanied by her son. The patient has experienced progressive memory loss over the last 2 years. She now needs help with her daily activities, such as shopping and housekeeping. The patient's son says, "She used to be such an independent person, but now she needs help with most things. She even forgot my name the other day!" Medical history includes hypertension, hyperlipidemia, and type 2 diabetes mellitus. Family history includes major depressive disorder in her father. MRI reveals diffuse cortical and hippocampal atrophy. Which of the following biochemical changes is most likely contributing to this patient's condition?

- ✓ A. Decreased choline acetyltransferase activity in the nucleus basalis (67%)
- B. Decreased dopa decarboxylase activity in the substantia nigra (6%)
- C. Decreased tryptophan hydroxylase activity in the raphe nuclei (6%)
- D. Increased acetylcholinesterase activity in the caudate nucleus (17%)
- E. Increased dopamine beta-hydroxylase activity in the locus ceruleus (3%)

Omitted
Correct answer
A

67%
Answered correctly

01 sec
Time Spent

02/10/2020
Last Updated

Explanation

Clinical features of Alzheimer disease	
Early	• Anterograde memory loss (ie, immediate recall affected, distant memories preserved) • Visuospatial deficits (eg, lost in own neighborhood)

Explanation

Clinical features of Alzheimer disease	
Early findings	• Anterograde memory loss (ie, immediate recall affected, distant memories preserved) • Visuospatial deficits (eg, lost in own neighborhood) • Language difficulties (eg, difficulty finding words) • Cognitive impairment with progressive decline
Late findings	• Neuropsychiatric (eg, hallucinations, wandering) • Dyspraxia (eg, difficulty performing learned motor tasks) • Lack of insight regarding deficits • Noncognitive neurologic deficits (eg, pyramidal & extrapyramidal motor, myoclonus, seizures) • Urinary incontinence

Alzheimer disease (AD) is the most common cause of dementia. It has the following characteristic features:

- Prevailing clinical symptom: slow, progressive memory loss
- Macroscopic brain appearance: mild-to-moderate generalized brain atrophy
- Microscopic brain changes: neurofibrillary tangles, senile plaques, and amyloid angiopathy
- Biochemical abnormalities: decreased acetylcholine levels in the hippocampus and nucleus basalis of Meynert

The most important biochemical abnormality noted in AD is a **decrease** in the **acetylcholine level**. This occurs due to a **deficiency** of **choline acetyltransferase**. The decline in acetylcholine is most notable in the **nucleus basalis of Meynert**, which participates in memory and cognition. This nucleus is located at the base of the forebrain and widely projects to the neocortex. Another involved structure is the **hippocampus**: The major function of the hippocampus is the formation of new memories.

Symptomatic management of AD includes cholinesterase inhibitors, which target the acetylcholine deficit by inhibiting the degradation of acetylcholine at the synaptic cleft.

Alzheimer disease (AD) is the most common cause of dementia. It has the following characteristic features:

- Prevailing clinical symptom: slow, progressive memory loss
- Macroscopic brain appearance: mild-to-moderate generalized brain atrophy
- Microscopic brain changes: neurofibrillary tangles, senile plaques, and amyloid angiopathy
- Biochemical abnormalities: decreased acetylcholine levels in the hippocampus and nucleus basalis of Meynert

The most important biochemical abnormality noted in AD is a **decrease** in the **acetylcholine level**. This occurs due to a **deficiency** of **choline acetyltransferase**. The decline in acetylcholine is most notable in the **nucleus basalis of Meynert**, which participates in memory and cognition. This nucleus is located at the base of the forebrain and widely projects to the neocortex. Another involved structure is the **hippocampus**: The major function of the hippocampus is the formation of new memories.

Symptomatic management of AD includes cholinesterase inhibitors, which target the acetylcholine deficit by inhibiting the degradation of acetylcholine at the synaptic cleft.

(Choice B) Loss of dopaminergic neurons in the substantia nigra is seen in Parkinson disease and dementia with Lewy bodies.

(Choice C) The raphe nuclei form the medial part of the brain stem's reticular formation (medulla, pons, and midbrain). Many neurons in the nuclei are serotonergic. Serotonin is implicated in the pathogenesis of anorexia, depression, and sleep disorders.

(Choice D) Atrophy of the caudate nucleus is seen in Huntington disease.

(Choice E) The locus ceruleus is thought to play a role in the pathogenesis of panic attacks and panic disorder. It is located in the pons and contains cell bodies of noradrenergic neurons that synthesize norepinephrine.

Educational objective:
Alzheimer disease is characterized by decreased levels of acetylcholine in the nucleus basalis of Meynert and the hippocampus, caused by diminished activity of choline acetyltransferase.

References

- Alzheimer's disease: targeting the cholinergic system.

The most important biochemical abnormality noted in AD is a **decrease** in the **acetylcholine level**. This occurs due to a **deficiency** of **choline acetyltransferase**. The decline in acetylcholine is most notable in the **nucleus basalis of Meynert**, which participates in memory and cognition. This nucleus is located at the base of the forebrain and widely projects to the neocortex. Another involved structure is the **hippocampus**: The major function of the hippocampus is the formation of new memories.

Symptomatic management of AD includes cholinesterase inhibitors, which target the acetylcholine deficit by inhibiting the degradation of acetylcholine at the synaptic cleft.

(Choice B) Loss of dopaminergic neurons in the substantia nigra is seen in Parkinson disease and dementia with Lewy bodies.

(Choice C) The raphe nuclei form the medial part of the brain stem's reticular formation (medulla, pons, and midbrain). Many neurons in the nuclei are serotonergic. Serotonin is implicated in the pathogenesis of anorexia, depression, and sleep disorders.

(Choice D) Atrophy of the caudate nucleus is seen in Huntington disease.

(Choice E) The locus ceruleus is thought to play a role in the pathogenesis of panic attacks and panic disorder. It is located in the pons and contains cell bodies of noradrenergic neurons that synthesize norepinephrine.

Educational objective:
Alzheimer disease is characterized by decreased levels of acetylcholine in the nucleus basalis of Meynert and the hippocampus, caused by diminished activity of choline acetyltransferase.

References

- Alzheimer's disease: targeting the cholinergic system.

Pathology	Nervous System	Alzheimer disease
Subject	System	Topic

Copyright © UWorld. All rights reserved.

Settings

1 2 3 4 5 6 7 8 9 10 11 12 13 14 15 16 17 18 19 20 21 22 23 24 25 26 27 28 29 30

Item 16 of 40
Question Id: 597

Mark | Previous | Next | Full Screen | Tutorial | Lab Values | Notes | Calculator | Reverse Color | Text Zoom | Settings

A 64-year-old man is hospitalized with abdominal pain, nausea, and vomiting. The patient has had several similar episodes in the past and was advised to avoid alcohol consumption. Evaluation reveals epigastric tenderness and elevated serum amylase and lipase levels. The patient is admitted, and treatment with bowel rest and intravenous fluids is begun. During hospitalization, he develops new-onset confusion. Physical examination shows horizontal nystagmus and gait ataxia. Brain imaging reveals abnormalities in the mammillary bodies and periaqueductal gray matter. Which of the following most likely precipitated this patient's current neurologic condition?

- A. Abrupt alcohol cessation
- B. Excessive hydration
- C. Glucose infusion
- D. Hypotonic fluid administration
- E. Lack of anticoagulant use
- F. Vitamin supplementation

Submit

Block Time Remaining: 00:00:36
TUTOR

3 | Feedback | Suspend | End Block

1 2 3 4 5 6 7 8 9 10 11 12 13 14 15 16 17 18 19 20 21 22 23 24 25 26 27 28 29 30

A 64-year-old man is hospitalized with abdominal pain, nausea, and vomiting. The patient has had several similar episodes in the past and was advised to avoid alcohol consumption. Evaluation reveals epigastric tenderness and elevated serum amylase and lipase levels. The patient is admitted, and treatment with bowel rest and intravenous fluids is begun. During hospitalization, he develops new-onset confusion. Physical examination shows horizontal nystagmus and gait ataxia. Brain imaging reveals abnormalities in the mammillary bodies and periaqueductal gray matter. Which of the following most likely precipitated this patient's current neurologic condition?

- A. Abrupt alcohol cessation (15%)
- B. Excessive hydration (5%)
- ✓ C. Glucose infusion (64%)
- D. Hypotonic fluid administration (8%)
- E. Lack of anticoagulant use (0%)
- F. Vitamin supplementation (5%)

Omitted
Correct answer
C

64%
Answered correctly

02 secs
Time Spent

04/20/2020
Last Updated

Explanation

Features of Wernicke-Korsakoff syndrome	

Features of Wernicke-Korsakoff syndrome	
Associated conditions	• Chronic **alcoholism** (most common) • Malnutrition
Pathophysiology	• **Thiamine deficiency** → impairs ATP generation → neuronal dysfunction/death • Paraventricular lesions (eg, **mammillary bodies**, dorsomedial thalamus)
Clinical findings	• **Confusion** • **Oculomotor dysfunction** (eg, horizontal nystagmus & bilateral abducens palsy) • Postural & gait **ataxia** • Memory impairment (permanent)
Treatment	• Intravenous thiamine • Administration of glucose before thiamine can worsen symptoms

This patient with pancreatitis (nausea/vomiting, abdominal pain, elevated lipase) and a history of alcohol abuse received intravenous fluids and developed the classic triad of **Wernicke encephalopathy** (WE):

- **Oculomotor dysfunction**: horizontal nystagmus, lateral rectus palsy, ophthalmoplegia
- **Gait ataxia**: slow, wide-based gait; postural ataxia
- **Encephalopathy**: confusion, apathy, inattentiveness, disorientation

WE is a complication of **thiamine (vitamin B_1) deficiency** and most commonly occurs in patients with a history of long-standing **alcohol abuse** or other forms of chronic malnourishment (eg, anorexia, short-bowel syndrome). Thiamine is a vitamin cofactor for multiple enzymes involved in glucose metabolism, and deficiency results in the brain's inability to utilize glucose, leading to neuronal damage and necrosis. Iatrogenic WE can be precipitated by the administration of **glucose-containing fluids** (this patient likely received these as a maintenance fluid), which deplete the

- **Gait ataxia**: slow, wide-based gait; postural ataxia
- **Encephalopathy**: confusion, apathy, inattentiveness, disorientation

WE is a complication of **thiamine (vitamin B_1) deficiency** and most commonly occurs in patients with a history of long-standing **alcohol abuse** or other forms of chronic malnourishment (eg, anorexia, short-bowel syndrome). Thiamine is a vitamin cofactor for multiple enzymes involved in glucose metabolism, and deficiency results in the brain's inability to utilize glucose, leading to neuronal damage and necrosis. Iatrogenic WE can be precipitated by the administration of **glucose-containing fluids** (this patient likely received these as a maintenance fluid), which deplete the last remaining stores of thiamine. Areas of the brain with high metabolic demand are particularly susceptible; focal hemorrhage or atrophy of the **mammillary bodies** is characteristic. The periaqueductal gray, thalamus, and medulla may also be affected.

Intravenous thiamine should be administered before infusion of glucose-containing fluids in at-risk patients and in all patients with suspected WE. Ocular irregularities are the first to respond to thiamine and typically normalize within hours. Gait ataxia and confusion typically respond over the course of days to weeks.

(Choice A) Abrupt alcohol cessation can cause alcohol withdrawal. Tremor and diaphoresis are common and may progress to delirium, seizures, and death. Ataxia and ophthalmoplegia are unexpected.

(Choice B) Chronic hyponatremia can occur in patients with heavy alcohol use. Overly rapid correction with normal saline causes osmotic demyelination syndrome, which manifests as dysarthria, confusion, and paralysis. Some patients become "locked in" (ie, alert but unable to move or verbally communicate); however, extraocular muscles are spared.

(Choice D) Hypotonic fluid administration can result in acute hyponatremia, which can cause cerebral edema. Symptoms are typically progressive, with headache and nausea occurring before alterations in mental status. Ophthalmoplegia and ataxia are unexpected.

(Choice E) Prophylactic low-dose anticoagulation is typically recommended to prevent deep venous thrombosis (DVT) in patients with prolonged hospitalization or inactivity. Pulmonary embolism, the most common sequela of DVT, typically causes pleuritic chest pain, tachycardia, and dyspnea.

(Choice F) Thiamine supplementation is used for both prevention and treatment of WE; it does not precipitate the disease.

Intravenous thiamine should be administered before infusion of glucose-containing fluids in at-risk patients and in all patients with suspected WE. Ocular irregularities are the first to respond to thiamine and typically normalize within hours. Gait ataxia and confusion typically respond over the course of days to weeks.

(Choice A) Abrupt alcohol cessation can cause alcohol withdrawal. Tremor and diaphoresis are common and may progress to delirium, seizures, and death. Ataxia and ophthalmoplegia are unexpected.

(Choice B) Chronic hyponatremia can occur in patients with heavy alcohol use. Overly rapid correction with normal saline causes osmotic demyelination syndrome, which manifests as dysarthria, confusion, and paralysis. Some patients become "locked in" (ie, alert but unable to move or verbally communicate); however, extraocular muscles are spared.

(Choice D) Hypotonic fluid administration can result in acute hyponatremia, which can cause cerebral edema. Symptoms are typically progressive, with headache and nausea occurring before alterations in mental status. Ophthalmoplegia and ataxia are unexpected.

(Choice E) Prophylactic low-dose anticoagulation is typically recommended to prevent deep venous thrombosis (DVT) in patients with prolonged hospitalization or inactivity. Pulmonary embolism, the most common sequela of DVT, typically causes pleuritic chest pain, tachycardia, and dyspnea.

(Choice F) Thiamine supplementation is used for both prevention and treatment of WE; it does not precipitate the disease.

Educational objective:
Wernicke encephalopathy is a complication of thiamine deficiency characterized by encephalopathy, ataxia, and oculomotor dysfunction. It occurs most commonly in patients with chronic alcohol abuse and may be precipitated by infusion of glucose-containing fluids. Neuroimaging reveals focal hemorrhage or atrophy of the mammillary bodies.

Pathology	Nervous System	Wernicke korsakoff syndrome
Subject	System	Topic

Copyright © UWorld. All rights reserved.

Settings

1 2 3 4 5 6 7 8 9 10 11 12 13 14 15 16 17 18 19 20 21 22 23 24 25 26 27 28 29 30

Item 17 of 40
Question Id: 1152

Mark | Previous | Next | Full Screen | Tutorial | Lab Values | Notes | Calculator | Reverse Color | Text Zoom | Settings

A 12-year-old boy is evaluated for chronic headaches and visual changes. The headaches have progressively worsened over the past year and are associated with nausea. The patient's parents are especially concerned as his symptoms have been interfering with his coursework in middle school. An intracranial calcified mass is detected on brain imaging. The mass is surgically removed and on gross inspection shows cystic spaces filled with thick, brownish-yellow fluid that is rich in cholesterol. This mass is most likely derived from cells responsible for forming which of the following structures?

A. Anterior pituitary
B. Cerebellar vermis
C. Choroid plexus
D. Pineal gland
E. Retina

Submit

Block Time Remaining: 00:00:38
TUTOR

3 | Feedback | Suspend | End Block

1 2 3 4 5 6 7 8 9 10 11 12 13 14 15 16 17 18 19 20 21 22 23 24 25 26 27 28 29 30

A 12-year-old boy is evaluated for chronic headaches and visual changes. The headaches have progressively worsened over the past year and are associated with nausea. The patient's parents are especially concerned as his symptoms have been interfering with his coursework in middle school. An intracranial calcified mass is detected on brain imaging. The mass is surgically removed and on gross inspection shows cystic spaces filled with thick, brownish-yellow fluid that is rich in cholesterol. This mass is most likely derived from cells responsible for forming which of the following structures?

- ✓ A. Anterior pituitary (59%)
- B. Cerebellar vermis (5%)
- C. Choroid plexus (13%)
- D. Pineal gland (17%)
- E. Retina (4%)

Omitted
Correct answer
A

59%
Answered correctly

01 sec
Time Spent

07/01/2020
Last Updated

Explanation

Pituitary embryology

Settings

Item 17 of 40
Question Id: 1152

Mark | Previous | Next | Full Screen | Tutorial | Lab Values | Notes | Calculator | Reverse Color | Text Zoom | Settings

Pituitary embryology

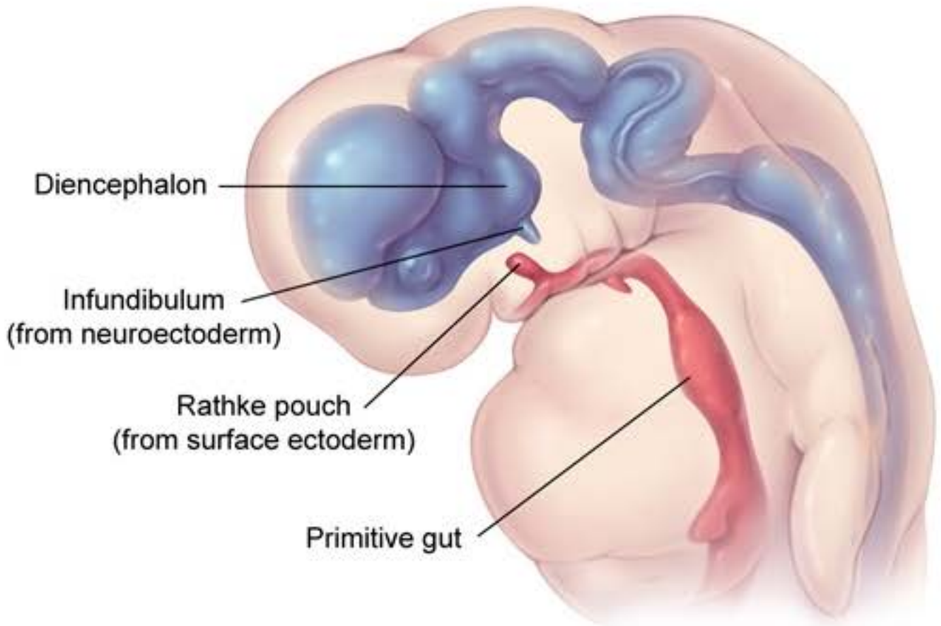

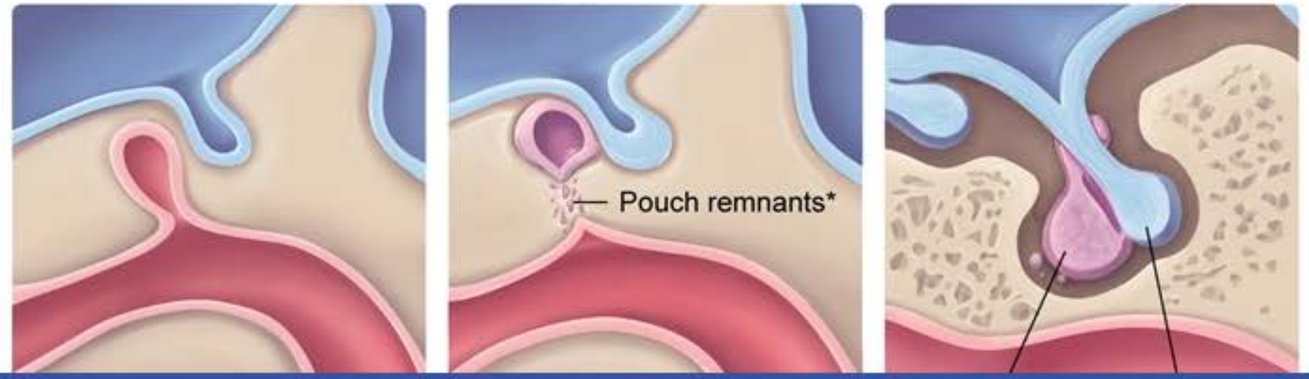

Block Time Remaining: 00:00:39
TUTOR

3 | Feedback | Suspend | End Block

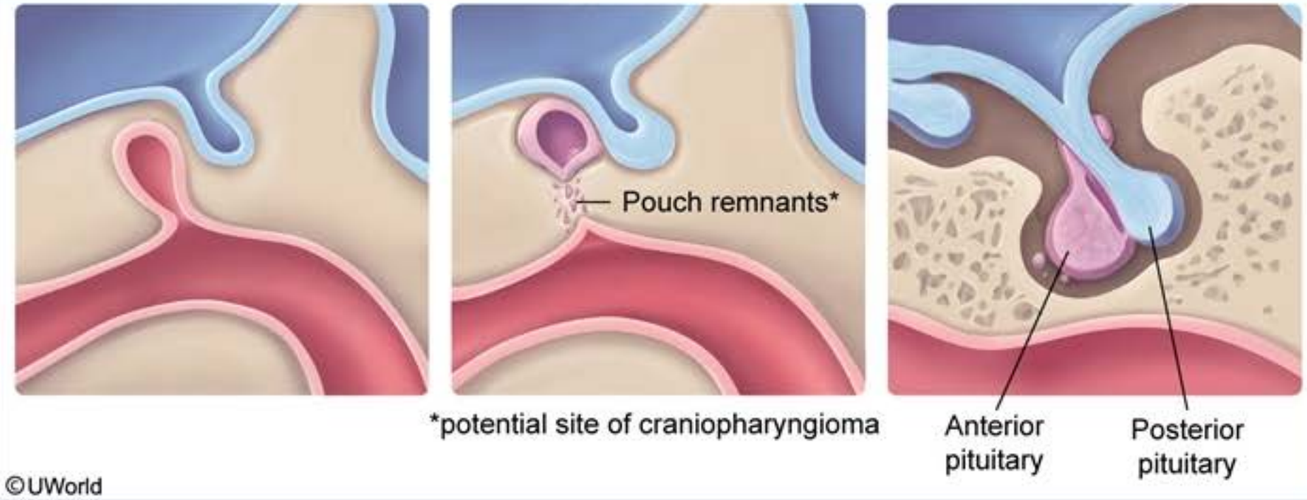

This patient most likely has an adamantinomatous **craniopharyngioma**. These are rare, slow-growing (benign) intracranial tumors found in children and typically located in the suprasellar region. On macroscopic examination, they are **cystic** or partially cystic with solid areas. The cysts are usually filled with a brownish-yellow, viscous fluid that resembles machine oil due to the presence of protein and **cholesterol crystals**. Dystrophic **calcification** of the cysts is highly characteristic and may be detected on neuroimaging. On light microscopy, the cysts are lined by cords/nests of stratified squamous epithelium with peripheral palisading and internal areas of lamellar "wet" keratin.

Craniopharyngiomas are derived from remnants of **Rathke's pouch**, which is an evagination of the surface ectoderm that lines the fetal oral cavity. This protrusion of the roof of the mouth forms the **anterior pituitary** gland (adenohypophysis). The posterior lobe of the pituitary (neurohypophysis) forms from an outpouching of the diencephalon (infundibulum) and is derived from neuroectoderm.

(Choices B, C, D, and E) The cerebellum, pineal gland, and retina are derived from neuroectoderm. Epithelial cells of the choroid plexus are also derived from neuroectoderm, whereas the mesenchyme (eg, blood vessels, connective tissue) is derived from mesoderm.

Educational objective:
Craniopharyngiomas are suprasellar tumors found in children and composed of calcified cysts containing cholesterol crystals. They arise from remnants of Rathke's pouch, an embryonic precursor of the anterior pituitary.

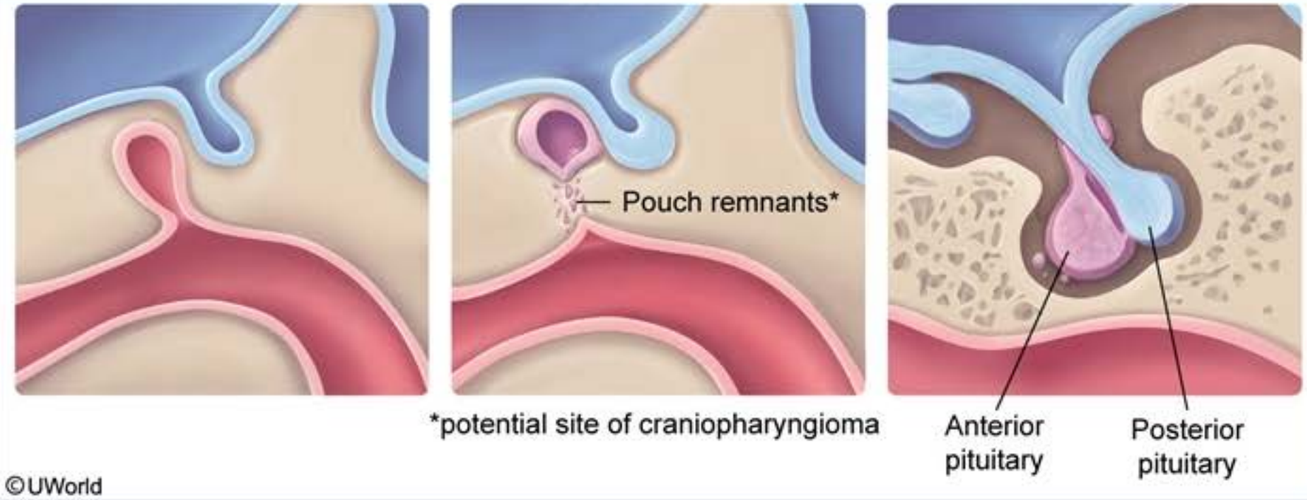

This patient most likely has an adamantinomatous **craniopharyngioma**. These are rare, slow-growing (benign) intracranial tumors found in children and typically located in the suprasellar region. On macroscopic examination, they are **cystic** or partially cystic with solid areas. The cysts are usually filled with a brownish-yellow, viscous fluid that resembles machine oil due to the presence of protein and **cholesterol crystals**. Dystrophic **calcification** of the cysts is highly characteristic and may be detected on neuroimaging. On light microscopy, the cysts are lined by cords/nests of stratified squamous epithelium with peripheral palisading and internal areas of lamellar "wet" keratin.

Craniopharyngiomas are derived from remnants of **Rathke's pouch**, which is an evagination of the surface ectoderm that lines the fetal oral cavity. This protrusion of the roof of the mouth forms the **anterior pituitary** gland (adenohypophysis). The posterior lobe of the pituitary (neurohypophysis) forms from an outpouching of the diencephalon (infundibulum) and is derived from neuroectoderm.

(Choices B, C, D, and E) The cerebellum, pineal gland, and retina are derived from neuroectoderm. Epithelial cells of the choroid plexus are also derived from neuroectoderm, whereas the mesenchyme (eg, blood vessels, connective tissue) is derived from mesoderm.

Educational objective:
Craniopharyngiomas are suprasellar tumors found in children and composed of calcified cysts containing cholesterol crystals. They arise from remnants of Rathke's pouch, an embryonic precursor of the anterior pituitary.

1 2 3 4 5 6 7 8 9 10 11 12 13 14 15 16 17 18 19 20 21 22 23 24 25 26 27 28 29 30

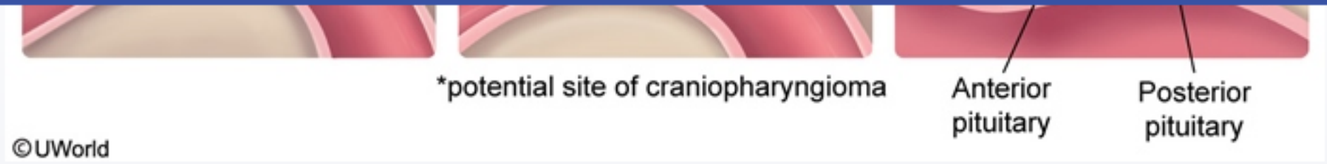

This patient most likely has an adamantinomatous **craniopharyngioma**. These are rare, slow-growing (benign) intracranial tumors found in children and typically located in the suprasellar region. On macroscopic examination, they are **cystic** or partially cystic with solid areas. The cysts are usually filled with a brownish-yellow, viscous fluid that resembles machine oil due to the presence of protein and **cholesterol crystals**. Dystrophic **calcification** of the cysts is highly characteristic and may be detected on neuroimaging. On light microscopy, the cysts are lined by cords/nests of stratified squamous epithelium with peripheral palisading and internal areas of lamellar "wet" keratin.

Craniopharyngiomas are derived from remnants of **Rathke's pouch**, which is an evagination of the surface ectoderm that lines the fetal oral cavity. This protrusion of the roof of the mouth forms the **anterior pituitary** gland (adenohypophysis). The posterior lobe of the pituitary (neurohypophysis) forms from an outpouching of the diencephalon (infundibulum) and is derived from neuroectoderm.

(Choices B, C, D, and E) The cerebellum, pineal gland, and retina are derived from neuroectoderm. Epithelial cells of the choroid plexus are also derived from neuroectoderm, whereas the mesenchyme (eg, blood vessels, connective tissue) is derived from mesoderm.

Educational objective:
Craniopharyngiomas are suprasellar tumors found in children and composed of calcified cysts containing cholesterol crystals. They arise from remnants of Rathke's pouch, an embryonic precursor of the anterior pituitary.

References

- Craniopharyngioma: a pathologic, clinical, and surgical review.

Pathology	Nervous System	Craniopharyngiomas
Subject	System	Topic

Copyright © UWorld. All rights reserved.

Settings

1
2
3
4
5
6
7
8
9
10
11
12
13
14
15
16
17
18
19
20
21
22
23
24
25
26
27
28
29
30

Item 17 of 40
Question Id: 1152

Mark | Previous | Next | Full Screen | Tutorial | Lab Values | Notes | Calculator | Reverse Color | Text Zoom | Settings

Exhibit Display

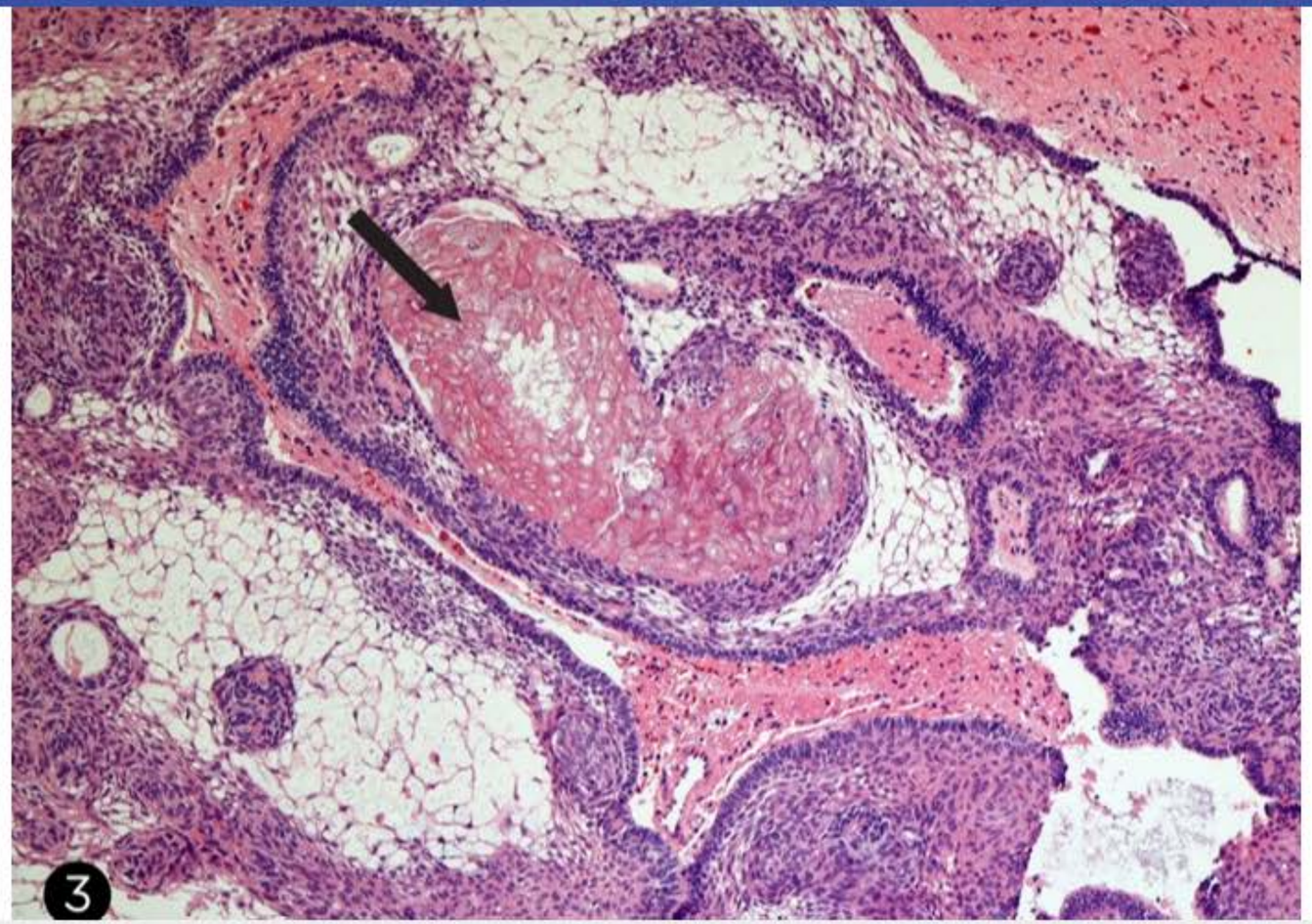

Zoom In | Zoom Out | Reset | Add To New Card | Existing Card

Block Time Remaining: 00:00:39
TUTOR

3 | Feedback | Suspend | End Block

Settings

1 2 3 4 5 6 7 8 9 10 11 12 13 14 15 16 17 18 19 20 21 22 23 24 25 26 27 28 29 30

Item 18 of 40
Question Id: 500

Mark | Previous | Next | Full Screen | Tutorial | Lab Values | Notes | Calculator | Reverse Color | Text Zoom | Settings

A 46-year-old woman comes to the emergency department due to sudden-onset, severe occipital headache and nausea. The patient has a history of hypertension and cigarette smoking. Physical examination shows mild disorientation but no focal weakness, sensory loss, or cranial nerve abnormalities. Noncontrast CT scan of the head reveals diffuse hyperdensity in the subarachnoid space. CT angiography reveals a ruptured anterior communicating artery aneurysm. The patient undergoes endovascular coiling of the aneurysm. Four days later, there is sudden deterioration in her level of consciousness and new, right-sided hemiparesis is observed. Repeat CT scan shows no significant changes. Which of the following is the most likely cause of this patient's neurological deterioration?

A. Arterial thrombosis
B. Embolism
C. Hydrocephalus
D. Rebleeding
E. Vascular inflammation
F. Vasospasm

Submit

Block Time Remaining: 00:00:40
TUTOR

2 | Feedback | Suspend | End Block

1 2 3 4 5 6 7 8 9 10 11 12 13 14 15 16 17 18 19 20 21 22 23 24 25 26 27 28 29 30

A 46-year-old woman comes to the emergency department due to sudden-onset, severe occipital headache and nausea. The patient has a history of hypertension and cigarette smoking. Physical examination shows mild disorientation but no focal weakness, sensory loss, or cranial nerve abnormalities. Noncontrast CT scan of the head reveals diffuse hyperdensity in the subarachnoid space. CT angiography reveals a ruptured anterior communicating artery aneurysm. The patient undergoes endovascular coiling of the aneurysm. Four days later, there is sudden deterioration in her level of consciousness and new, right-sided hemiparesis is observed. Repeat CT scan shows no significant changes. Which of the following is the most likely cause of this patient's neurological deterioration?

- A. Arterial thrombosis (8%)
- B. Embolism (8%)
- C. Hydrocephalus (1%)
- D. Rebleeding (11%)
- E. Vascular inflammation (6%)
- ✓ F. Vasospasm (64%)

Omitted
Correct answer
F

64%
Answered correctly

02 secs
Time Spent

04/05/2020
Last Updated

Explanation

Subarachnoid hemorrhage (SAH) is a life-threatening condition that most commonly results from rupture of a saccular (berry) aneurysm. It

Subarachnoid hemorrhage (SAH) is a life-threatening condition that most commonly results from rupture of a saccular (berry) aneurysm. It classically manifests with the abrupt onset of severe headache **(thunderclap headache)**; confusion, loss of consciousness, and meningismus may also occur. Noncontrast head CT scan reveals blood in the subarachnoid space (between the arachnoid and pia mater).

If the patient survives the initial SAH, a number of complications (eg, rebleeding, hydrocephalus, seizures) may occur in the following days to weeks. The most common is **arterial vasospasm**, which occurs due to the release of vasoconstrictive factors from damaged erythrocytes in the subarachnoid space and the inability of damaged vascular endothelial cells to produce vasodilators (eg, nitric oxide). The resultant unopposed vasoconstriction can cause **delayed cerebral ischemia**, which manifests as a change in mental status and/or new **focal neurological deficits** 3-12 days after the SAH.

CT scan usually reveals **no significant changes** despite the severity of the ischemia following vasospasm. Nimodipine, a selective calcium channel blocker, is used after SAH to promote vasodilation and prevent calcium-dependent excitotoxicity, which improves outcomes by reducing the incidence and extent of ischemia due to cerebral vasospasm.

(Choices A, B, and E) Although arterial thrombosis, embolism, and vascular inflammation could all cause a change in mental status and focal neurologic deficits, they are not significant complications of SAH.

(Choice C) Hydrocephalus may occur hours to days after SAH due to blood breakdown products obstructing the flow of cerebrospinal fluid or clogging the arachnoid villi. Patients develop signs of elevated intracranial pressure (eg, nausea/vomiting), and neuroimaging demonstrates ventricular dilation.

(Choice D) Rebleeding after initial SAH carries a high mortality rate and usually occurs early (<24 hours) after the initial bleed. Although symptoms can include a sudden change in level of consciousness and appearance of new neurological deficits, rebleeding is very rare 4 days after a successfully repaired aneurysmal rupture and CT scan would demonstrate newly extravasated blood.

Educational objective:
The most common complication of aneurysmal subarachnoid hemorrhage is vasospasm, which typically occurs 3-12 days after the initial insult and can cause delayed cerebral ischemia (eg, sudden change in mental status, new focal neurological deficits). The CT scan usually remains unchanged, unlike with rebleeding.

1 2 3 4 5 6 7 8 9 10 11 12 13 14 15 16 17 18 19 20 21 22 23 24 25 26 27 28 29 30

weeks. The most common is **arterial vasospasm**, which occurs due to the release of vasoconstrictive factors from damaged erythrocytes in the subarachnoid space and the inability of damaged vascular endothelial cells to produce vasodilators (eg, nitric oxide). The resultant unopposed vasoconstriction can cause **delayed cerebral ischemia**, which manifests as a change in mental status and/or new **focal neurological deficits** 3-12 days after the SAH.

CT scan usually reveals **no significant changes** despite the severity of the ischemia following vasospasm. Nimodipine, a selective calcium channel blocker, is used after SAH to promote vasodilation and prevent calcium-dependent excitotoxicity, which improves outcomes by reducing the incidence and extent of ischemia due to cerebral vasospasm.

(Choices A, B, and E) Although arterial thrombosis, embolism, and vascular inflammation could all cause a change in mental status and focal neurologic deficits, they are not significant complications of SAH.

(Choice C) Hydrocephalus may occur hours to days after SAH due to blood breakdown products obstructing the flow of cerebrospinal fluid or clogging the arachnoid villi. Patients develop signs of elevated intracranial pressure (eg, nausea/vomiting), and neuroimaging demonstrates ventricular dilation.

(Choice D) Rebleeding after initial SAH carries a high mortality rate and usually occurs early (<24 hours) after the initial bleed. Although symptoms can include a sudden change in level of consciousness and appearance of new neurological deficits, rebleeding is very rare 4 days after a successfully repaired aneurysmal rupture and CT scan would demonstrate newly extravasated blood.

Educational objective:
The most common complication of aneurysmal subarachnoid hemorrhage is vasospasm, which typically occurs 3-12 days after the initial insult and can cause delayed cerebral ischemia (eg, sudden change in mental status, new focal neurological deficits). The CT scan usually remains unchanged, unlike with rebleeding.

Pathology	Nervous System	Subarachnoid hemorrhage
Subject	System	Topic

Copyright © UWorld. All rights reserved.

Settings

1 2 3 4 5 6 7 8 9 10 11 12 13 14 15 16 17 18 19 20 21 22 23 24 25 26 27 28 29 30

Item 19 of 40
Question Id: 11627

Mark | Previous | Next | Full Screen | Tutorial | Lab Values | Notes | Calculator | Reverse Color | Text Zoom | Settings

A 45-year-old man is brought to the emergency department due to new-onset seizure. His family witnessed an episode of blank staring followed by a generalized tonic-clonic convulsion with tongue biting and urinary incontinence. The patient has a past medical history of seasonal asthma and takes no prescription medications. He does not use alcohol or illicit drugs. Vital signs and neurologic examination are normal. Noncontrast head CT and brain MRI are consistent with a diagnosis of cavernous hemangioma. This patient is at greatest risk of developing which of the following complications?

A. Epidural hematoma

B. Intracerebral hemorrhage

C. Ischemic stroke

D. Migraine headaches

E. Subarachnoid hemorrhage

F. Subdural hematoma

Submit

Block Time Remaining: 00:00:42
TUTOR

2 | Feedback | Suspend | End Block

1 2 3 4 5 6 7 8 9 10 11 12 13 14 15 16 17 18 19 20 21 22 23 24 25 26 27 28 29 30

A 45-year-old man is brought to the emergency department due to new-onset seizure. His family witnessed an episode of blank staring followed by a generalized tonic-clonic convulsion with tongue biting and urinary incontinence. The patient has a past medical history of seasonal asthma and takes no prescription medications. He does not use alcohol or illicit drugs. Vital signs and neurologic examination are normal. Noncontrast head CT and brain MRI are consistent with a diagnosis of cavernous hemangioma. This patient is at greatest risk of developing which of the following complications?

- A. Epidural hematoma (2%)
- ✓ B. Intracerebral hemorrhage (54%)
- C. Ischemic stroke (7%)
- D. Migraine headaches (4%)
- E. Subarachnoid hemorrhage (20%)
- F. Subdural hematoma (9%)

Omitted
Correct answer
B

54%
Answered correctly

01 sec
Time Spent

03/01/2020
Last Updated

Explanation

Cavernous hemangiomas are vascular malformations (sporadic or familial) that most commonly occur within the **brain parenchyma** above the cerebellar tentorium. They consist of clusters of dilated, thin-walled capillaries with little or no intervening nervous tissue. Patients with cavernous

1 2 3 4 5 6 7 8 9 10 11 12 13 14 15 16 17 18 19 20 21 22 23 24 25 26 27 28 29 30

Cavernous hemangiomas are vascular malformations (sporadic or familial) that most commonly occur within the **brain parenchyma** above the cerebellar tentorium. They consist of clusters of dilated, thin-walled capillaries with little or no intervening nervous tissue. Patients with cavernous hemangiomas often have **seizures** and may develop progressive neurologic deficits due to mass effect with interruption of the cerebral microcirculation. These lesions also have a **tendency to bleed**, which can contribute to neurologic symptoms (eg, due to subcortical/cortical tissue irritation) and appear as an irregular hyperdense/bright mass on head CT.

(Choice A) Epidural hematomas usually result from rupture of the middle meningeal artery in the setting of head trauma (eg, skull fracture at the pterion).

(Choice C) Cavernous hemangiomas increase the risk of hemorrhagic as opposed to ischemic stroke. Ischemic stroke typically occurs in older individuals with cardiovascular risk factors (eg, diabetes mellitus, hypertension, hyperlipidemia, smoking history) due to vessel occlusion caused by thrombosis or cardioembolism.

(Choice D) Migraine headache is a primary headache disorder commonly seen in young women. Although migraine headaches can have a secondary cause, they have not been linked specifically to cavernous hemangiomas.

(Choice E) Subarachnoid hemorrhage is usually caused by ruptured saccular aneurysms and is an infrequent consequence of bleeding vascular malformations.

(Choice F) Subdural hematoma results from rupture of the bridging veins in the subdural space (between the dura and arachnoid membranes) and is most commonly caused by head trauma. Vascular malformations do not typically result in subdural hematomas.

Educational objective:
Cavernous hemangiomas are vascular malformations that occur most commonly within the brain parenchyma; they carry an increased risk of intracerebral hemorrhage and seizure.

References

- CNS cavernous haemangioma: "popcorn" in the brain and spinal cord.
- Management of cerebral aneurysmal malformations: from diagnosis to treatment

Settings

1
2
3
4
5
6
7
8
9
10
11
12
13
14
15
16
17
18
19
20
21
22
23
24
25
26
27
28
29
30

Item 19 of 40
Question Id: 11627

Mark | Previous | Next | Full Screen | Tutorial | Lab Values | Notes | Calculator | Reverse Color | Text Zoom | Settings

Exhibit Display

Zoom In | Zoom Out | Reset | Add To New Card | Existing Card

Block Time Remaining: 00:00:42
TUTOR

2 | Feedback | Suspend | End Block

1 2 3 4 5 6 7 8 9 10 11 12 13 14 15 16 17 18 19 20 21 22 23 24 25 26 27 28 29 30

(Choice A) Epidural hematomas usually result from rupture of the middle meningeal artery in the setting of head trauma (eg, skull fracture at the pterion).

(Choice C) Cavernous hemangiomas increase the risk of hemorrhagic as opposed to ischemic stroke. Ischemic stroke typically occurs in older individuals with cardiovascular risk factors (eg, diabetes mellitus, hypertension, hyperlipidemia, smoking history) due to vessel occlusion caused by thrombosis or cardioembolism.

(Choice D) Migraine headache is a primary headache disorder commonly seen in young women. Although migraine headaches can have a secondary cause, they have not been linked specifically to cavernous hemangiomas.

(Choice E) Subarachnoid hemorrhage is usually caused by ruptured saccular aneurysms and is an infrequent consequence of bleeding vascular malformations.

(Choice F) Subdural hematoma results from rupture of the bridging veins in the subdural space (between the dura and arachnoid membranes) and is most commonly caused by head trauma. Vascular malformations do not typically result in subdural hematomas.

Educational objective:
Cavernous hemangiomas are vascular malformations that occur most commonly within the brain parenchyma; they carry an increased risk of intracerebral hemorrhage and seizure.

References

- CNS cavernous haemangioma: "popcorn" in the brain and spinal cord.
- Management of cerebral cavernous malformations: from diagnosis to treatment.

Pathology	Nervous System	Hemangioma
Subject	System	Topic

Copyright © UWorld. All rights reserved.

Settings

1 2 3 4 5 6 7 8 9 10 11 12 13 14 15 16 17 18 19 20 21 22 23 24 25 26 27 28 29 30

Item 20 of 40
Question Id: 468

Mark | Previous | Next | Full Screen | Tutorial | Lab Values | Notes | Calculator | Reverse Color | Text Zoom | Settings

Magnetic resonance imaging of the head of a young patient shows an angiomatous lesion involving the cerebellum. There is also a cystic mass in the right kidney on abdominal ultrasound. The differential diagnosis must include which of the following?

A. Neurofibromatosis type 1
B. Neurofibromatosis type 2
C. Sturge-Weber syndrome
D. Von Hippel-Lindau disease
E. Tuberous sclerosis
F. Hereditary hemorrhagic telangiectasia

Submit

Block Time Remaining: 00:00:42
TUTOR

3 | Feedback | Suspend | End Block

1 2 3 4 5 6 7 8 9 10 11 12 13 14 15 16 17 18 19 20 21 22 23 24 25 26 27 28 29 30

Magnetic resonance imaging of the head of a young patient shows an angiomatous lesion involving the cerebellum. There is also a cystic mass in the right kidney on abdominal ultrasound. The differential diagnosis must include which of the following?

A. Neurofibromatosis type 1 (2%)

B. Neurofibromatosis type 2 (3%)

C. Sturge-Weber syndrome (4%)

✓ D. Von Hippel-Lindau disease (71%)

E. Tuberous sclerosis (14%)

F. Hereditary hemorrhagic telangiectasia (3%)

Omitted
Correct answer
D

71%
Answered correctly

02 secs
Time Spent

04/06/2020
Last Updated

Explanation

Von Hippel-Lindau disease	
Etiology	• Mutation in the *VHL* tumor suppressor gene on chromosome 3 • Autosomal dominant inheritance
	• Cerebellar & retinal hemangioblastomas

Von Hippel-Lindau disease	
Etiology	• Mutation in the *VHL* tumor suppressor gene on chromosome 3 • Autosomal dominant inheritance
Manifestations	• Cerebellar & retinal hemangioblastomas • Pheochromocytoma • Renal cell carcinoma (clear cell subtype)

Management	• Surveillance for associated malignancies
	  ◦ Eye/retinal examination
	  ◦ Plasma or urine metanephrines
	  ◦ MRI of the brain & spine
	  ◦ MRI of the abdomen
	• Tumor resection

Von Hippel–Lindau disease is a rare, autosomal dominant condition characterized by the presence of **capillary hemangioblastomas** in the retina and/or cerebellum, as well as congenital cysts and/or neoplasms in the kidney, liver, and pancreas. Patients are also at increased risk for renal cell carcinoma, which can be bilateral.

(Choice A) Neurofibromatosis type 1 (von Recklinghausen's disease), is an autosomal dominant disorder characterized by neurofibromas, optic nerve gliomas, Lisch nodules (pigmented nodules of the iris), and café au lait spots (hyperpigmented cutaneous macules).

(Choice B) Neurofibromatosis type 2 is an autosomal dominant nervous system tumor syndrome, in which patients commonly develop bilateral cranial nerve VIII schwannomas and multiple meningiomas.

(Choice C) Sturge-Weber syndrome (encephalotrigeminal angiomatosis) is a rare congenital neurocutaneous disorder characterized by the presence of a cutaneous facial angioma (port wine stain) as well as leptomeningeal vascular malformations. This condition is associated with intellectual disability, seizures, hemiplegia, and "tram-track" calcifications on skull radiographs.

Von Hippel–Lindau disease is a rare, autosomal dominant condition characterized by the presence of **capillary hemangioblastomas** in the retina and/or cerebellum, as well as congenital cysts and/or neoplasms in the kidney, liver, and pancreas. Patients are also at increased risk for renal cell carcinoma, which can be bilateral.

(Choice A) Neurofibromatosis type 1 (von Recklinghausen's disease), is an autosomal dominant disorder characterized by neurofibromas, optic nerve gliomas, Lisch nodules (pigmented nodules of the iris), and café au lait spots (hyperpigmented cutaneous macules).

(Choice B) Neurofibromatosis type 2 is an autosomal dominant nervous system tumor syndrome, in which patients commonly develop bilateral cranial nerve VIII schwannomas and multiple meningiomas.

(Choice C) Sturge-Weber syndrome (encephalotrigeminal angiomatosis) is a rare congenital neurocutaneous disorder characterized by the presence of a cutaneous facial angioma (port wine stain) as well as leptomeningeal vascular malformations. This condition is associated with intellectual disability, seizures, hemiplegia, and "tram-track" calcifications on skull radiographs.

(Choice E) Although tuberous sclerosis may cause kidney, liver, and pancreatic cysts, central nervous system involvement manifests not as *angiomatous* lesions, but as cortical and subependymal *hamartomas*. Renal angiomyolipomas and cardiac rhabdomyomas are also characteristic. Clinically, seizures are a major complication.

(Choice F) Hereditary hemorrhagic telangiectasia (Osler-Weber-Rendu syndrome) is an autosomal dominant condition presenting with congenital telangiectasias. Rupture of these telangiectasias may cause epistaxis, gastrointestinal bleeding, or hematuria. Cysts are not characteristic.

Educational objective:
A cerebellar hemangioblastoma in association with congenital cysts of the kidneys, liver, and/or pancreas is highly suggestive of von Hippel–Lindau disease, a rare autosomal dominant condition.

Pathology	Nervous System	Von hippel lindau disease
Subject	System	Topic

Copyright © UWorld. All rights reserved.

Settings

1 2 3 4 5 6 7 8 9 10 11 12 13 14 15 16 17 18 19 20 21 22 23 24 25 26 27 28 29 30

Item 21 of 40
Question Id: 19214

Mark | Previous | Next | Full Screen | Tutorial | Lab Values | Notes | Calculator | Reverse Color | Text Zoom | Settings

A 55-year-old man comes to the clinic due to gradual, progressive weakness of the right upper extremity over the past 6 months. Over the last month, he has also noticed weakness in the left upper extremity. Vital signs are normal. Physical examination shows fasciculations and atrophy of the intrinsic muscles of the right hand and the muscles of the forearm. Reflexes are brisk in the upper extremities, and the plantar responses are extensor. Mild gait ataxia is present. Over the course of his illness, this patient will most likely develop which of the following?

A. Decreased left ventricular compliance

B. Decreased lung vital capacity

C. Degeneration of the cardiac conduction system

D. Inability to feel sensations below the neck

E. Refractory generalized tonic-clonic seizures

Submit

Block Time Remaining: 00:00:44
TUTOR

0 | Feedback | Suspend | End Block

1 2 3 4 5 6 7 8 9 10 11 12 13 14 15 16 17 18 19 20 21 22 23 24 25 26 27 28 29 30

A 55-year-old man comes to the clinic due to gradual, progressive weakness of the right upper extremity over the past 6 months. Over the last month, he has also noticed weakness in the left upper extremity. Vital signs are normal. Physical examination shows fasciculations and atrophy of the intrinsic muscles of the right hand and the muscles of the forearm. Reflexes are brisk in the upper extremities, and the plantar responses are extensor. Mild gait ataxia is present. Over the course of his illness, this patient will most likely develop which of the following?

A. Decreased left ventricular compliance (3%)

✓ B. Decreased lung vital capacity (74%)

C. Degeneration of the cardiac conduction system (4%)

D. Inability to feel sensations below the neck (12%)

E. Refractory generalized tonic-clonic seizures (4%)

Omitted
Correct answer
B

74%
Answered correctly

01 sec
Time Spent

05/14/2020
Last Updated

Explanation

This patient has progressive weakness with signs of **upper motor neuron** (UMN) dysfunction (eg, brisk reflexes, extensor plantar reflex) and **lower motor neuron** (LMN) dysfunction (eg, fasciculations, muscle atrophy), which is characteristic of **amyotrophic lateral sclerosis** (ALS), a terminal neurodegenerative disease.

Patients with ALS most often die of **respiratory failure**, which is caused by multiple factors:

1 2 3 4 5 6 7 8 9 10 11 12 13 14 15 16 17 18 19 20 21 22 23 24 25 26 27 28 29 30

This patient has progressive weakness with signs of **upper motor neuron** (UMN) dysfunction (eg, brisk reflexes, extensor plantar reflex) and **lower motor neuron** (LMN) dysfunction (eg, fasciculations, muscle atrophy), which is characteristic of **amyotrophic lateral sclerosis** (ALS), a terminal neurodegenerative disease.

Patients with ALS most often die of **respiratory failure**, which is caused by multiple factors:

- Inspiratory muscle (eg, diaphragm) atrophy and weakness, which leads to poor inspiratory strength. This is evident on pulmonary function testing as **decreased vital capacity** (the maximum volume displaced from the lung), which is followed as a **marker of disease progression** in patients with ALS.
- Expiratory muscle weakness, which leads to an **ineffective cough** and poor airway clearance.
- Bulbar muscle weakness, which leads to dysphagia and **chronic aspiration**.

Treatment of ALS often focuses on improving respiratory function, which both prolongs survival and improves quality of life.

(Choice A) Friedreich ataxia also presents with gait abnormalities and limb weakness. Death is typically due to cardiac dysfunction, due to either abnormalities of the cardiac conduction system or cardiac muscle defects (eg, decreased left ventricular compliance). However, Friedreich ataxia occurs in children age 5-15 years.

(Choice C) Disseminated Lyme disease can present with radiculopathy; the classic triad of neurologic Lyme is meningitis, cranial neuropathy, and radiculoneuropathy (sensory or motor). Carditis can also occur, which can result in degeneration of the cardiac conduction system. However, this patient's combination of UMN and LMN signs is much more likely to be ALS.

(Choice D) ALS is a disease that primarily affects motor neurons (both upper and lower). Although sensory disturbances can be present in some patients, widespread sensory defects do not occur.

(Choice E) Tuberous sclerosis is an autosomal dominant disorder that results in tumors in multiple organ systems. Generalized tonic-clonic seizures often occur and become refractory as the disease progresses. This patient has no evidence of tumors or seizures nor a positive family history to suggest tuberous sclerosis.

Treatment of ALS often focuses on improving respiratory function, which both prolongs survival and improves quality of life.

(Choice A) Friedreich ataxia also presents with gait abnormalities and limb weakness. Death is typically due to cardiac dysfunction, due to either abnormalities of the cardiac conduction system or cardiac muscle defects (eg, decreased left ventricular compliance). However, Friedreich ataxia occurs in children age 5-15 years.

(Choice C) Disseminated Lyme disease can present with radiculopathy; the classic triad of neurologic Lyme is meningitis, cranial neuropathy, and radiculoneuropathy (sensory or motor). Carditis can also occur, which can result in degeneration of the cardiac conduction system. However, this patient's combination of UMN and LMN signs is much more likely to be ALS.

(Choice D) ALS is a disease that primarily affects motor neurons (both upper and lower). Although sensory disturbances can be present in some patients, widespread sensory defects do not occur.

(Choice E) Tuberous sclerosis is an autosomal dominant disorder that results in tumors in multiple organ systems. Generalized tonic-clonic seizures often occur and become refractory as the disease progresses. This patient has no evidence of tumors or seizures nor a positive family history to suggest tuberous sclerosis.

Educational objective:
Patients with amyotrophic lateral sclerosis often develop respiratory failure due to inspiratory muscle weakness (causing decreased vital capacity), expiratory muscle weakness (causing a weak cough), and bulbar dysfunction (causing dysphagia and chronic aspiration).

References

- Association between decline in slow vital capacity and respiratory insufficiency, use of assisted ventilation, tracheostomy, or death in patients with amyotrophic lateral sclerosis.

Pathology	Nervous System	Amyotrophic lateral sclerosis
Subject	System	Topic

Copyright © UWorld. All rights reserved.

Settings

1 2 3 4 5 6 7 8 9 10 11 12 13 14 15 16 17 18 19 20 21 22 23 24 25 26 27 28 29 30

Item 22 of 40
Question Id: 17

Mark | Previous | Next | Full Screen | Tutorial | Lab Values | Notes | Calculator | Reverse Color | Text Zoom | Settings

A 65-year-old woman is evaluated for worsening urinary urgency and incontinence. The patient has had no abdominal pain, dysuria, or changes in urinary frequency. On several occasions, she has urinated involuntarily, which she attributes to an inability to walk quickly to the bathroom. The patient feels unsteady while ambulating and walks slowly with small steps. Her family also reports that she has become forgetful and has difficulty planning and executing various activities that she used to perform regularly. Medical history is notable for hypertension. The patient does not use tobacco, alcohol, or illicit drugs. Vital signs are within normal limits. Cardiopulmonary, abdominal, and genitourinary examinations show no abnormalities. Neurological examination shows impaired attention and short-term memory. MRI of the brain reveals chronic white matter changes with no infarction, hemorrhage, or mass lesions. There is diffuse ventriculomegaly with no sulcal enlargement. Which of the following is the most likely underlying cause of this patient's urinary incontinence?

- A. Cerebellar dysfunction
- B. Compression of the reticular formation
- C. Impaired basal ganglia signaling
- D. Spinal cord damage
- E. Stretching of descending cortical fibers

Submit

Block Time Remaining: 00:00:45
TUTOR

1 | Feedback | Suspend | End Block

1 2 3 4 5 6 7 8 9 10 11 12 13 14 15 16 17 18 19 20 21 22 23 24 25 26 27 28 29 30

A 65-year-old woman is evaluated for worsening urinary urgency and incontinence. The patient has had no abdominal pain, dysuria, or changes in urinary frequency. On several occasions, she has urinated involuntarily, which she attributes to an inability to walk quickly to the bathroom. The patient feels unsteady while ambulating and walks slowly with small steps. Her family also reports that she has become forgetful and has difficulty planning and executing various activities that she used to perform regularly. Medical history is notable for hypertension. The patient does not use tobacco, alcohol, or illicit drugs. Vital signs are within normal limits. Cardiopulmonary, abdominal, and genitourinary examinations show no abnormalities. Neurological examination shows impaired attention and short-term memory. MRI of the brain reveals chronic white matter changes with no infarction, hemorrhage, or mass lesions. There is diffuse ventriculomegaly with no sulcal enlargement. Which of the following is the most likely underlying cause of this patient's urinary incontinence?

A. Cerebellar dysfunction (4%)

B. Compression of the reticular formation (14%)

C. Impaired basal ganglia signaling (15%)

D. Spinal cord damage (4%)

✓ E. Stretching of descending cortical fibers (59%)

Omitted
Correct answer
E

59%
Answered correctly

01 sec
Time Spent

03/23/2020
Last Updated

Explanation

1 2 3 4 5 6 7 8 9 10 11 12 13 14 15 16 17 18 19 20 21 22 23 24 25 26 27 28 29 30

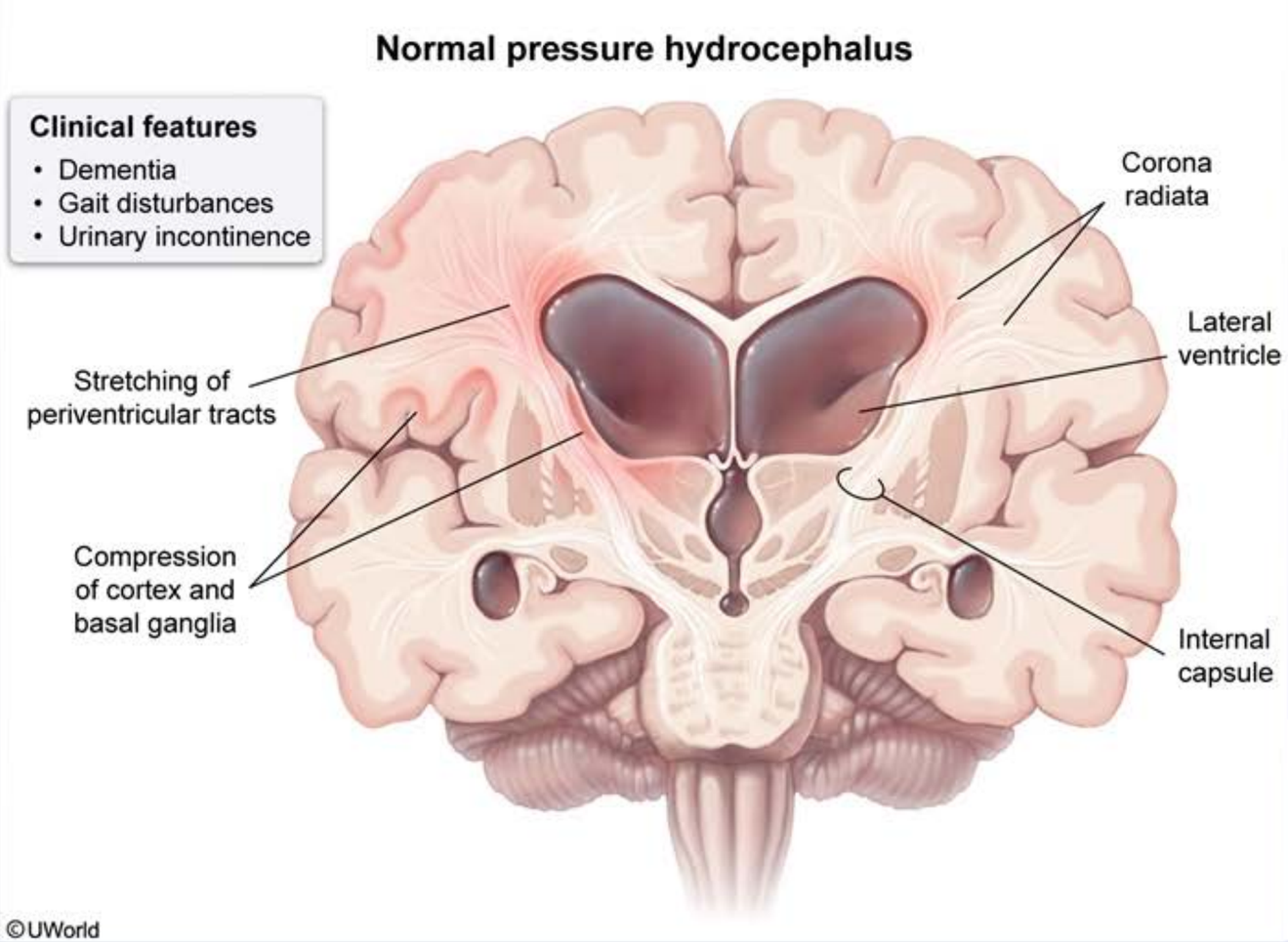

This patient with impaired memory and cognition, unsteady gait, and urinary incontinence has ventriculomegaly without sulcal enlargement on MRI, which is characteristic of **normal pressure hydrocephalus (NPH)**. NPH can occur due to decreased absorption of cerebrospinal fluid (CSF)

1 2 3 4 5 6 7 8 9 10 11 12 13 14 15 16 17 18 19 20 21 22 23 24 25 26 27 28 29 30

This patient with impaired memory and cognition, unsteady gait, and urinary incontinence has ventriculomegaly without sulcal enlargement on MRI, which is characteristic of **normal pressure hydrocephalus (NPH)**. NPH can occur due to decreased absorption of cerebrospinal fluid (CSF) by the arachnoid granulations (eg, fibrosis from previous cerebral inflammation or bleeding) with gradual accumulation of CSF in the ventricular system. The lateral ventricles expand, resulting in normal intracranial pressure and **stretching the descending cortical fibers** (corona radiata). Interruption of these pathways, along with impairment of cortical and subcortical function, leads to the classic triad of NPH symptoms (**dementia**, **gait disturbance**, **urinary incontinence**).

The cerebral cortex (through the pontine micturition center) regulates the micturition reflex, which is an autonomic spinal reflex mediated by the neurons in the sacral spinal cord. In NPH, the **lack of cortical inhibition** results in **detrusor muscle hyperactivity**. This leads to urinary urgency, which can be worsened by gait abnormalities that limit a patient's ability to quickly get to a bathroom (**urge incontinence**). Progressive frontal lobe impairment leads to the inability to recognize urinary urge, uncontrolled urination, and a lack of concern as the disease progresses.

(Choice A) Cerebellar dysfunction can cause an ataxic gait, dysarthria, and intention tremors. Memory dysfunction and urinary incontinence are more indicative of cerebral impairment. NPH typically spares cerebellar function.

(Choice B) Compression of the reticular formation can occur with brainstem herniation, leading to loss of consciousness and coma.

(Choice C) Impaired basal ganglia signaling is characteristic of Parkinson disease, which can result in ataxia with a slow gait. However, cogwheel rigidity and resting tremor would be prominent and dementia and urinary incontinence would not be expected until later in the disease course.

(Choice D) Spinal cord damage is a common cause of incontinence with gait impairment. However, spinal cord injury also frequently causes lower extremity weakness and is not associated with cognitive impairment.

Educational objective:
Normal pressure hydrocephalus occurs due to decreased cerebrospinal fluid absorption, resulting in ventriculomegaly with normal intracranial pressure. This causes stretching of the descending cortical fibers (corona radiata) from the frontal lobe and contributes to the classic triad of symptoms (ie, dementia, gait abnormalities, urinary incontinence). Loss of cortical inhibition of the sacral micturition center leads to urge incontinence.

Settings

1 2 3 4 5 6 7 8 9 10 11 12 13 14 15 16 17 18 19 20 21 22 23 24 25 26 27 28 29 30

Item 22 of 40
Question Id: 17

Mark | Previous | Next | Full Screen | Tutorial | Lab Values | Notes | Calculator | Reverse Color | Text Zoom | Settings

©UWorld

Exhibit Display

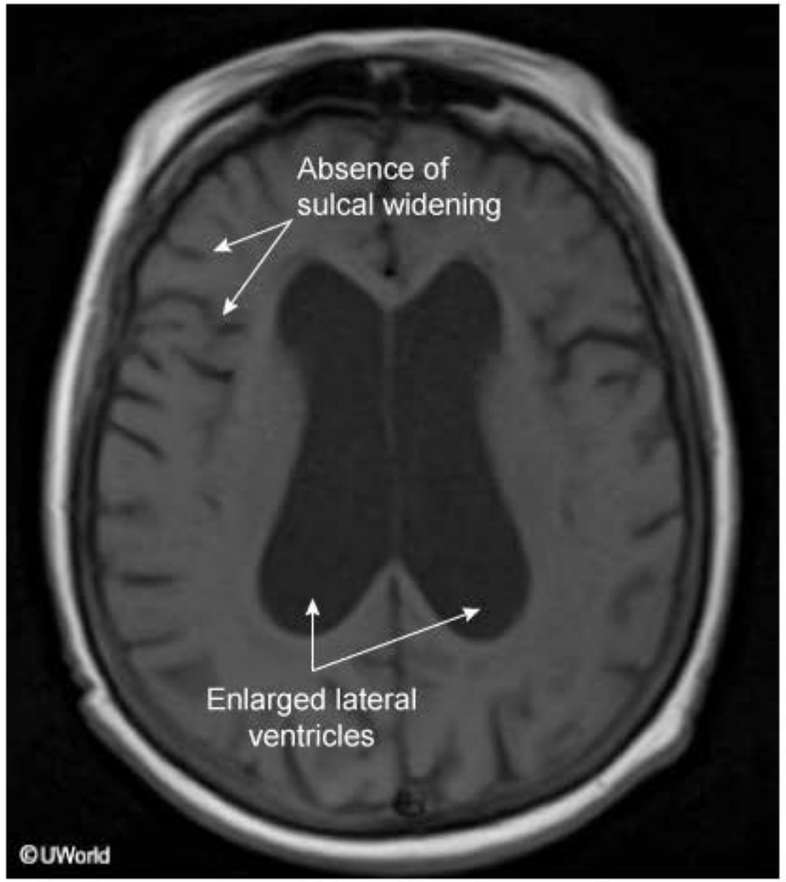

Zoom In | Zoom Out | Reset | Add To New Card | Existing Card

symptoms (ie, dementia, gait abnormalities, urinary incontinence). Loss of cortical inhibition of the sacral micturition center leads to urge

Block Time Remaining: 00:00:46
TUTOR

1 | Feedback | Suspend | End Block

Settings

1 2 3 4 5 6 7 8 9 10 11 12 13 14 15 16 17 18 19 20 21 22 23 24 25 26 27 28 29 30

Item 22 of 40
Question Id: 17

Mark | Previous | Next | Full Screen | Tutorial | Lab Values | Notes | Calculator | Reverse Color | Text Zoom | Settings

©UWorld

Exhibit Display

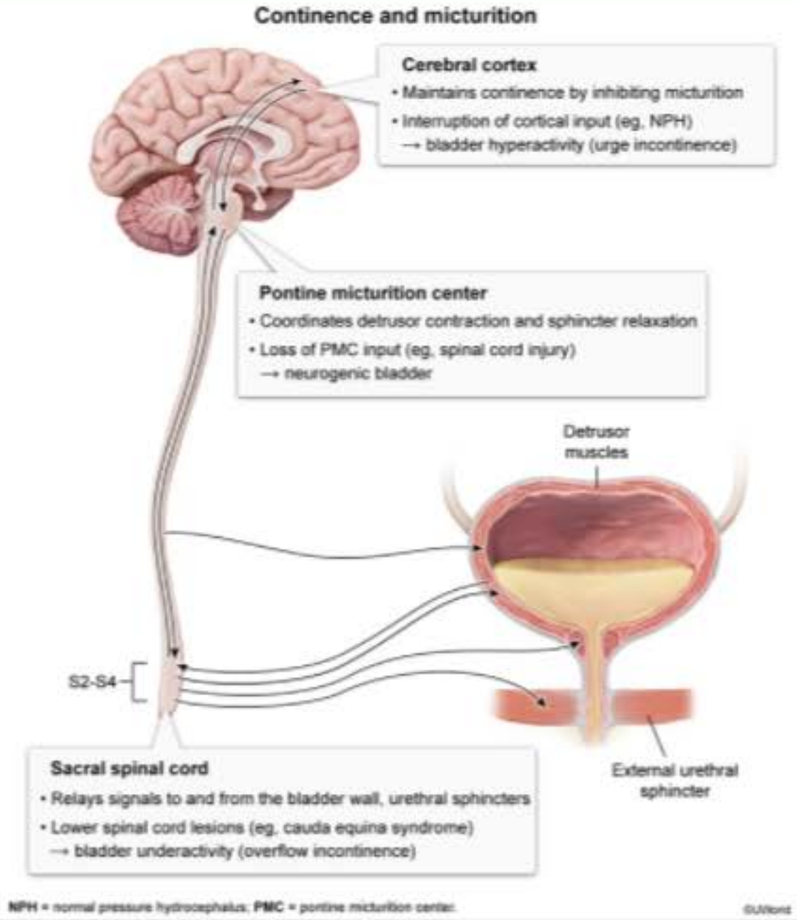

Zoom In | Zoom Out | Reset | Add To New Card | Existing Card

symptoms (ie, dementia, gait abnormalities, urinary incontinence). Loss of cortical inhibition of the sacral micturition center leads to urge

Block Time Remaining: 00:00:46
TUTOR

Feedback | Suspend | End Block

1, 2, 3, 4, 5, 6, 7, 8, 9, 10, 11, 12, 13, 14, 15, 16, 17, 18, 19, 20, 21, 22, 23, 24, 25, 26, 27, 28, 29, 30

gait disturbance, **urinary incontinence**).

The cerebral cortex (through the pontine micturition center) regulates the micturition reflex, which is an autonomic spinal reflex mediated by the neurons in the sacral spinal cord. In NPH, the **lack of cortical inhibition** results in **detrusor muscle hyperactivity**. This leads to urinary urgency, which can be worsened by gait abnormalities that limit a patient's ability to quickly get to a bathroom (**urge incontinence**). Progressive frontal lobe impairment leads to the inability to recognize urinary urge, uncontrolled urination, and a lack of concern as the disease progresses.

(Choice A) Cerebellar dysfunction can cause an ataxic gait, dysarthria, and intention tremors. Memory dysfunction and urinary incontinence are more indicative of cerebral impairment. NPH typically spares cerebellar function.

(Choice B) Compression of the reticular formation can occur with brainstem herniation, leading to loss of consciousness and coma.

(Choice C) Impaired basal ganglia signaling is characteristic of Parkinson disease, which can result in ataxia with a slow gait. However, cogwheel rigidity and resting tremor would be prominent and dementia and urinary incontinence would not be expected until later in the disease course.

(Choice D) Spinal cord damage is a common cause of incontinence with gait impairment. However, spinal cord injury also frequently causes lower extremity weakness and is not associated with cognitive impairment.

Educational objective:
Normal pressure hydrocephalus occurs due to decreased cerebrospinal fluid absorption, resulting in ventriculomegaly with normal intracranial pressure. This causes stretching of the descending cortical fibers (corona radiata) from the frontal lobe and contributes to the classic triad of symptoms (ie, dementia, gait abnormalities, urinary incontinence). Loss of cortical inhibition of the sacral micturition center leads to urge incontinence.

Pathology	Nervous System	Normal pressure hydrocephalus
Subject	System	Topic

Copyright © UWorld. All rights reserved.

Settings

1 2 3 4 5 6 7 8 9 10 11 12 13 14 15 16 17 18 19 20 21 22 23 24 25 26 27 28 29 30

Item 23 of 40
Question Id: 647

Mark | Previous | Next | Full Screen | Tutorial | Lab Values | Notes | Calculator | Reverse Color | Text Zoom | Settings

A 65-year-old man with a long history of smoking comes to the office due to a nonproductive cough over the last several months. He recently developed left shoulder pain, persistent hiccups, and dyspnea. His temperature is 36.7 C (98 F), blood pressure is 140/85 mm Hg, and pulse is 76/min. Physical examination reveals decreased breath sounds on the left side. Chest x-ray shows a large left lung mass. Compression of a nerve arising from which of the following locations is most likely causing this patient's recent symptoms?

- A. Brainstem
- B. C1-C3
- C. C3-C5
- D. C5-C8
- E. T1-T2

Submit

Block Time Remaining: 00:00:46
TUTOR

2 | Feedback | Suspend | End Block

1 2 3 4 5 6 7 8 9 10 11 12 13 14 15 16 17 18 19 20 21 22 23 24 25 26 27 28 29 30

A 65-year-old man with a long history of smoking comes to the office due to a nonproductive cough over the last several months. He recently developed left shoulder pain, persistent hiccups, and dyspnea. His temperature is 36.7 C (98 F), blood pressure is 140/85 mm Hg, and pulse is 76/min. Physical examination reveals decreased breath sounds on the left side. Chest x-ray shows a large left lung mass. Compression of a nerve arising from which of the following locations is most likely causing this patient's recent symptoms?

- A. Brainstem (4%)
- B. C1-C3 (3%)
- ✓ C. C3-C5 (76%)
- D. C5-C8 (10%)
- E. T1-T2 (4%)

Omitted
Correct answer
C

76%
Answered correctly

01 sec
Time Spent

04/04/2020
Last Updated

Explanation

Lung cancers are prone to early local and distant spread. Intrathoracic expansion of a tumor can cause a number of distinctive syndromes, including **phrenic nerve** irritation and palsy.

The phrenic nerve arises from the **C3-C5** cervical segments and descends through the neck and thorax to innervate the ipsilateral hemidiaphragm. Phrenic nerve **irritation** can cause dyspnea, hiccups (diaphragmatic irritation), and **referred pain to the shoulder** (area

1 2 3 4 5 6 7 8 9 10 11 12 13 14 15 16 17 18 19 20 21 22 23 24 25 26 27 28 29 30

Lung cancers are prone to early local and distant spread. Intrathoracic expansion of a tumor can cause a number of distinctive syndromes, including **phrenic nerve** irritation and palsy.

The phrenic nerve arises from the **C3-C5** cervical segments and descends through the neck and thorax to innervate the ipsilateral hemidiaphragm. Phrenic nerve **irritation** can cause dyspnea, hiccups (diaphragmatic irritation), and **referred pain to the shoulder** (area innervated by supraclavicular nerve originating from C3 and C4). Phrenic nerve **palsy** is associated with respiratory distress and diminished breath sounds on the affected side, with elevation of the affected hemidiaphragm on chest x-ray. Upward movement of the affected hemidiaphragm with inspiration is seen on fluoroscopy.

Other syndromes that may occur due to local spread of a lung tumor include:

- **Horner syndrome** (ipsilateral miosis, ptosis, and anhydrosis) occurs in association with tumors of the lung apex (**Pancoast tumor**) that disrupt the oculosympathetic nerve pathway. Lung cancer in this location can also invade the rami of the **brachial plexus** (C5-T1) and cause shoulder pain **(Choices D and E).**
- A centrally located tumor or mediastinal spread of a more distant tumor can cause **superior vena cava (SVC) syndrome**, which is commonly associated with small cell lung carcinoma. SVC syndrome causes headache, facial and upper-extremity edema, and dilated veins of the upper torso.
- Involvement of the recurrent laryngeal nerve may cause hoarseness.
- Dysphagia may result if the tumor compresses the esophagus.

(Choice A) The brainstem, which is the site of origin of most cranial nerves, contains the respiratory center (in the medulla oblongata) and is traversed by spinal tracts. Brainstem strokes typically present with vertigo and, in extreme cases, can lead to locked-in syndrome (spastic quadriplegia and paralysis of most cranial nerves with preserved consciousness).

(Choice B) C1 is unique among the spinal nerves in that it carries only motor fibers. C1-C3 lesions could affect neck musculature but would not explain this patient's hiccups or dyspnea.

Educational objective:
The phrenic nerve arises from the C3-C5 segments of the spinal cord and innervates the ipsilateral hemidiaphragm. Intrathoracic spread of lung

hemidiaphragm with inspiration is seen on fluoroscopy.

Other syndromes that may occur due to local spread of a lung tumor include:

- **Horner syndrome** (ipsilateral miosis, ptosis, and anhydrosis) occurs in association with tumors of the lung apex (**Pancoast tumor**) that disrupt the oculosympathetic nerve pathway. Lung cancer in this location can also invade the rami of the **brachial plexus** (C5-T1) and cause shoulder pain **(Choices D and E).**
- A centrally located tumor or mediastinal spread of a more distant tumor can cause **superior vena cava (SVC) syndrome**, which is commonly associated with small cell lung carcinoma. SVC syndrome causes headache, facial and upper-extremity edema, and dilated veins of the upper torso.
- Involvement of the recurrent laryngeal nerve may cause hoarseness.
- Dysphagia may result if the tumor compresses the esophagus.

(Choice A) The brainstem, which is the site of origin of most cranial nerves, contains the respiratory center (in the medulla oblongata) and is traversed by spinal tracts. Brainstem strokes typically present with vertigo and, in extreme cases, can lead to locked-in syndrome (spastic quadriplegia and paralysis of most cranial nerves with preserved consciousness).

(Choice B) C1 is unique among the spinal nerves in that it carries only motor fibers. C1-C3 lesions could affect neck musculature but would not explain this patient's hiccups or dyspnea.

Educational objective:
The phrenic nerve arises from the C3-C5 segments of the spinal cord and innervates the ipsilateral hemidiaphragm. Intrathoracic spread of lung cancer may affect the phrenic nerve, causing hiccups and diaphragmatic paralysis with dyspnea. Brachial plexus involvement can cause pain in the distribution of the C8, T1, and T2 nerve roots. Involvement of the recurrent laryngeal nerve may cause hoarseness.

Pathology	Nervous System	Lung cancer
Subject	System	Topic

Copyright © UWorld. All rights reserved.

Settings

1 2 3 4 5 6 7 8 9 10 11 12 13 14 15 16 17 18 19 20 21 22 23 24 25 26 27 28 29 30

Item 24 of 40
Question Id: 19218

Mark | Previous | Next | Full Screen | Tutorial | Lab Values | Notes | Calculator | Reverse Color | Text Zoom | Settings

A 65-year-old man is found dead at his home due to a suspected suicide. The family reports that the patient has been having difficulty swallowing, dyspnea on exertion, and arm and leg weakness for the past several months and had undergone a medical workup. They suspect the physician may have given bad news and the patient ended his life so he would not have to live with the diagnosed condition. External examination shows atrophy of the muscles of the right lower and left upper extremities. Autopsy would most likely reveal which of the following additional findings?

A. Degeneration of dorsal spinal roots

B. Diaphragmatic atrophy

C. Diffuse brain atrophy

D. Inflammatory infiltrates in skeletal muscles

E. Plaques and gliosis in periventricular white matter

Submit

Block Time Remaining: 00:00:47
TUTOR

0 | Feedback | Suspend | End Block

1 2 3 4 5 6 7 8 9 10 11 12 13 14 15 16 17 18 19 20 21 22 23 24 25 26 27 28 29 30

A 65-year-old man is found dead at his home due to a suspected suicide. The family reports that the patient has been having difficulty swallowing, dyspnea on exertion, and arm and leg weakness for the past several months and had undergone a medical workup. They suspect the physician may have given bad news and the patient ended his life so he would not have to live with the diagnosed condition. External examination shows atrophy of the muscles of the right lower and left upper extremities. Autopsy would most likely reveal which of the following additional findings?

- A. Degeneration of dorsal spinal roots (17%)
- ✓ B. Diaphragmatic atrophy (49%)
- C. Diffuse brain atrophy (6%)
- D. Inflammatory infiltrates in skeletal muscles (6%)
- E. Plaques and gliosis in periventricular white matter (20%)

Omitted
Correct answer
B

49%
Answered correctly

01 sec
Time Spent

05/09/2020
Last Updated

Explanation

Amyotrophic lateral sclerosis	
Criteria	**Description**
Macroscopic	• Thin anterior roots

1 2 3 4 5 6 7 8 9 10 11 12 13 14 15 16 17 18 19 20 21 22 23 24 25 26 27 28 29 30

Amyotrophic lateral sclerosis	
Criteria	**Description**
Macroscopic	• Thin anterior roots • Mild atrophy of the precentral gyrus (primary motor cortex)
Microscopic	• Loss of neurons in the anterior horn (LMN lesion) • Degeneration & atrophy of the lateral corticospinal tracts (UMN lesion) • Loss of neurons in the motor nuclei of CNs V, IX, X & XII • Muscle: denervation atrophy (small, angular fibers)
Clinical	• LMN symptoms: muscle atrophy & fasciculation • UMN symptoms: spasticity, hyperreflexia & pathologic reflexes
Genetic	• Mutation of copper-zinc superoxide dismutase (SOD1) gene may be implicated
Treatment	• Riluzole (mechanism of action: decreased glutamate release)

LMN = lower motor neuron; **UMN** = upper motor neuron.

This patient with a history of bulbar symptoms (eg, difficulty swallowing) and limb weakness has postmortem evidence of asymmetric muscular atrophy. This presentation is concerning for **amyotrophic lateral sclerosis** (ALS), a progressive, fatal neurodegenerative disease of both upper motor neurons (UMNs) and lower motor neurons (LMNs).

ALS has the highest incidence in patients age 60-75. The most common initial presentation includes **asymmetric weakness** of the extremities; bulbar symptoms are also common and can include dysphagia and dysarthria. Because any upper or lower motor neuron can be affected, the initial presentation may vary widely. UMN degeneration leads to spasticity and hyperreflexia; **LMN degeneration** leads to denervation **atrophy of**

LMN = lower motor neuron; UMN = upper motor neuron.

This patient with a history of bulbar symptoms (eg, difficulty swallowing) and limb weakness has postmortem evidence of asymmetric muscular atrophy. This presentation is concerning for **amyotrophic lateral sclerosis** (ALS), a progressive, fatal neurodegenerative disease of both upper motor neurons (UMNs) and lower motor neurons (LMNs).

ALS has the highest incidence in patients age 60-75. The most common initial presentation includes **asymmetric weakness** of the extremities; bulbar symptoms are also common and can include dysphagia and dysarthria. Because any upper or lower motor neuron can be affected, the initial presentation may vary widely. UMN degeneration leads to spasticity and hyperreflexia; **LMN degeneration** leads to denervation **atrophy of skeletal muscles**.

The most concerning site of LMN degeneration involves the **diaphragm** because it results in **dyspnea**, as reported by this patient, and eventual **respiratory failure**. Diaphragmatic function can be monitored with imaging studies (eg, ultrasound) and via testing of respiratory muscle strength (eg, sniff tests); postmortem studies typically demonstrate striking **diaphragmatic atrophy**.

(Choice A) Degeneration of dorsal spinal roots would lead to sensory dysfunction, not motor dysfunction, as seen in this patient. Sensory dysfunction is not a classic feature of ALS.

(Choice C) Because ALS results primarily in neurodegeneration of motor neurons, atrophy is seen predominately in the motor cortex rather than diffusely throughout the brain.

(Choice D) Inflammatory infiltrates in skeletal muscles are seen in inflammatory myopathies, including dermatomyositis and polymyositis. Long-standing disease can lead to muscle atrophy; however, ALS causes muscle atrophy due to denervation rather than inflammation.

(Choice E) Plaques and gliosis in periventricular white matter are characteristic pathologic findings of multiple sclerosis. These inflammatory demyelinating lesions occur in the CNS; therefore, weakness is often associated with spasticity (UMN sign) rather than atrophy (LMN sign). In addition, it typically occurs in younger women (age <55).

Educational objective:
Amyotrophic lateral sclerosis causes degeneration of both upper and lower motor neurons and can result in bulbar and skeletal muscle weakness. Denervation atrophy can affect the diaphragm and contribute to respiratory failure.

bulbar symptoms are also common and can include dysphagia and dysarthria. Because any upper or lower motor neuron can be affected, the initial presentation may vary widely. UMN degeneration leads to spasticity and hyperreflexia; **LMN degeneration** leads to denervation **atrophy of skeletal muscles**.

The most concerning site of LMN degeneration involves the **diaphragm** because it results in **dyspnea**, as reported by this patient, and eventual **respiratory failure**. Diaphragmatic function can be monitored with imaging studies (eg, ultrasound) and via testing of respiratory muscle strength (eg, sniff tests); postmortem studies typically demonstrate striking **diaphragmatic atrophy**.

(Choice A) Degeneration of dorsal spinal roots would lead to sensory dysfunction, not motor dysfunction, as seen in this patient. Sensory dysfunction is not a classic feature of ALS.

(Choice C) Because ALS results primarily in neurodegeneration of motor neurons, atrophy is seen predominately in the motor cortex rather than diffusely throughout the brain.

(Choice D) Inflammatory infiltrates in skeletal muscles are seen in inflammatory myopathies, including dermatomyositis and polymyositis. Long-standing disease can lead to muscle atrophy; however, ALS causes muscle atrophy due to denervation rather than inflammation.

(Choice E) Plaques and gliosis in periventricular white matter are characteristic pathologic findings of multiple sclerosis. These inflammatory demyelinating lesions occur in the CNS; therefore, weakness is often associated with spasticity (UMN sign) rather than atrophy (LMN sign). In addition, it typically occurs in younger women (age <55).

Educational objective:
Amyotrophic lateral sclerosis causes degeneration of both upper and lower motor neurons and can result in bulbar and skeletal muscle weakness. Denervation atrophy can affect the diaphragm and contribute to respiratory failure.

Pathology	Nervous System	Amyotrophic lateral sclerosis
Subject	System	Topic

Copyright © UWorld. All rights reserved.

Settings

1 2 3 4 5 6 7 8 9 10 11 12 13 14 15 16 17 18 19 20 21 22 23 24 25 26 27 28 29 30

Item 25 of 40
Question Id: 7492

Mark | Previous | Next | Full Screen | Tutorial | Lab Values | Notes | Calculator | Reverse Color | Text Zoom | Settings

A 27-year-old woman comes to the office due to almost daily headaches for the past 3 months. The patient describes constant "dull pressure" in her head that is worse at the end of the day. She is an office manager and is able to work through the pain. The patient has a history of seasonal allergies and her sister has migraine headaches. Which of the following is the most likely diagnosis?

A. Chronic sinusitis
B. Cluster headache
C. Giant cell arteritis
D. Intracranial neoplasm
E. Migraine without aura
F. Tension headache

Submit

Block Time Remaining: 00:00:48
TUTOR

3 | Feedback | Suspend | End Block

Settings

1 2 3 4 5 6 7 8 9 10 11 12 13 14 15 16 17 18 19 20 21 22 23 24 25 26 27 28 29 30

Item 25 of 40
Question Id: 7492

Mark | Previous | Next | Full Screen | Tutorial | Lab Values | Notes | Calculator | Reverse Color | Text Zoom | Settings

A 27-year-old woman comes to the office due to almost daily headaches for the past 3 months. The patient describes constant "dull pressure" in her head that is worse at the end of the day. She is an office manager and is able to work through the pain. The patient has a history of seasonal allergies and her sister has migraine headaches. Which of the following is the most likely diagnosis?

- A. Chronic sinusitis (16%)
- B. Cluster headache (3%)
- C. Giant cell arteritis (0%)
- D. Intracranial neoplasm (2%)
- E. Migraine without aura (4%)
- ✓ F. Tension headache (73%)

Omitted
Correct answer
F

73%
Answered correctly

01 sec
Time Spent

03/11/2020
Last Updated

Explanation

	Types of headache		
	Migraine	Cluster	Tension
Sex			

Block Time Remaining: 00:00:49
TUTOR

3 | Feedback | Suspend | End Block

	Types of headache		
	Migraine	**Cluster**	**Tension**
Sex predilection	Female > male	Male > female	Female > male
Family history	Often present	±	None
Onset	Variable	During sleep or similar timing daily	Under stress
Location	Often unilateral	Behind one eye	Band-like pattern around the head (bilateral)
Character	Pulsatile & throbbing	Excruciating, sharp & steady	Dull, tight & persistent
Duration	4-72 hours	15-180 minutes	30 minutes to months/years
Associated symptoms	Photophobia, phonophobia & nausea, ± aura	Ipsilateral sweating, facial flushing, nasal congestion & pupillary changes	Muscle tenderness in the head, neck, or shoulders

This woman with dull, near-daily headaches has **tension headaches** (THs), the most common form of headache. THs are likely due to sensitization of peripheral nociceptors leading to increased perception of myofascial pain. Patients typically develop mild to moderate, achy, or pressure-like pain that is often **bilateral** and may involve the occipitonuchal, temporal, or frontal regions of the head. Pericranial **muscle tenderness** (eg, head, neck, shoulder) is common.

THs are not associated with other neurologic symptoms or nausea/vomiting and are often precipitated by **stress** and fatigue. They may persist for days, months, or even years but (unlike migraines and cluster headaches) do not typically limit a patient's ability to perform daily functions. Treatment is typically with **simple analgesics** (eg, nonsteroidal anti-inflammatory drugs, acetaminophen).

(Choice A) Chronic sinusitis can cause facial pain and tenderness but is often associated with nasal congestion and mucopurulent nasal drainage. A reduced sense of smell and taste is also common.

1 2 3 4 5 6 7 8 9 10 11 12 13 14 15 16 17 18 19 20 21 22 23 24 25 26 27 28 29 30

pressure-like pain that is often **bilateral** and may involve the occipitonuchal, temporal, or frontal regions of the head. Pericranial **muscle tenderness** (eg, head, neck, shoulder) is common.

THs are not associated with other neurologic symptoms or nausea/vomiting and are often precipitated by **stress** and fatigue. They may persist for days, months, or even years but (unlike migraines and cluster headaches) do not typically limit a patient's ability to perform daily functions. Treatment is typically with **simple analgesics** (eg, nonsteroidal anti-inflammatory drugs, acetaminophen).

(Choice A) Chronic sinusitis can cause facial pain and tenderness but is often associated with nasal congestion and mucopurulent nasal drainage. A reduced sense of smell and taste is also common.

(Choice B) Cluster headaches most commonly affect men and present as severe, unilateral, orbital or temporal pain with associated autonomic symptoms (eg, lacrimation, rhinorrhea, diaphoresis). The headaches are typically brief (15-180 minutes), debilitating, and may awaken patients from sleep.

(Choice C) Giant cell arteritis is associated with an acute headache that is typically accompanied by scalp tenderness, visual symptoms, and jaw claudication. It occurs exclusively in older patients (age ≥50) and is often associated with polymyalgia rheumatica.

(Choice D) Brain tumors typically cause nausea, vomiting, and headaches that worsen with changes in body position. In addition, the presence of other focal neurologic signs would be expected due to compression of surrounding brain structures by the expanding tumor.

(Choice E) Migraine headaches are characterized by often debilitating, episodic, unilateral, pulsatile headaches typically associated with nausea, photophobia, and phonophobia. Some patients have focal neurologic symptoms that precede or accompany the headache (ie, aura).

Educational objective:
Tension headaches are the most common form of headache. They are characterized by an achy or pressure-like pain that is often bilateral and associated with pericranial muscle tenderness. Tension headaches are not associated with other neurologic symptoms and do not typically limit a patient's ability to perform daily functions.

Pathology	Nervous System	Tension headache
Subject	System	Topic

A 45-year-old man is brought to the emergency department after sustaining a closed-head injury in a motor vehicle accident. The patient was found unresponsive in the field and had several generalized tonic-clonic seizures during transport. He has a history of hypertension as well as cocaine and alcohol abuse. Temperature is 36.7 C (98 F), blood pressure is 170/96 mm Hg, pulse is 50/min, and respirations are 10/min. Pulse oximetry shows 98% on mechanical ventilation with 50% oxygen. On examination, the patient is comatose with mid-positioned and fixed pupils and rigid extension of the upper and lower extremities. A noncontrast head CT scan is shown in the image below.

Settings

1 2 3 4 5 6 7 8 9 10 11 12 13 14 15 16 17 18 19 20 21 22 23 24 25 26 27 28 29 30

Item 26 of 40
Question Id: 11574

Mark | Previous | Next | Full Screen | Tutorial | Lab Values | Notes | Calculator | Reverse Color | Text Zoom | Settings

A 45-year-old man is brought to the emergency department after sustaining a closed-head injury in a motor vehicle accident. The patient was found unresponsive in the field and had several generalized tonic-clonic seizures during transport. He has a history of hypertension as well as cocaine and alcohol abuse. Temperature is 36.7 C (98 F), blood pressure is 170/96 mm Hg, pulse is 50/min, and respirations are 10/min. Pulse oximetry shows 98% on mechanical ventilation with 50% oxygen. On examination, the patient is comatose with mid-positioned and fixed pupils and rigid extension of the upper and lower extremities. A noncontrast head CT scan is shown in the image below.

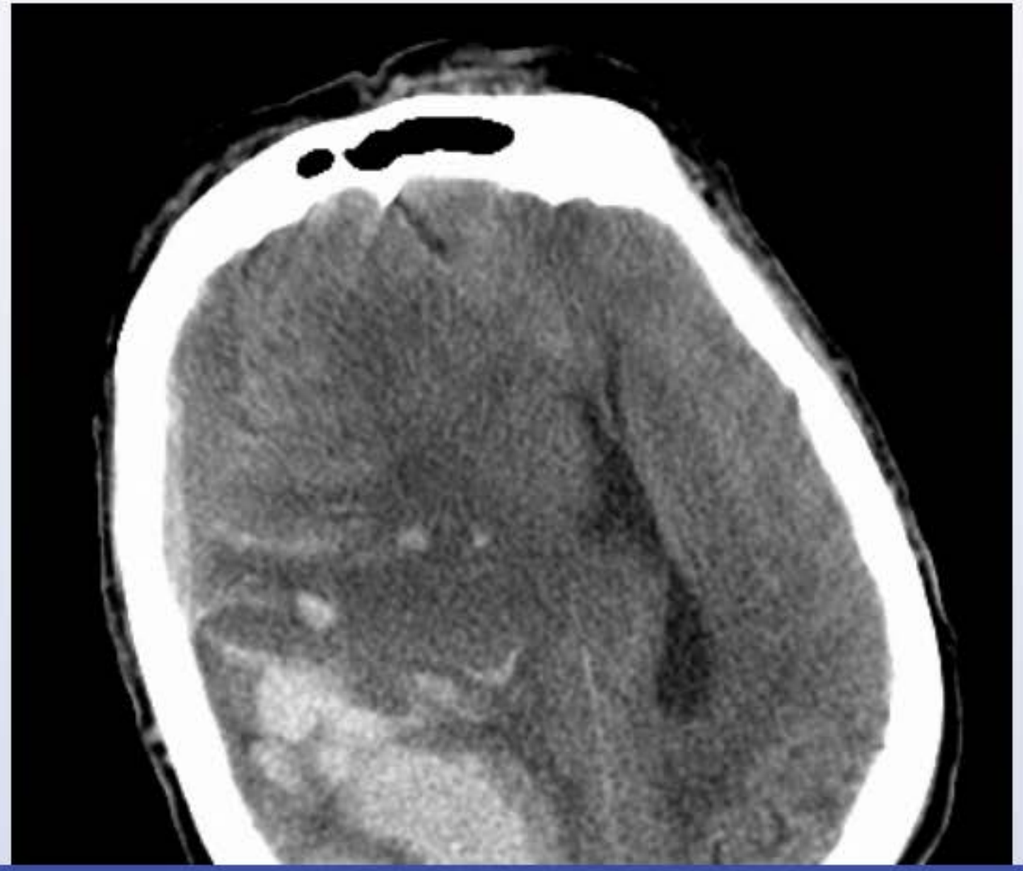

Block Time Remaining: 00:00:50
TUTOR

3 | Feedback | Suspend | End Block

Settings

1 2 3 4 5 6 7 8 9 10 11 12 13 14 15 16 17 18 19 20 21 22 23 24 25 26 27 28 29 30

Item 26 of 40
Question Id: 11574

Mark | Previous | Next | Full Screen | Tutorial | Lab Values | Notes | Calculator | Reverse Color | Text Zoom | Settings

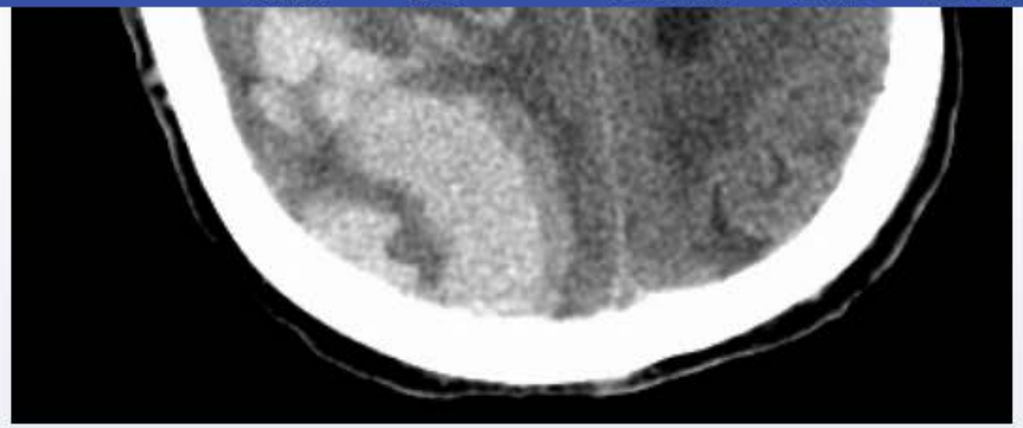

Damage to which of the following neural structures is the most likely explanation for this patient's abnormal posturing?

- A. Cerebellar vermis
- B. Cerebral hemispheres
- C. Cervical spinal cord
- D. Internal capsule
- E. Pons
- F. Substantia nigra
- G. Thalamus

Submit

Block Time Remaining: 00:00:52
TUTOR

3 | Feedback | Suspend | End Block

Settings

1 2 3 4 5 6 7 8 9 10 11 12 13 14 15 16 17 18 19 20 21 22 23 24 25 26 27 28 29 30

Item 26 of 40
Question Id: 11574

Mark | Previous | Next | Full Screen | Tutorial | Lab Values | Notes | Calculator | Reverse Color | Text Zoom | Settings

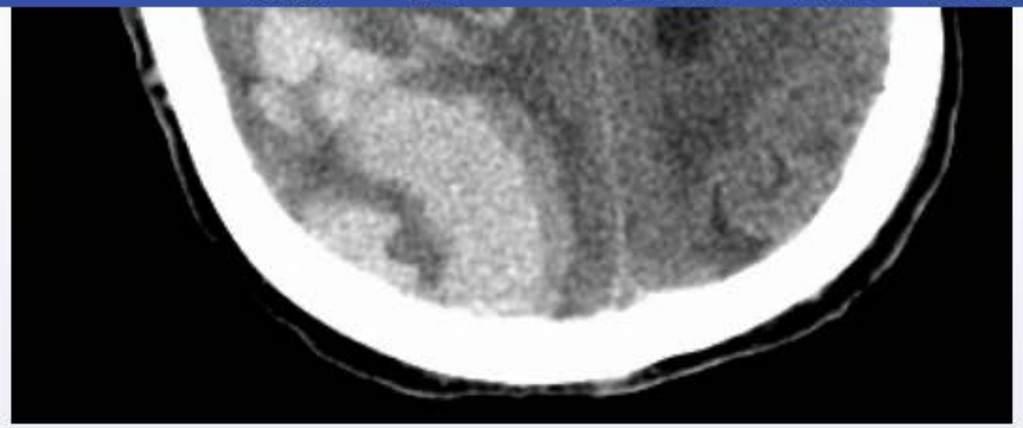

Damage to which of the following neural structures is the most likely explanation for this patient's abnormal posturing?

- A. Cerebellar vermis (12%)
- B. Cerebral hemispheres (24%)
- C. Cervical spinal cord (3%)
- D. Internal capsule (14%)
- ✓ E. Pons (36%)
- F. Substantia nigra (2%)
- G. Thalamus (5%)

Omitted
Correct answer

36%
Answered correctly

04 secs
Time Spent

02/21/2020
Last Updated

Block Time Remaining: 00:00:53
TUTOR

3 | Feedback | Suspend | End Block

Settings

1
2
3
4
5
6
7
8
9
10
11
12
13
14
15
16
17
18
19
20
21
22
23
24
25
26
27
28
29
30

Item 26 of 40
Question Id: 11574

Mark | Previous | Next | Full Screen | Tutorial | Lab Values | Notes | Calculator | Reverse Color | Text Zoom | Settings

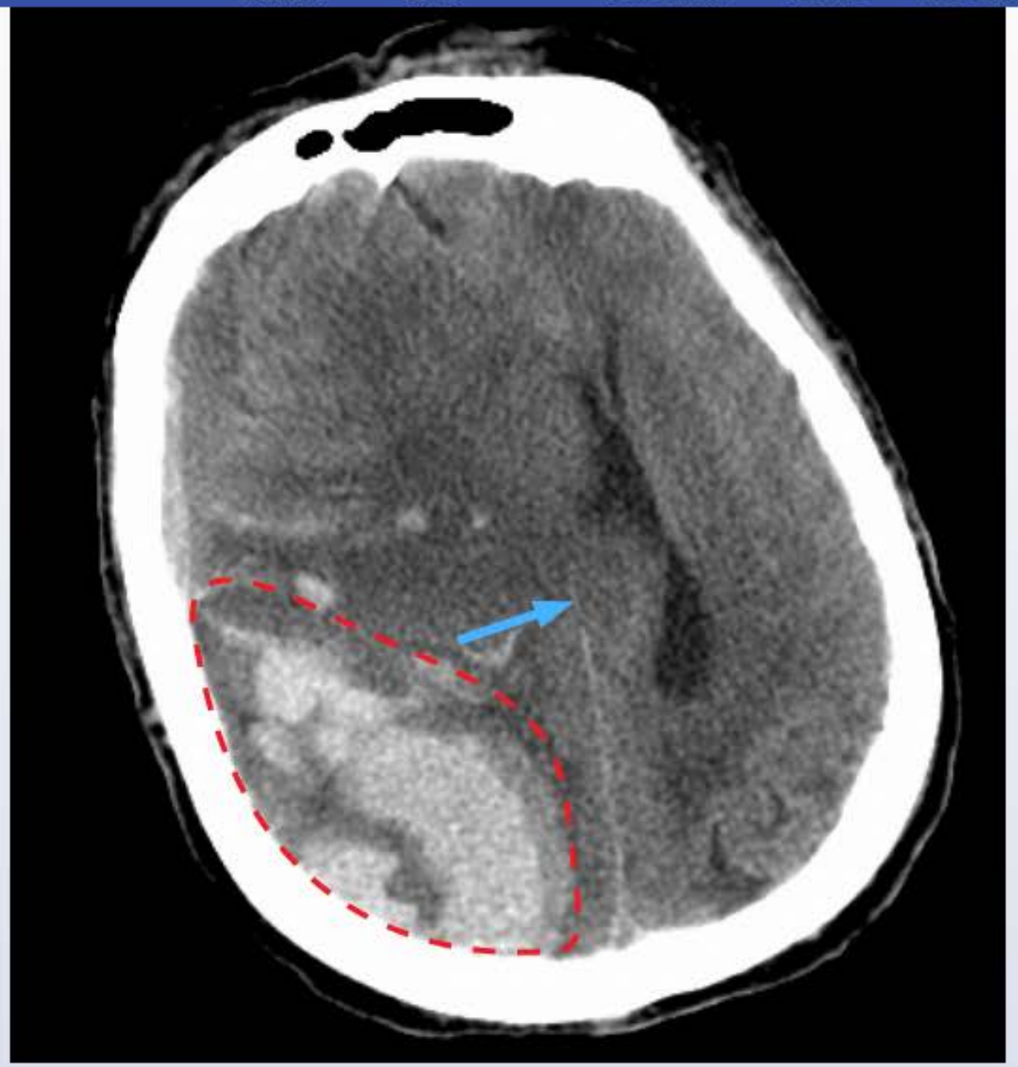

This patient has a severe **traumatic intracranial hemorrhage** (red, dashed circle) likely complicated by **transtentorial (uncal) herniation**.

Intraparenchymal brain hemorrhage can cause mass effect, leading to horizontal shifts in midline structures (blue arrow) and impaired

Block Time Remaining: 00:00:53
TUTOR

3 | Feedback | Suspend | End Block

1 2 3 4 5 6 7 8 9 10 11 12 13 14 15 16 17 18 19 20 21 22 23 24 25 26 27 28 29 30

This patient has a severe **traumatic intracranial hemorrhage** (red, dashed circle) likely complicated by **transtentorial (uncal) herniation**. Intraparenchymal brain hemorrhage can cause mass effect, leading to horizontal shifts in midline structures (blue arrow) and impaired consciousness. Further hematoma expansion and increasing intracranial pressure may cause seizure and **brainstem compression** with Cushing triad (hypertension, bradycardia, respiratory depression). Uncal herniation initially disrupts the ipsilateral oculomotor nerve leading to a fixed dilated pupil with "down and out" eye deviation; however, as the herniation progresses, injury to the midbrain and upper pons typically results in mid-positioned and fixed pupils bilaterally with loss of vestibulo-ocular reflexes.

Damage to the brainstem **at or below** the level of the **red nucleus** (eg, midbrain tegmentum, pons) usually causes decerebrate (extensor) posturing due to loss of descending excitation to the upper limb flexors (via the rubrospinal tract) and extensor predominance (due to unopposed vestibulospinal tract output). In contrast, damage to neural structures above the red nucleus (eg, cerebral hemispheres, internal capsule) typically results in decorticate (flexor) posturing due to loss of descending inhibition of the red nucleus and subsequent hyperactivity of upper limb flexors **(Choices B and D)**. (Note: The vestibulospinal tract originates from vestibular nuclei at the pontomedullary junction and does not receive significant descending cortical inhibition.)

(Choice A) Damage to the cerebellar vermis usually affects balance and coordination of the axial/proximal limb muscles, resulting in gait and truncal ataxia. Injury to this structure may also result in nystagmus and vertigo due to its role in vestibular function.

(Choice C) The cervical spinal cord is commonly damaged in the setting of closed-head injury, which may lead acutely to flaccid quadriplegia/spinal shock (absence of flexor and extensor motor tone).

(Choice F) Damage to the substantia nigra can result in dopamine depletion in this region, with increased inhibition of the thalamus and decreased excitation of the motor cortex. This leads to motor features of Parkinson disease (eg, rigidity, bradykinesia, tremor).

(Choice G) The thalamus is the major relay station for almost all ascending sensory information. Although bilateral damage to the thalamus may result in coma, flexor/extensor posturing is not characteristic.

Educational objective:

Damage to the brainstem at/below the level of the red nucleus (eg, midbrain tegmentum, pons) typically results in decerebrate (extensor)

Settings

Item 26 of 40
Question Id: 11574

Mark | Previous | Next | Full Screen | Tutorial | Lab Values | Notes | Calculator | Reverse Color | Text Zoom | Settings

Exhibit Display

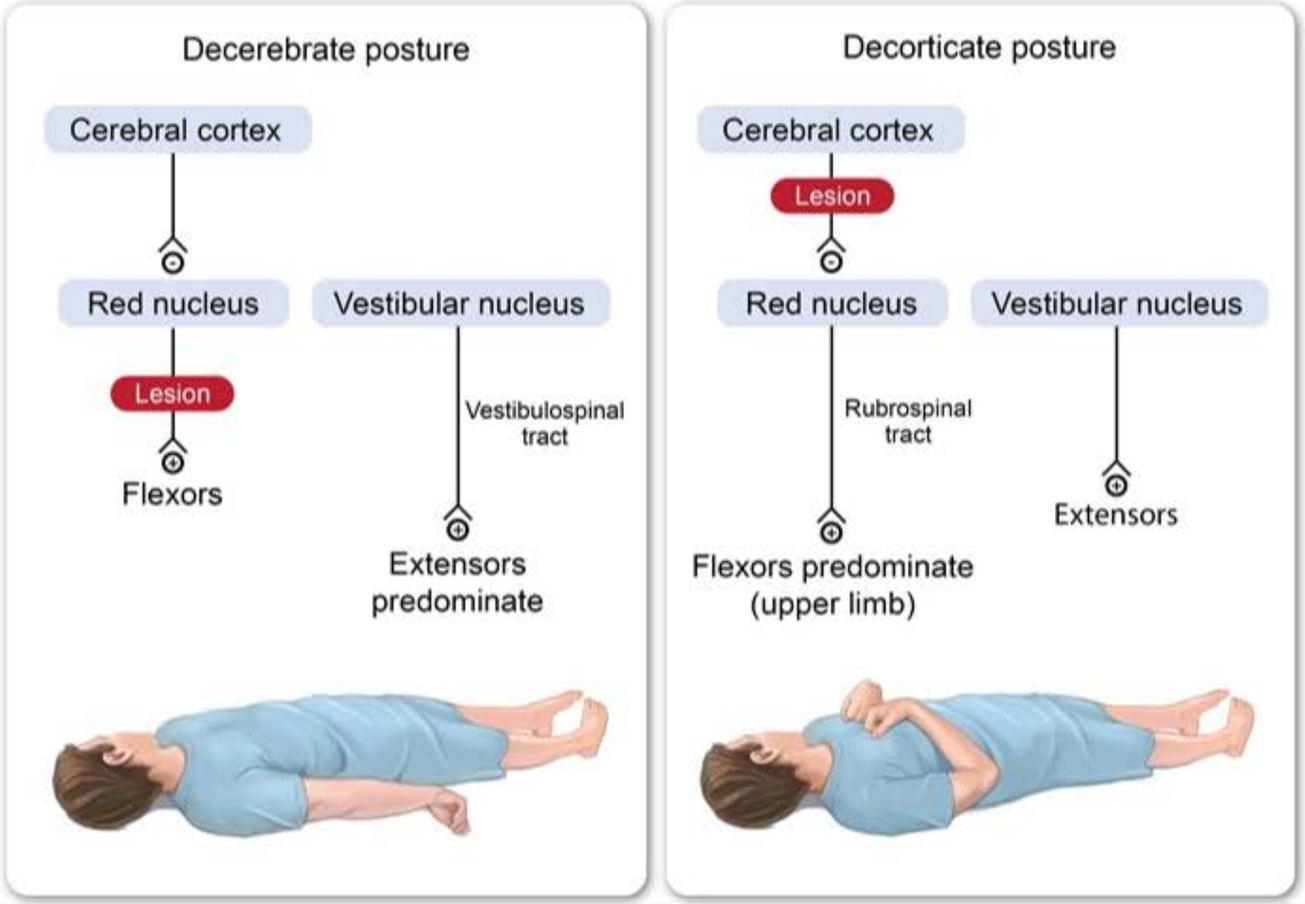

Zoom In | Zoom Out | Reset | Add To New Card | Existing Card

Block Time Remaining: 00:00:53
TUTOR

3 | Feedback | Suspend | End Block

results in decorticate (flexor) posturing due to loss of descending inhibition of the red nucleus and subsequent hyperactivity of upper limb flexors **(Choices B and D)**. (Note: The vestibulospinal tract originates from vestibular nuclei at the pontomedullary junction and does not receive significant descending cortical inhibition.)

(Choice A) Damage to the cerebellar vermis usually affects balance and coordination of the axial/proximal limb muscles, resulting in gait and truncal ataxia. Injury to this structure may also result in nystagmus and vertigo due to its role in vestibular function.

(Choice C) The cervical spinal cord is commonly damaged in the setting of closed-head injury, which may lead acutely to flaccid quadriplegia/spinal shock (absence of flexor and extensor motor tone).

(Choice F) Damage to the substantia nigra can result in dopamine depletion in this region, with increased inhibition of the thalamus and decreased excitation of the motor cortex. This leads to motor features of Parkinson disease (eg, rigidity, bradykinesia, tremor).

(Choice G) The thalamus is the major relay station for almost all ascending sensory information. Although bilateral damage to the thalamus may result in coma, flexor/extensor posturing is not characteristic.

Educational objective:
Damage to the brainstem at/below the level of the red nucleus (eg, midbrain tegmentum, pons) typically results in decerebrate (extensor) posturing. In contrast, damage to neural structures above the red nucleus (eg, cerebral hemispheres, internal capsule) typically results in decorticate (flexor) posturing.

References

- Neurological assessment of coma.
- Decerebrate rigidity in humans.

Pathology	Nervous System	Traumatic brain injury
Subject	System	Topic

Copyright © UWorld. All rights reserved.

Settings

1 2 3 4 5 6 7 8 9 10 11 12 13 14 15 16 17 18 19 20 21 22 23 24 25 26 27 28 29 30

Item 27 of 40
Question Id: 495

Mark | Previous | Next | Full Screen | Tutorial | Lab Values | Notes | Calculator | Reverse Color | Text Zoom | Settings

A 55-year-old right-handed woman complained of acute onset headache and difficulty with vision. She quickly becomes unconscious en route to the hospital. She has a past medical history of hypertension. Her medications include aspirin and lisinopril at home. Her blood pressure is 150/90 mm Hg and pulse is 90/min and regular. A stat head CT scan without contrast demonstrates an acute hemorrhage in the left temporal lobe and compression of the anterior medial temporal lobe against the free margin of the tentorium cerebelli. Which of the following cranial nerves is most likely to be compromised in this patient?

- A. Optic
- B. Oculomotor
- C. Trochlear
- D. Trigeminal
- E. Abducens
- F. Facial
- G. Vagus

Submit

Block Time Remaining: 00:00:53
TUTOR

2 | Feedback | Suspend | End Block

1 2 3 4 5 6 7 8 9 10 11 12 13 14 15 16 17 18 19 20 21 22 23 24 25 26 27 28 29 30

A 55-year-old right-handed woman complained of acute onset headache and difficulty with vision. She quickly becomes unconscious en route to the hospital. She has a past medical history of hypertension. Her medications include aspirin and lisinopril at home. Her blood pressure is 150/90 mm Hg and pulse is 90/min and regular. A stat head CT scan without contrast demonstrates an acute hemorrhage in the left temporal lobe and compression of the anterior medial temporal lobe against the free margin of the tentorium cerebelli. Which of the following cranial nerves is most likely to be compromised in this patient?

- A. Optic (17%)
- ✓ B. Oculomotor (51%)
- C. Trochlear (8%)
- D. Trigeminal (6%)
- E. Abducens (8%)
- F. Facial (5%)
- G. Vagus (2%)

Omitted
Correct answer
B

51%
Answered correctly

02 secs
Time Spent

06/13/2020
Last Updated

Explanation

Settings

1 2 3 4 5 6 7 8 9 10 11 12 13 14 15 16 17 18 19 20 21 22 23 24 25 26 27 28 29 30

Item 27 of 40
Question Id: 495

Mark | Previous | Next | Full Screen | Tutorial | Lab Values | Notes | Calculator | Reverse Color | Text Zoom | Settings

Major herniations of the brain

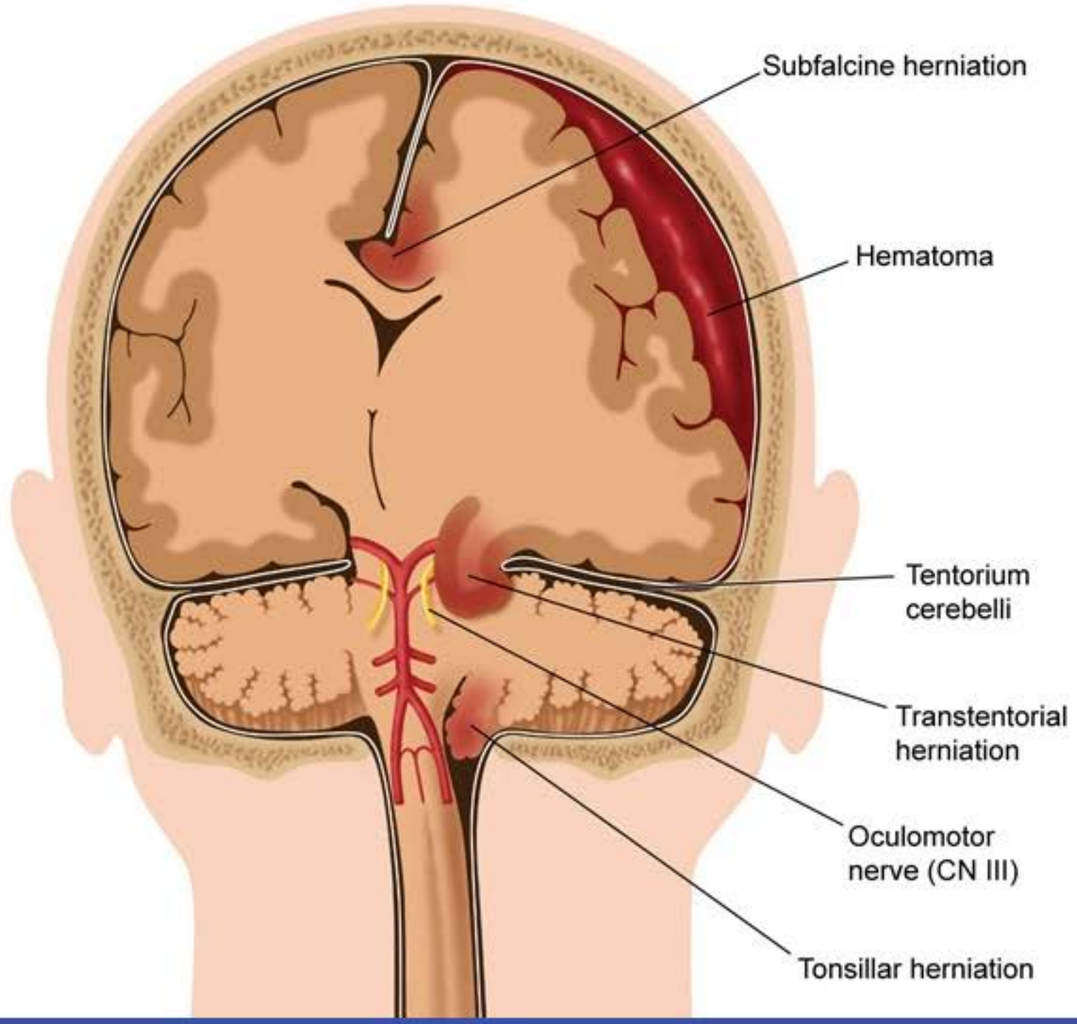

Block Time Remaining: 00:00:55
TUTOR

2 | Feedback | Suspend | End Block

©UWorld

The cranial vault is limited by the rigid cranial bones and divided into compartments by the dural folds (i.e., falx cerebri and tentorium cerebelli). There is no room for brain expansion in the event of a brain edema, tumor, or hemorrhage. As a result, portions of the brain can protrude through the openings in the falx cerebri or tentorium cerebelli or through the foramen magnum. This process is called herniation.

Transtentorial (i.e., uncal) herniation occurs when the medial temporal lobe (i.e., uncus) herniates through the gap between the crus cerebri and the tentorium. In **subfalcine herniation**, the cingulate gyrus herniates under the falx cerebri, potentially compressing the anterior cerebral artery. In **tonsillar herniation**, the cerebellar tonsils displace through the foramen magnum and compress the medulla.

The most common cause of transtentorial herniation is an ipsilateral mass lesion (e.g., brain tumor, subdural or epidural hematoma, and intracerebral hemorrhage). This mass causes an increase in supratentorial pressure on the side of the lesion and forces the ipsilateral parahippocampal uncus through the tentorial incisure. As a result, the following structures may become compressed:

1. Ipsilateral oculomotor nerve (CN III) compression leads to a fixed and dilated pupil on the side of compression. Paralysis of the oculomotor muscles occurs later and leads to ptosis and a "down-and-out" position of the ipsilateral eye.
2. Ipsilateral posterior cerebral artery compression leads to contralateral homonymous hemianopsia with macular sparing.
3. Compression of the contralateral cerebral peduncle against the tentorium may occur. The damage to the contralateral corticospinal tract leads to ipsilateral hemiparesis. Compression of the ipsilateral cerebral peduncle can also cause contralateral hemiparesis.
4. Brainstem hemorrhages (i.e., Duret hemorrhages) may occur in the pons and midbrain due to stretching and rupture of the basilar artery. This is usually fatal.

None of the other cranial nerves becomes compressed due to uncal herniation **(Choices A, C, D, E, F, G)**.

Educational objective:
Transtentorial (i.e., uncal) herniation is a complication of an ipsilateral mass lesion, such as a hemorrhage or brain tumor. The first sign of uncal herniation is a fixed and dilated pupil on the side of the lesion. Ipsilateral paralysis of oculomotor muscles, contralateral or ipsilateral hemiparesis, and contralateral homonymous hemianopsia with macular sparing may also occur.

References

- Brain herniations in patients with intracerebral hemorrhage

1 2 3 4 5 6 7 8 9 10 11 12 13 14 15 16 17 18 19 20 21 22 23 24 25 26 27 28 29 30

the tentorium. In **subfalcine herniation**, the cingulate gyrus herniates under the falx cerebri, potentially compressing the anterior cerebral artery. In **tonsillar herniation**, the cerebellar tonsils displace through the foramen magnum and compress the medulla.

The most common cause of transtentorial herniation is an ipsilateral mass lesion (e.g., brain tumor, subdural or epidural hematoma, and intracerebral hemorrhage). This mass causes an increase in supratentorial pressure on the side of the lesion and forces the ipsilateral parahippocampal uncus through the tentorial incisure. As a result, the following structures may become compressed:

1. Ipsilateral oculomotor nerve (CN III) compression leads to a fixed and dilated pupil on the side of compression. Paralysis of the oculomotor muscles occurs later and leads to ptosis and a "down-and-out" position of the ipsilateral eye.
2. Ipsilateral posterior cerebral artery compression leads to contralateral homonymous hemianopsia with macular sparing.
3. Compression of the contralateral cerebral peduncle against the tentorium may occur. The damage to the contralateral corticospinal tract leads to ipsilateral hemiparesis. Compression of the ipsilateral cerebral peduncle can also cause contralateral hemiparesis.
4. Brainstem hemorrhages (i.e., Duret hemorrhages) may occur in the pons and midbrain due to stretching and rupture of the basilar artery. This is usually fatal.

None of the other cranial nerves becomes compressed due to uncal herniation **(Choices A, C, D, E, F, G)**.

Educational objective:
Transtentorial (i.e., uncal) herniation is a complication of an ipsilateral mass lesion, such as a hemorrhage or brain tumor. The first sign of uncal herniation is a fixed and dilated pupil on the side of the lesion. Ipsilateral paralysis of oculomotor muscles, contralateral or ipsilateral hemiparesis, and contralateral homonymous hemianopsia with macular sparing may also occur.

References

- Brain herniations in patients with intracerebral hemorrhage

Pathology	Nervous System	Brain herniation
Subject	System	Topic

Copyright © UWorld. All rights reserved.

Settings

1 2 3 4 5 6 7 8 9 10 11 12 13 14 15 16 17 18 19 20 21 22 23 24 25 26 27 28 29 30

Item 28 of 40
Question Id: 11843

Mark | Previous | Next | Full Screen | Tutorial | Lab Values | Notes | Calculator | Reverse Color | Text Zoom | Settings

A 2-year-old boy who recently immigrated to the United States with his family is brought to the office for irritability and excessive crying. The mother's pregnancy was uneventful, but the patient was delivered via cesarean section due to obstructed labor. His mother reports that he has developed more slowly than his brother in ability to lift his head, crawl, and walk. She has also noticed that the patient's head is larger than other children of the same age. His weight is at the 60th percentile, height is at the 50th percentile, and head circumference is at the 95th percentile. CT scan of the head is shown in the image below.

Block Time Remaining: 00:00:56
TUTOR

5 | Feedback | Suspend | End Block

Settings

1 2 3 4 5 6 7 8 9 10 11 12 13 14 15 16 17 18 19 20 21 22 23 24 25 26 27 28 29 30

Item 28 of 40
Question Id: 11843

Mark | Previous | Next | Full Screen | Tutorial | Lab Values | Notes | Calculator | Reverse Color | Text Zoom | Settings

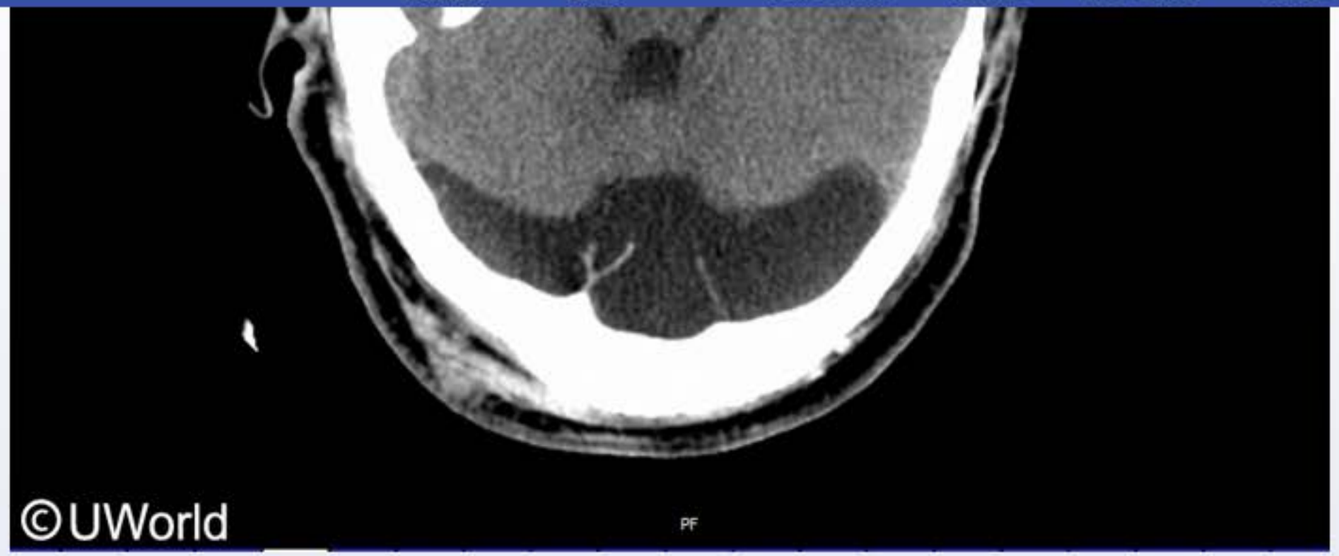

Which of the following is the most likely diagnosis?

- A. Arnold-Chiari malformation
- B. Arteriovenous malformation
- C. Dandy-Walker malformation
- D. Encephalocele
- E. Hypoxic-ischemic injury

Submit

Block Time Remaining: 00:00:57
TUTOR

5 | Feedback | Suspend | End Block

Settings

Item 28 of 40
Question Id: 11843

Mark | Previous | Next | Full Screen | Tutorial | Lab Values | Notes | Calculator | Reverse Color | Text Zoom | Settings

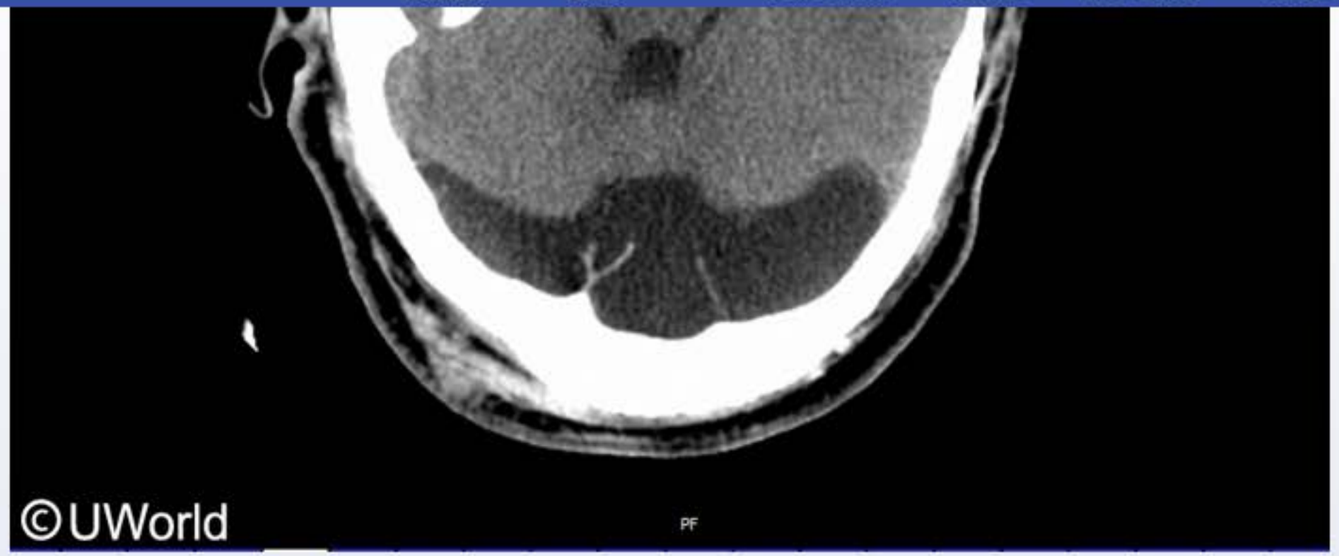

Which of the following is the most likely diagnosis?

- A. Arnold-Chiari malformation (17%)
- B. Arteriovenous malformation (5%)
- ✓ C. Dandy-Walker malformation (61%)
- D. Encephalocele (9%)
- E. Hypoxic-ischemic injury (6%)

Omitted
Correct answer

61%
Answered correctly

04 secs
Time Spent

06/23/2020
Last Updated

Block Time Remaining: 00:00:59
TUTOR

5 | Feedback | Suspend | End Block

Settings

1
2
3
4
5
6
7
8
9
10
11
12
13
14
15
16
17
18
19
20
21
22
23
24
25
26
27
28
29
30

Item 28 of 40
Question Id: 11843

Mark | Previous | Next | Full Screen | Tutorial | Lab Values | Notes | Calculator | Reverse Color | Text Zoom | Settings

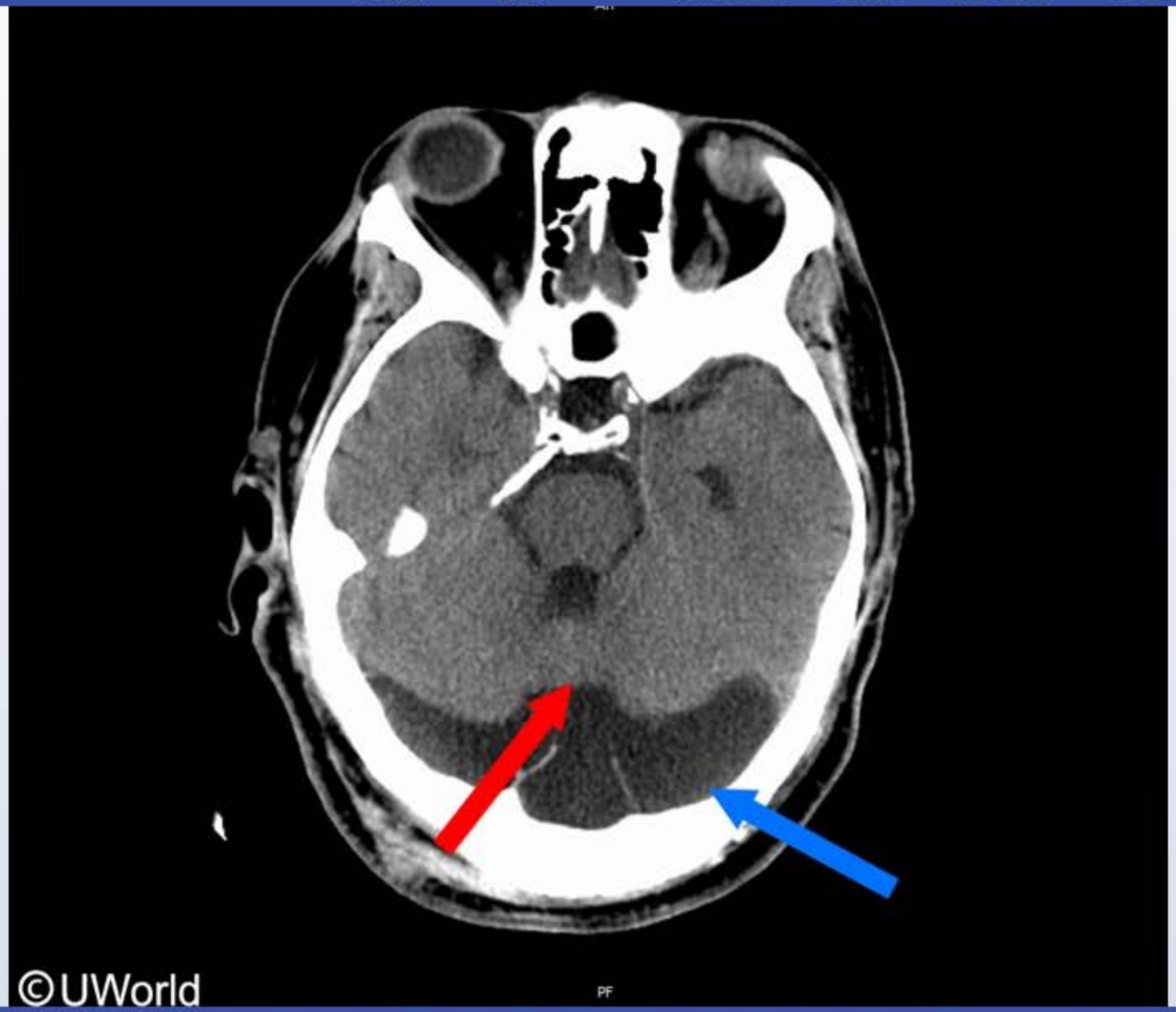

Block Time Remaining: 00:00:59
TUTOR

5 | Feedback | Suspend | End Block

This child likely has **Dandy-Walker malformation**, a developmental anomaly characterized by **hypoplasia/absence** of the **cerebellar vermis** (red arrow) and **cystic dilation** of the **fourth ventricle** with posterior fossa enlargement (blue arrow).

Patients often present during infancy with developmental delay and progressive skull enlargement. Cerebellar dysfunction can result in unsteadiness and impaired muscle coordination. Non-communicating **hydrocephalus** may occur due to atresia of the foramina of Luschka and Magendie, resulting in symptoms of elevated intracranial pressure (eg, irritability, vomiting). Other associated features can include agenesis of the corpus callosum and malformations involving the face, heart, or limbs.

(Choice A) Arnold-Chiari malformation, also known as Chiari II malformation, is characterized by downward displacement of the cerebellar vermis and tonsils below the foramen magnum. Patients also frequently have spinal myelomeningocele.

(Choice B) Brain arteriovenous malformations are developmental vascular lesions that usually present at age 10-30 with intracranial hemorrhage, seizure, headache, or focal neurologic deficits.

(Choice D) An encephalocele is a rare neural tube defect characterized by protrusion of the brain and meninges through an abnormal opening in the skull.

(Choice E) Hypoxic-ischemic brain injury may occur with complicated deliveries (eg, emergency cesarean section), but it typically presents with altered consciousness and decreased spontaneous movements during the neonatal period. Neuroimaging classically shows watershed necrosis of the gray matter between perfusion zones of the major cerebral arteries.

Educational objective:
Dandy-Walker malformation is a developmental anomaly characterized by hypoplasia/absence of the cerebellar vermis and cystic dilation of the fourth ventricle with posterior fossa enlargement. Patients often present during infancy with developmental delay and progressive skull enlargement. Other features may include cerebellar dysfunction and non-communicating hydrocephalus.

References

- Diagnosis and management of the Dandy-Walker malformation: 30 years of experience.

Settings

1
2
3
4
5
6
7
8
9
10
11
12
13
14
15
16
17
18
19
20
21
22
23
24
25
26
27
28
29
30

Item 28 of 40
Question Id: 11843

Mark | Previous | Next | Full Screen | Tutorial | Lab Values | Notes | Calculator | Reverse Color | Text Zoom | Settings

Exhibit Display

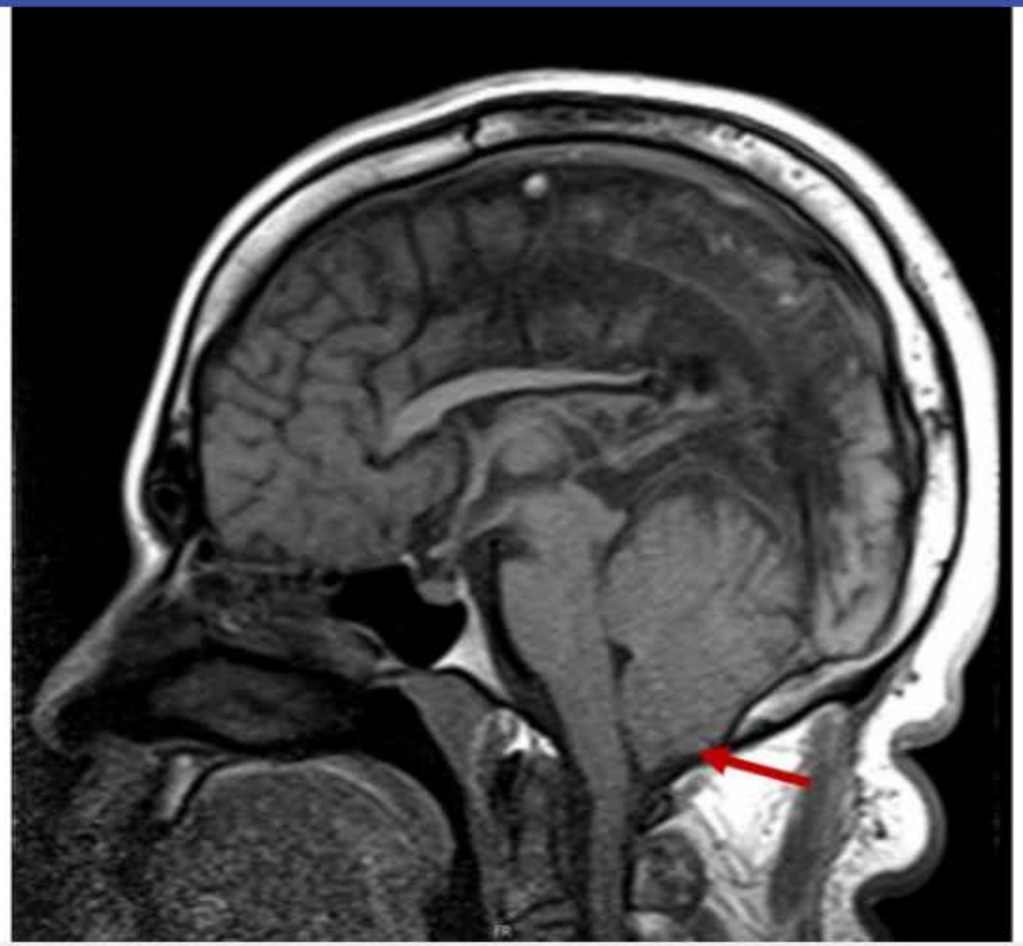

Zoom In | Zoom Out | Reset | Add To New Card | Existing Card

Block Time Remaining: 00:00:59
TUTOR

5 | Feedback | Suspend | End Block

Settings

1
2
3
4
5
6
7
8
9
10
11
12
13
14
15
16
17
18
19
20
21
22
23
24
25
26
27
28
29
30

Item 28 of 40
Question Id: 11843

Mark | Previous | Next | Full Screen | Tutorial | Lab Values | Notes | Calculator | Reverse Color | Text Zoom | Settings

Exhibit Display

Zoom In | Zoom Out | Reset | Add To New Card | Existing Card

Block Time Remaining: 00:00:59
TUTOR

5 | Feedback | Suspend | End Block

unsteadiness and impaired muscle coordination. Non-communicating **hydrocephalus** may occur due to atresia of the foramina of Luschka and Magendie, resulting in symptoms of elevated intracranial pressure (eg, irritability, vomiting). Other associated features can include agenesis of the corpus callosum and malformations involving the face, heart, or limbs.

(Choice A) Arnold-Chiari malformation, also known as Chiari II malformation, is characterized by downward displacement of the cerebellar vermis and tonsils below the foramen magnum. Patients also frequently have spinal myelomeningocele.

(Choice B) Brain arteriovenous malformations are developmental vascular lesions that usually present at age 10-30 with intracranial hemorrhage, seizure, headache, or focal neurologic deficits.

(Choice D) An encephalocele is a rare neural tube defect characterized by protrusion of the brain and meninges through an abnormal opening in the skull.

(Choice E) Hypoxic-ischemic brain injury may occur with complicated deliveries (eg, emergency cesarean section), but it typically presents with altered consciousness and decreased spontaneous movements during the neonatal period. Neuroimaging classically shows watershed necrosis of the gray matter between perfusion zones of the major cerebral arteries.

Educational objective:
Dandy-Walker malformation is a developmental anomaly characterized by hypoplasia/absence of the cerebellar vermis and cystic dilation of the fourth ventricle with posterior fossa enlargement. Patients often present during infancy with developmental delay and progressive skull enlargement. Other features may include cerebellar dysfunction and non-communicating hydrocephalus.

References

- Diagnosis and management of the Dandy-Walker malformation: 30 years of experience.

Pathology	Nervous System	Dandy walker syndrome
Subject	System	Topic

Copyright © UWorld. All rights reserved.

Settings

1 2 3 4 5 6 7 8 9 10 11 12 13 14 15 16 17 18 19 20 21 22 23 24 25 26 27 28 29 30

Item 29 of 40
Question Id: 63

Mark | Previous | Next | Full Screen | Tutorial | Lab Values | Notes | Calculator | Reverse Color | Text Zoom | Settings

A 54-year-old man is brought to the emergency department due to acute onset mental status change and double vision. On examination, he is disoriented to time and place and has a decreased attention span. Further questioning reveals memory impairment that appears to be most severe during the last several years. Neurologic examination shows horizontal nystagmus evoked on lateral gaze with bilateral weakness of the lateral rectus muscles. The patient is unable to stand without external support. Thiamine infusion is started immediately, and his condition improves significantly over the next several days. Which of the following neurologic findings is most likely to persist despite treatment?

- A. Ataxia
- B. Disorientation
- C. Inattention
- D. Memory loss
- E. Ophthalmopathy

Submit

Block Time Remaining: 00:00:59
TUTOR

2 | Feedback | Suspend | End Block

1 2 3 4 5 6 7 8 9 10 11 12 13 14 15 16 17 18 19 20 21 22 23 24 25 26 27 28 29 30

A 54-year-old man is brought to the emergency department due to acute onset mental status change and double vision. On examination, he is disoriented to time and place and has a decreased attention span. Further questioning reveals memory impairment that appears to be most severe during the last several years. Neurologic examination shows horizontal nystagmus evoked on lateral gaze with bilateral weakness of the lateral rectus muscles. The patient is unable to stand without external support. Thiamine infusion is started immediately, and his condition improves significantly over the next several days. Which of the following neurologic findings is most likely to persist despite treatment?

- A. Ataxia (6%)
- B. Disorientation (0%)
- C. Inattention (1%)
- ✓ D. Memory loss (82%)
- E. Ophthalmopathy (8%)

Omitted
Correct answer
D

82%
Answered correctly

02 secs
Time Spent

04/20/2020
Last Updated

Explanation

Features of Wernicke-Korsakoff syndrome	
Associated conditions	• Chronic **alcoholism** (most common) • Malnutrition

Features of Wernicke-Korsakoff syndrome	
Associated conditions	• Chronic **alcoholism** (most common) • Malnutrition
Pathophysiology	• **Thiamine deficiency** → impairs ATP generation → neuronal dysfunction/death • Paraventricular lesions (eg, **mammillary bodies**, dorsomedial thalamus)
Clinical findings	• **Confusion** • **Oculomotor dysfunction** (eg, horizontal nystagmus & bilateral abducens palsy) • Postural & gait **ataxia** • Memory impairment (permanent)
Treatment	• Intravenous thiamine • Administration of glucose before thiamine can worsen symptoms

The characteristic manifestations of Wernicke syndrome, a condition caused by chronic thiamine (vitamin B_1) deficiency, are as follows:

- **Oculomotor dysfunction**: Occurs due to damage involving the oculomotor nerve (CN III), abducens nerve (CN VI), and vestibular nuclei. It is rapidly reversible and usually resolves almost completely with thiamine administration **(Choice E)**.
- **Ataxia**: Caused by damage to the cerebellar cortex and vestibular nuclei. Unlike oculomotor function, ataxia takes longer to resolve and some patients may have permanent symptoms **(Choice A)**.
- **Mental status changes**: Disorientation, apathy, and decreased attention span respond well to treatment **(Choices B and C)**. However, memory and learning abnormalities usually persist as a condition known as Korsakoff syndrome.

Korsakoff syndrome is associated with damage to the **anterior and dorsomedial thalamic nuclei**. This results in memory loss and a psychological phenomenon called "confabulation." When patients with Korsakoff syndrome are unsure of a fact, they fill in the memory gap with a fabricated story that they themselves believe to be true. Korsakoff syndrome also results in an inability to form new memories (anterograde amnesia). These impairments in memory and learning are usually permanent.

The characteristic manifestations of Wernicke syndrome, a condition caused by chronic thiamine (vitamin B_1) deficiency, are as follows:

- **Oculomotor dysfunction**: Occurs due to damage involving the oculomotor nerve (CN III), abducens nerve (CN VI), and vestibular nuclei. It is rapidly reversible and usually resolves almost completely with thiamine administration **(Choice E)**.
- **Ataxia**: Caused by damage to the cerebellar cortex and vestibular nuclei. Unlike oculomotor function, ataxia takes longer to resolve and some patients may have permanent symptoms **(Choice A)**.
- **Mental status changes**: Disorientation, apathy, and decreased attention span respond well to treatment **(Choices B and C)**. However, memory and learning abnormalities usually persist as a condition known as Korsakoff syndrome.

Korsakoff syndrome is associated with damage to the **anterior and dorsomedial thalamic nuclei**. This results in memory loss and a psychological phenomenon called "confabulation." When patients with Korsakoff syndrome are unsure of a fact, they fill in the memory gap with a fabricated story that they themselves believe to be true. Korsakoff syndrome also results in an inability to form new memories (anterograde amnesia). These impairments in memory and learning are usually permanent.

Thiamine should be administered immediately in all patients with suspected Wernicke encephalopathy because it can help limit irreversible neurologic damage.

Educational objective:
Oculomotor dysfunction, ataxia, and confusion form the triad of Wernicke syndrome. Most of these symptoms usually resolve after thiamine administration. Korsakoff syndrome is a complication of Wernicke encephalopathy, the hallmarks of which are permanent memory loss and confabulation.

References

- Wernicke-Korsakoff syndrome.

Pathology	Nervous System	Wernicke korsakoff syndrome
Subject	System	Topic

Copyright © UWorld. All rights reserved.

Settings

1 2 3 4 5 6 7 8 9 10 11 12 13 14 15 16 17 18 19 20 21 22 23 24 25 26 27 28 29 30

Item 30 of 40
Question Id: 908

Mark | Previous | Next | Full Screen | Tutorial | Lab Values | Notes | Calculator | Reverse Color | Text Zoom | Settings

A 23-year-old man with no prior history of seizure is brought to the emergency department after experiencing a generalized tonic-clonic seizure. His roommate says that the patient has had a fever and headache for the past 2 days and that today he was talking nonsensically. The patient works for a fast-food chain and occasionally smokes cigarettes on his breaks. He does not use alcohol or illicit drugs. Temperature is 38.6 C (101.5 F). MRI of the brain shows swelling of the temporal lobes. CSF analysis is most likely to reveal which of the following?

	Glucose	Protein	Cells
A.	Normal	Increased	Increased (erythrocytes)
B.	Low	Increased	Increased (neutrophils)
C.	Normal	Increased	Increased (lymphocytes, erythrocytes)
D.	Low	Increased	Increased (lymphocytes)
E.	Normal	Increased	Normal
F.	Normal	Normal	Normal

Submit

Block Time Remaining: 00:01:01
TUTOR

3 | Feedback | Suspend | End Block

Settings

1 2 3 4 5 6 7 8 9 10 11 12 13 14 15 16 17 18 19 20 21 22 23 24 25 26 27 28 29 30

Item 30 of 40
Question Id: 908

Mark | Previous | Next | Full Screen | Tutorial | Lab Values | Notes | Calculator | Reverse Color | Text Zoom | Settings

A 23-year-old man with no prior history of seizure is brought to the emergency department after experiencing a generalized tonic-clonic seizure. His roommate says that the patient has had a fever and headache for the past 2 days and that today he was talking nonsensically. The patient works for a fast-food chain and occasionally smokes cigarettes on his breaks. He does not use alcohol or illicit drugs. Temperature is 38.6 C (101.5 F). MRI of the brain shows swelling of the temporal lobes. CSF analysis is most likely to reveal which of the following?

	Glucose	Protein	Cells
A.	Normal (2%)	Increased	Increased (erythrocytes)
B.	Low (25%)	Increased	Increased (neutrophils)
✓ C.	Normal (54%)	Increased	Increased (lymphocytes, erythrocytes)
D.	Low (9%)	Increased	Increased (lymphocytes)
E.	Normal (3%)	Increased	Normal
F.	Normal (4%)	Normal	Normal

Omitted
Correct answer

54%
Answered correctly

01 sec
Time Spent

02/17/2020
Last Updated

Block Time Remaining: 00:01:02
TUTOR

3 | Feedback | Suspend | End Block

Cerebrospinal fluid analysis				
Diagnosis	**Cell count**	**Cell type**	**Glucose**	**Protein**
Bacterial meningitis	↑↑	Neutrophils	↓	↑↑
Viral meningitis	↑	Lymphocytes	Normal	Normal or ↑
Fungal or tuberculous meningitis	↑	Lymphocytes	↓	↑
Herpes encephalitis	↑	Lymphocytes & erythrocytes	Normal	↑
Guillain-Barré syndrome	Normal	Normal	Normal	↑

Herpes simplex virus (HSV) type 1 is the most common cause of sporadic **encephalitis**. Patients usually present with acute-onset fever, headache, altered mental status, and focal neurologic deficits or seizure. MRI classically shows **temporal lobe edema** as the virus enters the brain via the olfactory tract and travels to the olfactory cortex (located in the medial temporal lobe). Most patients have a "viral pattern" on cerebrospinal fluid (CSF) analysis with **lymphocytic pleocytosis**, normal glucose, and **elevated protein**. Hemorrhagic inflammation of the temporal lobes also usually causes **elevated erythrocytes** in the CSF.

(Choice A) Trauma from inserting the lumbar puncture needle can lead to a "traumatic tap," which is characterized by CSF evidence of normal glucose, elevated protein, and elevated erythrocytes.

(Choice B) Bacterial meningitis is usually associated with CSF evidence of low glucose, high protein, and a markedly elevated white blood cell count with a neutrophil predominance. Bacterial meningitis classically causes the triad of fever, neck stiffness, and altered mental state.

(Choice D) Tuberculous or fungal meningitis is often associated with CSF evidence of low glucose, moderately elevated protein, and lymphocytic pleocytosis. Most patients with herpes encephalitis have normal CSF glucose and elevated CSF erythrocytes.

(Choice E) Patients with Guillain-Barré syndrome (GBS) often have CSF protein elevations with normal cell counts (albuminocytologic

Herpes simplex virus (HSV) type 1 is the most common cause of sporadic **encephalitis**. Patients usually present with acute-onset fever, headache, altered mental status, and focal neurologic deficits or seizure. MRI classically shows **temporal lobe edema** as the virus enters the brain via the olfactory tract and travels to the olfactory cortex (located in the medial temporal lobe). Most patients have a "viral pattern" on cerebrospinal fluid (CSF) analysis with **lymphocytic pleocytosis**, normal glucose, and **elevated protein**. Hemorrhagic inflammation of the temporal lobes also usually causes **elevated erythrocytes** in the CSF.

(Choice A) Trauma from inserting the lumbar puncture needle can lead to a "traumatic tap," which is characterized by CSF evidence of normal glucose, elevated protein, and elevated erythrocytes.

(Choice B) Bacterial meningitis is usually associated with CSF evidence of low glucose, high protein, and a markedly elevated white blood cell count with a neutrophil predominance. Bacterial meningitis classically causes the triad of fever, neck stiffness, and altered mental state.

(Choice D) Tuberculous or fungal meningitis is often associated with CSF evidence of low glucose, moderately elevated protein, and lymphocytic pleocytosis. Most patients with herpes encephalitis have normal CSF glucose and elevated CSF erythrocytes.

(Choice E) Patients with Guillain-Barré syndrome (GBS) often have CSF protein elevations with normal cell counts (albuminocytologic dissociation), which is thought to be due to increased permeability of the blood-nerve-barrier at the level of the nerve root. GBS usually presents with progressive, symmetric ascending muscle weakness, not seizures and fevers.

Educational objective:
Viral infections of the central nervous system are usually characterized by elevated protein, normal glucose, and an elevated white blood cell count with a lymphocytic predominance. Patients with herpes encephalitis also usually have elevated erythrocytes in the cerebrospinal fluid due to hemorrhagic inflammation of the temporal lobes.

Pathology	Nervous System	HSV infection
Subject	System	Topic

Copyright © UWorld. All rights reserved.

Settings

1 2 3 4 5 6 7 8 9 10 11 12 13 14 15 16 17 18 19 20 21 22 23 24 25 26 27 28 29 30

Item 31 of 40
Question Id: 12252

Mark | Previous | Next | Full Screen | Tutorial | Lab Values | Notes | Calculator | Reverse Color | Text Zoom | Settings

A 55-year-old man comes to the clinic due to headache and progressive facial weakness. The patient's headaches began 2 months ago and are characterized as throbbing. They are typically worse in the morning and when he bears down or coughs. He has had no recent head trauma or loss of consciousness. The patient has a history of hypertension for which he takes lisinopril. He does not use tobacco, alcohol, or illicit drugs. Vital signs are normal. On physical examination, there is flattening of the left nasolabial fold and drooping of the left lower lip. The patient cannot fully close his left eye. MRI of the brain reveals a well-circumscribed homogenously enhancing mass in the posterior fossa that is compressing the left facial nerve root. Which of the following additional findings is most likely present on this patient's neurologic examination?

- A. "Down and out" eye deviation
- B. Hoarseness of voice
- C. Increased sensitivity to sound
- D. Loss of facial sensation
- E. Loss of hearing
- F. Loss of taste in posterior tongue
- G. Sensory loss in posterior tongue
- H. Tongue deviation to the left

Submit

Block Time Remaining: 00:01:02
TUTOR

2 | Feedback | Suspend | End Block

Settings

1 2 3 4 5 6 7 8 9 10 11 12 13 14 15 16 17 18 19 20 21 22 23 24 25 26 27 28 29 30

Item 31 of 40
Question Id: 12252

Mark | Previous | Next | Full Screen | Tutorial | Lab Values | Notes | Calculator | Reverse Color | Text Zoom | Settings

A 55-year-old man comes to the clinic due to headache and progressive facial weakness. The patient's headaches began 2 months ago and are characterized as throbbing. They are typically worse in the morning and when he bears down or coughs. He has had no recent head trauma or loss of consciousness. The patient has a history of hypertension for which he takes lisinopril. He does not use tobacco, alcohol, or illicit drugs. Vital signs are normal. On physical examination, there is flattening of the left nasolabial fold and drooping of the left lower lip. The patient cannot fully close his left eye. MRI of the brain reveals a well-circumscribed homogenously enhancing mass in the posterior fossa that is compressing the left facial nerve root. Which of the following additional findings is most likely present on this patient's neurologic examination?

- A. "Down and out" eye deviation (1%)
- B. Hoarseness of voice (0%)
- ✓ C. Increased sensitivity to sound (70%)
- D. Loss of facial sensation (5%)
- E. Loss of hearing (14%)
- F. Loss of taste in posterior tongue (3%)
- G. Sensory loss in posterior tongue (1%)
- H. Tongue deviation to the left (1%)

Omitted
Correct answer
C

70%
Answered correctly

02 secs
Time Spent

05/25/2020
Last Updated

Block Time Remaining: 00:01:04
TUTOR

2 | Feedback | Suspend | End Block

This patient has **facial nerve (CN VII) palsy**, likely due to nerve compression by a meningioma (eg, well-circumscribed, homogenously enhancing mass) in the posterior fossa. Space-occupying intracranial lesions classically present with a headache that is worse in the morning and with Valsalva (eg, bearing down, coughing) due to increased intracranial pressure.

The facial nerve exits the brainstem at the pontomedullary junction and subsequently enters the internal auditory meatus and facial canal in the temporal bone. Here, it gives off branches that supply the stapedius muscle (reduces volume by dampening ossicle movement in middle ear), salivary glands (eg, sublingual, submandibular), and lacrimal glands. It also provides taste from the anterior two thirds of the tongue via the chorda tympani nerve. After exiting the skull through the stylomastoid foramen, the facial nerve courses within the parotid gland and its terminal branches innervate the muscles of facial expression.

Facial nerve palsy presents with ipsilateral facial paralysis (eg, flattening of the nasolabial fold, drooping of the lower lip, inability to close the eye). There is also **loss of the corneal reflex** (efferent limb) due to denervation of the orbicularis oculi muscle. Paralysis of the stapedius muscle may lead to increased sensitivity to sound (**hyperacusis**). Since the nerve to the stapedius is one of the first branches of the facial nerve, hyperacusis indicates that the facial nerve is injured **near its brainstem origin**. Other features of facial nerve palsy include decreased lacrimation, salivation, and **loss of taste** in the **anterior two thirds** of the tongue.

(Choice A) Oculomotor nerve (CN III) palsy causes "down and out" eye deviation, ptosis (due to levator palpebrae superioris paralysis), and a fixed dilated pupil (due to parasympathetic fiber injury).

(Choice B) Vagus nerve (CN X) injury causes paralysis of the soft palate (eg, loss of efferent limb of the gag reflex), pharyngeal muscles (eg, dysphagia), and laryngeal muscles (eg, hoarseness). Sensory loss in the larynx and pharynx may also lead to impaired cough reflex.

(Choice D) Trigeminal nerve (CN V) damage causes ipsilateral facial anesthesia, loss of the corneal reflex (afferent limb), weakness of the muscles of mastication, and jaw deviation toward the side of the lesion (due to unopposed action of the opposite pterygoid muscle).

(Choice E) Vestibulocochlear nerve (CN VIII) injury (eg, due to vestibular schwannoma) causes sensorineural hearing loss, tinnitus, and vertigo.

(Choices F and G) Glossopharyngeal nerve (CN IX) damage causes loss of sensation and taste in the posterior one third of the tongue, and loss of the gag reflex (afferent limb).

(Choice H) Hypoglossal nerve (CN XII) injury causes tongue weakness and deviation toward the side of the lesion

Settings

Item 31 of 40
Question Id: 12252

Mark | Previous | Next | Full Screen | Tutorial | Lab Values | Notes | Calculator | Reverse Color | Text Zoom | Settings

Correct answer | Answered correctly | Time Spent | Last Updated

Exhibit Display

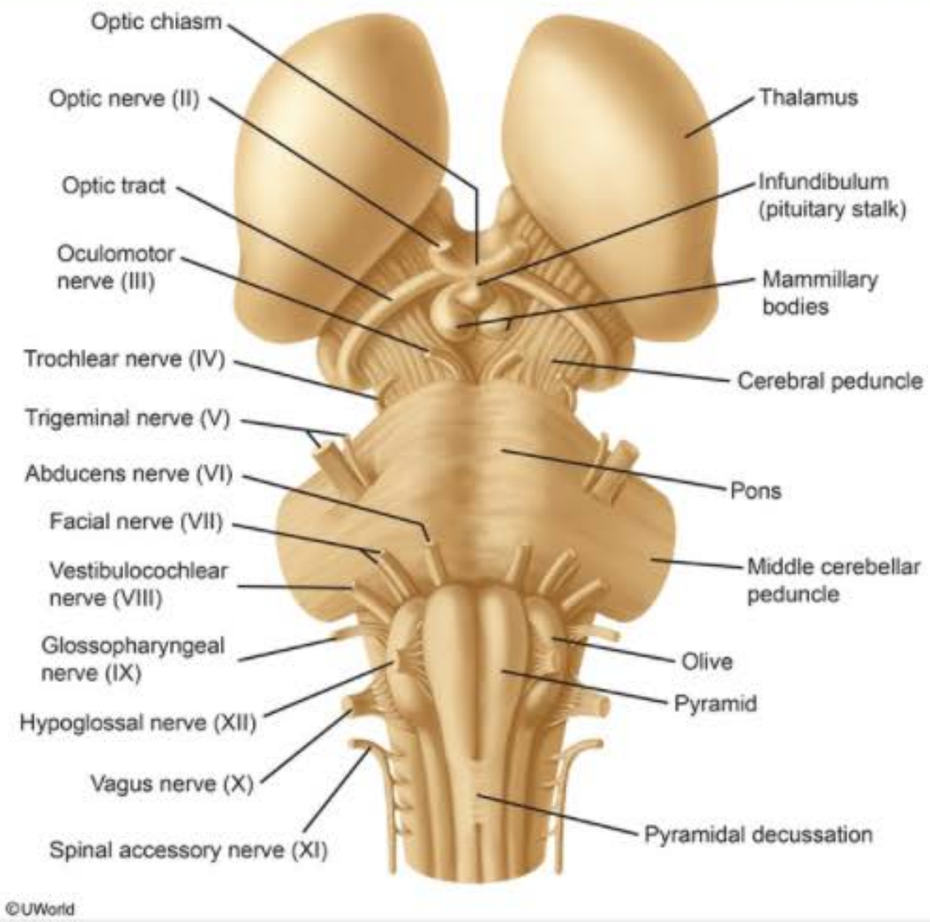

Zoom In | Zoom Out | Reset | Add To New Card | Existing Card

muscles of mastication, and jaw deviation toward the side of the lesion (due to unopposed action of the opposite pterygoid muscle).

Block Time Remaining: 00:01:04
TUTOR

2 | Feedback | Suspend | End Block

Settings

1 2 3 4 5 6 7 8 9 10 11 12 13 14 15 16 17 18 19 20 21 22 23 24 25 26 27 28 29 30

Item 31 of 40
Question Id: 12252

Mark | Previous | Next | Full Screen | Tutorial | Lab Values | Notes | Calculator | Reverse Color | Text Zoom | Settings

Explanation

Exhibit Display

Peripheral facial palsy

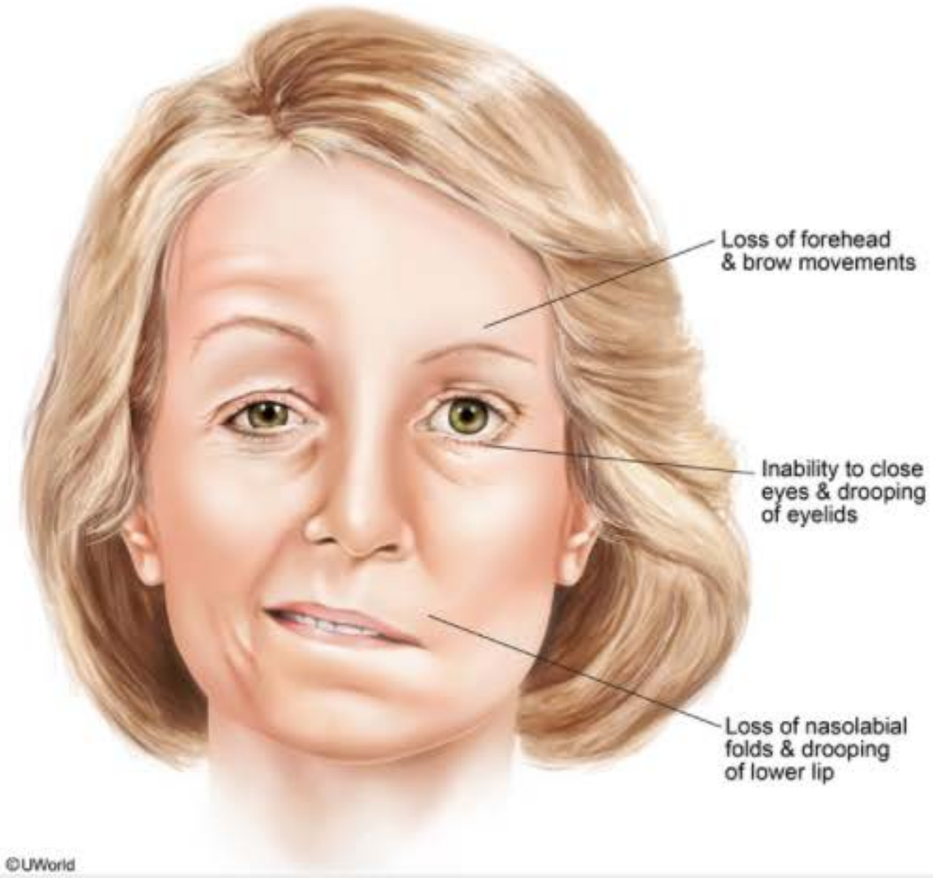

Zoom In | Zoom Out | Reset | Add To New Card | Existing Card

Block Time Remaining: 00:01:04
TUTOR

2 | Feedback | Suspend | End Block

indicates that the facial nerve is injured **near its brainstem origin**. Other features of facial nerve palsy include decreased lacrimation, salivation, and **loss of taste** in the **anterior two thirds** of the tongue.

(Choice A) Oculomotor nerve (CN III) palsy causes "down and out" eye deviation, ptosis (due to levator palpebrae superioris paralysis), and a fixed dilated pupil (due to parasympathetic fiber injury).

(Choice B) Vagus nerve (CN X) injury causes paralysis of the soft palate (eg, loss of efferent limb of the gag reflex), pharyngeal muscles (eg, dysphagia), and laryngeal muscles (eg, hoarseness). Sensory loss in the larynx and pharynx may also lead to impaired cough reflex.

(Choice D) Trigeminal nerve (CN V) damage causes ipsilateral facial anesthesia, loss of the corneal reflex (afferent limb), weakness of the muscles of mastication, and jaw deviation toward the side of the lesion (due to unopposed action of the opposite pterygoid muscle).

(Choice E) Vestibulocochlear nerve (CN VIII) injury (eg, due to vestibular schwannoma) causes sensorineural hearing loss, tinnitus, and vertigo.

(Choices F and G) Glossopharyngeal nerve (CN IX) damage causes loss of sensation and taste in the posterior one third of the tongue, and loss of the gag reflex (afferent limb).

(Choice H) Hypoglossal nerve (CN XII) injury causes tongue weakness and deviation toward the side of the lesion.

Educational objective:
Hyperacusis (increased sensitivity to sound) is an indication of damage to the facial nerve (CN VII) close to its origin from the brainstem.

References

- Hyperacusis.
- Seventh cranial neuropathy.

Pathology	Nervous System	Facial nerve
Subject	System	Topic

Copyright © UWorld. All rights reserved.

Settings

1 2 3 4 5 6 7 8 9 10 11 12 13 14 15 16 17 18 19 20 21 22 23 24 25 26 27 28 29 30

Item 32 of 40
Question Id: 12175

Mark | Previous | Next | Full Screen | Tutorial | Lab Values | Notes | Calculator | Reverse Color | Text Zoom | Settings

A 28-year-old woman with a history of type 1 diabetes mellitus comes to the hospital due to abdominal pain, nausea, and vomiting. She is found to have severe hyperglycemia, high anion gap metabolic acidosis, and an elevated beta-hydroxybutyrate level. While being evaluated in the emergency department, the patient develops involuntary, rhythmic jerking of her right upper extremity that lasts for about a minute. She remains fully alert during and after the event. The patient has never had similar symptoms in the past and has no other medical conditions. Physical examination shows no weakness or sensory loss in the right upper extremity. Which of the following is the most likely diagnosis?

- A. Acute dystonia
- B. Focal onset seizure
- C. Generalized absence seizure
- D. Generalized tonic-clonic seizure
- E. Hemiballism
- F. Tic disorder

Submit

Block Time Remaining: 00:01:04
TUTOR

3 | Feedback | Suspend | End Block

A 28-year-old woman with a history of type 1 diabetes mellitus comes to the hospital due to abdominal pain, nausea, and vomiting. She is found to have severe hyperglycemia, high anion gap metabolic acidosis, and an elevated beta-hydroxybutyrate level. While being evaluated in the emergency department, the patient develops involuntary, rhythmic jerking of her right upper extremity that lasts for about a minute. She remains fully alert during and after the event. The patient has never had similar symptoms in the past and has no other medical conditions. Physical examination shows no weakness or sensory loss in the right upper extremity. Which of the following is the most likely diagnosis?

- A. Acute dystonia (7%)
- ✓ B. Focal onset seizure (74%)
- C. Generalized absence seizure (0%)
- D. Generalized tonic-clonic seizure (1%)
- E. Hemiballism (15%)
- F. Tic disorder (1%)

Omitted
Correct answer
B

74%
Answered correctly

01 sec
Time Spent

03/10/2020
Last Updated

Explanation

Seizure type	Description	Preferred anticonvulsants

Seizure type	Description	Preferred anticonvulsants
Focal onset (involves a single cerebral hemisphere at onset)		
Aware	• No loss of consciousness or postictal state • Motor, sensory, autonomic, or cognitive symptoms	• Carbamazepine* • Lamotrigine • Levetiracetam • Phenytoin*
Impaired awareness	• Appears awake but consciousness is altered (eg, blank stare) • Postictal state • May have automatisms (eg, lip smacking)	
Generalized onset (involves both hemispheres at onset)		
Tonic-clonic	• Loss of consciousness & postictal state • Diffuse muscle contraction of limbs (tonic) followed by rhythmic jerking (clonic)	• Levetiracetam • Valproic acid
Myoclonic	• No loss of consciousness or postictal state • Brief jerking movements	
Absence	• Brief episodes of altered consciousness (eg, blank stare) • May have automatisms • Usually no postictal state	• Ethosuxamide • Valproic acid

*Narrow-spectrum agents can also treat focal-onset seizures that evolve into bilateral tonic-clonic seizures.

This patient with abdominal pain, vomiting, hyperglycemia, anion gap metabolic acidosis, and elevated beta-hydroxybutyrate has diabetic ketoacidosis. **Metabolic derangements** (eg, hyperglycemia, acidosis) in patients with **diabetic ketoacidosis** may cause neurologic dysfunction manifesting as altered mental status, focal neurologic deficits, and/or seizure.

This patient with abdominal pain, vomiting, hyperglycemia, anion gap metabolic acidosis, and elevated beta-hydroxybutyrate has diabetic ketoacidosis. **Metabolic derangements** (eg, hyperglycemia, acidosis) in patients with **diabetic ketoacidosis** may cause neurologic dysfunction manifesting as altered mental status, focal neurologic deficits, and/or seizure.

Seizures occur due to abnormal, synchronous discharges of neurons in the cerebral cortex. They are classified as either **focal onset** (previously known as partial) if they originate from a localized region of **one cerebral hemisphere** or generalized if they involve both hemispheres at onset. Focal seizures can be subclassified based on level of consciousness:

- Focal seizures with retained awareness (previously known as simple partial): Patients remain awake and interactive.
- Focal seizures with impaired awareness (previously known as complex partial): Patients appear awake but do not interact appropriately (eg, blank stare). Postictal state (eg, confusion, sedation) is common.

The manifestations of focal seizure depend on the brain region in which the seizure activity is occurring. This patient's episodic right upper limb rhythmic jerking suggests a **focal seizure with retained awareness** originating in the contralateral motor cortex.

(Choice A) Acute dystonia is a sustained, involuntary muscle contraction with abnormal posturing (eg, torticollis); it often occurs after exposure to dopamine antagonists (eg, haloperidol). Rhythmic jerking is more consistent with seizure activity.

(Choice C) Generalized absence seizure involves both hemispheres at onset and presents as a brief (<10 sec) staring spell with impaired consciousness. It typically occurs in children, and patients may have hundreds of episodes a day.

(Choice D) Generalized tonic-clonic seizure is characterized by loss of consciousness with diffuse, bilateral muscle contractions of the limbs followed by rhythmic jerking. Associated features may include tongue biting and urinary/bowel incontinence.

(Choice E) Hemiballism is characterized by involuntary, unilateral, nonrhythmic, wide-amplitude movements of the extremities (eg, arm flailing). It often occurs with Huntington chorea, an autosomal dominant disease that also causes psychiatric symptoms and dementia.

(Choice F) Motor tics are sudden, brief movements that may include arm jerking but are characterized by an overwhelming urge to perform the movement followed by feelings of relief. They can be voluntarily suppressed for brief periods.

Educational objective:

This patient with abdominal pain, vomiting, hyperglycemia, anion gap metabolic acidosis, and elevated beta-hydroxybutyrate has diabetic ketoacidosis. **Metabolic** tion manifesting as altered m

Seizures occur due to a usly known as partial) if they et. Focal seizures can be su

- Focal seizures wit
- Focal seizures wit (eg, blank stare). Post

The manifestations of fo nb rhythmic jerking suggest

(Choice A) Acute dysto re to dopamine antagonists (e

(Choice C) Generalized consciousness. It typica

(Choice D) Generalized followed by rhythmic jerk

(Choice E) Hemiballism g). It often occurs with Hunting

(Choice F) Motor tics a he movement followed by fe

Educational objective:

Exhibit Display

Anion gap metabolic acidosis	
Calculation	Anion gap = sodium – (chloride + bicarbonate) (Normal: 10-14)
Common causes Mnemonic: MUDPILES	• Methanol • Uremia • Diabetic ketoacidosis • Propylene glycol/paraldehyde • Isoniazid/iron • Lactic acidosis • Ethylene glycol (antifreeze) • Salicylates (aspirin)

Add To New Card | Existing Card

The manifestations of focal seizure depend on the brain region in which the seizure activity is occurring. This patient's episodic right upper limb rhythmic jerking suggests a **focal seizure with retained awareness** originating in the contralateral motor cortex.

(Choice A) Acute dystonia is a sustained, involuntary muscle contraction with abnormal posturing (eg, torticollis); it often occurs after exposure to dopamine antagonists (eg, haloperidol). Rhythmic jerking is more consistent with seizure activity.

(Choice C) Generalized absence seizure involves both hemispheres at onset and presents as a brief (<10 sec) staring spell with impaired consciousness. It typically occurs in children, and patients may have hundreds of episodes a day.

(Choice D) Generalized tonic-clonic seizure is characterized by loss of consciousness with diffuse, bilateral muscle contractions of the limbs followed by rhythmic jerking. Associated features may include tongue biting and urinary/bowel incontinence.

(Choice E) Hemiballism is characterized by involuntary, unilateral, nonrhythmic, wide-amplitude movements of the extremities (eg, arm flailing). It often occurs with Huntington chorea, an autosomal dominant disease that also causes psychiatric symptoms and dementia.

(Choice F) Motor tics are sudden, brief movements that may include arm jerking but are characterized by an overwhelming urge to perform the movement followed by feelings of relief. They can be voluntarily suppressed for brief periods.

Educational objective:
Seizures are classified as either focal onset if they originate from a localized region of one cerebral hemisphere or generalized if they involve both hemispheres at onset. Focal seizures can be subclassified as retained awareness (patients remain interactive) or impaired awareness (patients appear awake but do not interact appropriately). Manifestations of focal seizure depend on the brain region in which the seizure activity occurs.

References

- The 2010 revised classification of seizures and epilepsy.

Pathology	Nervous System	Seizures
Subject	System	Topic

Copyright © UWorld. All rights reserved.

A 32-year-old woman comes to the office due to left eye pain that is accentuated by ocular movements. She also has periodic dimming of vision in the same eye. The patient has had several such episodes over the last month, most often after a hot shower or intense workout. A year ago, she had an episode of numbness and tingling in her left arm that resolved spontaneously. The patient has no other medical issues and takes no medication. She smokes half a pack of cigarettes a day and does not use alcohol or illicit drugs. Vital signs are normal. BMI is 26 kg/m^2. Ophthalmologic examination shows swelling of the optic disc on the left. Neurologic examination shows a mild intention tremor and broad-based gait. Which of the following is the most likely cause of the patient's current condition?

- A. Atherosclerosis of the carotid arteries
- B. Brain metastasis
- C. Demyelinating plaques
- D. Increased red blood cell mass
- E. *Treponema pallidum* infection
- F. Vitamin B_{12} deficiency

Submit

1 2 3 4 5 6 7 8 9 10 11 12 13 14 15 16 17 18 19 20 21 22 23 24 25 26 27 28 29 30

A 32-year-old woman comes to the office due to left eye pain that is accentuated by ocular movements. She also has periodic dimming of vision in the same eye. The patient has had several such episodes over the last month, most often after a hot shower or intense workout. A year ago, she had an episode of numbness and tingling in her left arm that resolved spontaneously. The patient has no other medical issues and takes no medication. She smokes half a pack of cigarettes a day and does not use alcohol or illicit drugs. Vital signs are normal. BMI is 26 kg/m^2. Ophthalmologic examination shows swelling of the optic disc on the left. Neurologic examination shows a mild intention tremor and broad-based gait. Which of the following is the most likely cause of the patient's current condition?

- A. Atherosclerosis of the carotid arteries (3%)
- B. Brain metastasis (1%)
- ✓ C. Demyelinating plaques (81%)
- D. Increased red blood cell mass (10%)
- E. *Treponema pallidum* infection (1%)
- F. Vitamin B_{12} deficiency (1%)

Omitted
Correct answer
C

81%
Answered correctly

01 sec
Time Spent

02/23/2020
Last Updated

Explanation

Multiple sclerosis

Multiple sclerosis	
Common presenting symptoms	• Sensory disturbances, motor weakness, bowel/bladder dysfunction • Ocular manifestations: Optic neuritis (painful eye movement), internuclear ophthalmoplegia (impaired adduction on lateral gaze) • Lhermitte sign: Electrical sensation in limbs or back • Uhthoff phenomenon: Symptom worsening with increased body temperature
Risk factors	• Female, Caucasian, *HLA-DRB1* • Environmental factors: Location (USA, Europe), cold climate • Low vitamin D levels • Smoking
Diagnosis	• Episodic/progressive symptoms disseminated over time & space • Hyperintense lesions on T2-weighted MRI • Oligoclonal IgG bands on cerebrospinal fluid analysis

This patient has eye pain worsened with movement, intermittently decreased vision, and swelling of the optic disc, consistent with **optic neuritis**. In a young female patient, optic neuritis should raise concern for **multiple sclerosis** (MS), a chronic immune-mediated disease that affects the central nervous system (CNS) and leads to oligodendrocyte destruction. Demyelinating plaques are commonly seen as hyperintense lesions on T2- weighted MRI of the brain and spinal cord.

MS is characterized by episodic, progressive neurologic deficits that may involve multiple anatomic regions within the CNS (ie, **separated in space and time**). In addition to optic neuritis, other manifestations of MS include sensory/motor symptoms (eg, arm numbness and tingling), internuclear ophthalmoplegia, cerebellar dysfunction (eg, intention tremor, broad-based gait), fatigue, and Lhermitte sign (electrical sensations down the back/limbs with neck flexion). Symptom worsening can occur with increased body temperature (eg, exercise, bathing) due to slowing of neuronal conduction in unmyelinated nerves (Uhthoff phenomenon).

Settings

Item 33 of 40
Question Id: 916

Mark | Previous | Next | Full Screen | Tutorial | Lab Values | Notes | Calculator | Reverse Color | Text Zoom | Settings

Multiple sclerosis

Exhibit Display

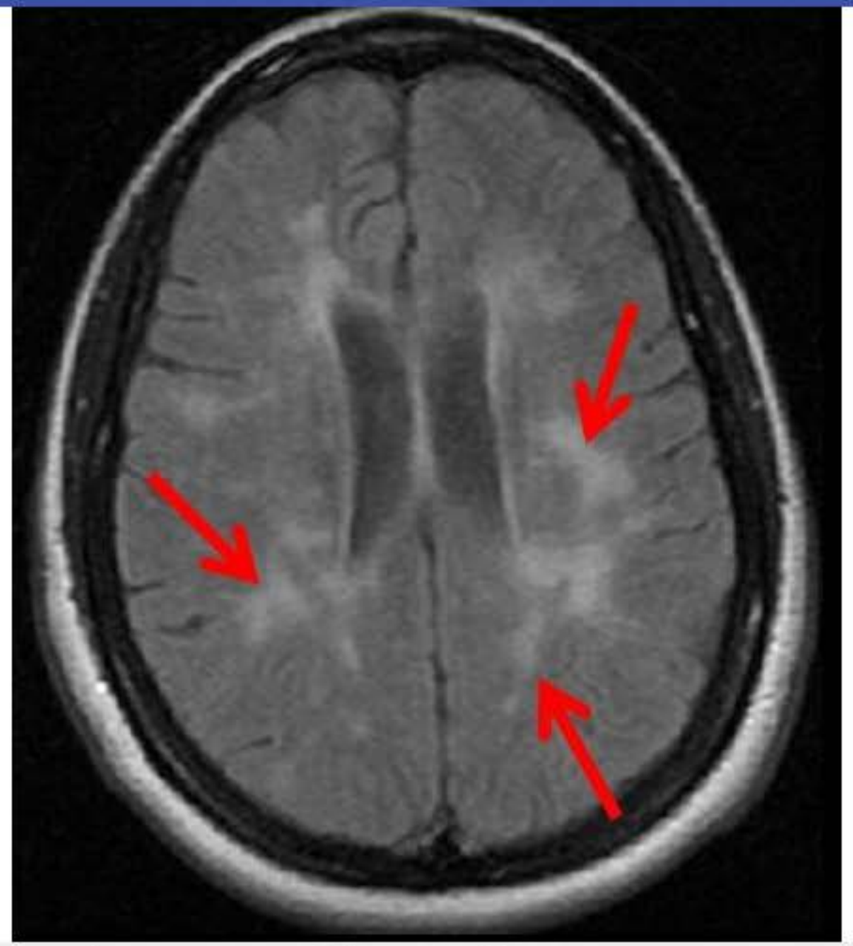

Zoom In | Zoom Out | Reset | Add To New Card | Existing Card

would not typically cause eye pain or worsening symptoms with body heat, and would be rare in a young patient without other signs of

Block Time Remaining: 00:01:08
TUTOR

4 | Feedback | Suspend | End Block

MS is characterized by episodic, progressive neurologic deficits that may involve multiple anatomic regions within the CNS (ie, **separated in space and time**). In addition to optic neuritis, other manifestations of MS include sensory/motor symptoms (eg, arm numbness and tingling), internuclear ophthalmoplegia, cerebellar dysfunction (eg, intention tremor, broad-based gait), fatigue, and Lhermitte sign (electrical sensations down the back/limbs with neck flexion). Symptom worsening can occur with increased body temperature (eg, exercise, bathing) due to slowing of neuronal conduction in unmyelinated nerves (Uhthoff phenomenon).

(Choice A) Atherosclerosis of the carotid arteries can cause transient ischemia leading to episodic vision loss (amaurosis fugax). However, it would not typically cause eye pain or worsening symptoms with body heat, and would be rare in a young patient without other signs of atherosclerosis.

(Choice B) Brain metastases can cause a variety of neurologic symptoms (eg, cerebellar signs, vision changes) but would be expected to worsen with time, not relapse and remit.

(Choice D) Polycythemia vera can cause transient visual disturbances and other neurologic manifestations due to increased blood viscosity. Although patients may have pruritus or erythema following heat exposure, heat does not worsen neurologic symptoms. Also, this patient does not have other polycythemic manifestations (eg, hypertension, facial plethora).

(Choice E) Neurosyphilis can cause a wide-based gait and pupillary irregularities (Argyll Robertson pupil; ie, accommodates but does not react to light), but there is no pain with eye movement or vision loss. In addition, heat sensitivity and upper extremity weakness would be unexpected.

(Choice F) Vitamin B_{12} deficiency causes subacute combined degeneration, and patients can develop a broad-based gait. However, in most cases this is slowly progressive and often accompanied by paresthesias in the distal lower extremities. Intention tremor and optic neuritis are not associated with vitamin B_{12} deficiency.

Educational objective:
Multiple sclerosis is characterized by episodic, progressive neurologic deficits involving multiple anatomic regions within the central nervous system. Demyelinating plaques are commonly seen as hyperintense lesions on T2-weighted MRI of the brain and spinal cord. Common manifestations include optic neuritis, internuclear ophthalmoplegia, sensory deficits, and fatigue, which may worsen with heat exposure.

References

would not typically cause eye pain or worsening symptoms with body heat, and would be rare in a young patient without other signs of atherosclerosis.

(Choice B) Brain metastases can cause a variety of neurologic symptoms (eg, cerebellar signs, vision changes) but would be expected to worsen with time, not relapse and remit.

(Choice D) Polycythemia vera can cause transient visual disturbances and other neurologic manifestations due to increased blood viscosity. Although patients may have pruritus or erythema following heat exposure, heat does not worsen neurologic symptoms. Also, this patient does not have other polycythemic manifestations (eg, hypertension, facial plethora).

(Choice E) Neurosyphilis can cause a wide-based gait and pupillary irregularities (Argyll Robertson pupil; ie, accommodates but does not react to light), but there is no pain with eye movement or vision loss. In addition, heat sensitivity and upper extremity weakness would be unexpected.

(Choice F) Vitamin B_{12} deficiency causes subacute combined degeneration, and patients can develop a broad-based gait. However, in most cases this is slowly progressive and often accompanied by paresthesias in the distal lower extremities. Intention tremor and optic neuritis are not associated with vitamin B_{12} deficiency.

Educational objective:
Multiple sclerosis is characterized by episodic, progressive neurologic deficits involving multiple anatomic regions within the central nervous system. Demyelinating plaques are commonly seen as hyperintense lesions on T2-weighted MRI of the brain and spinal cord. Common manifestations include optic neuritis, internuclear ophthalmoplegia, sensory deficits, and fatigue, which may worsen with heat exposure.

References

- Advances in the immunopathogenesis of multiple sclerosis.

Pathology	Nervous System	Multiple sclerosis
Subject	System	Topic

Copyright © UWorld. All rights reserved.

Settings

1 2 3 4 5 6 7 8 9 10 11 12 13 14 15 16 17 18 19 20 21 22 23 24 25 26 27 28 29 30

Item 34 of 40
Question Id: 20

Mark | Previous | Next | Full Screen | Tutorial | Lab Values | Notes | Calculator | Reverse Color | Text Zoom | Settings

A 56-year-old man dies in the hospital due to aspiration-related complications. The patient was admitted 5 days ago with right-sided weakness, sensory loss, and difficulty with speech and swallowing. CT scan revealed an area of hypodensity in the left frontoparietal region. Autopsy examination is performed, and a section of loose, spongy tissue from the abnormal brain area is obtained. Histologic findings after staining for lipids are shown below.

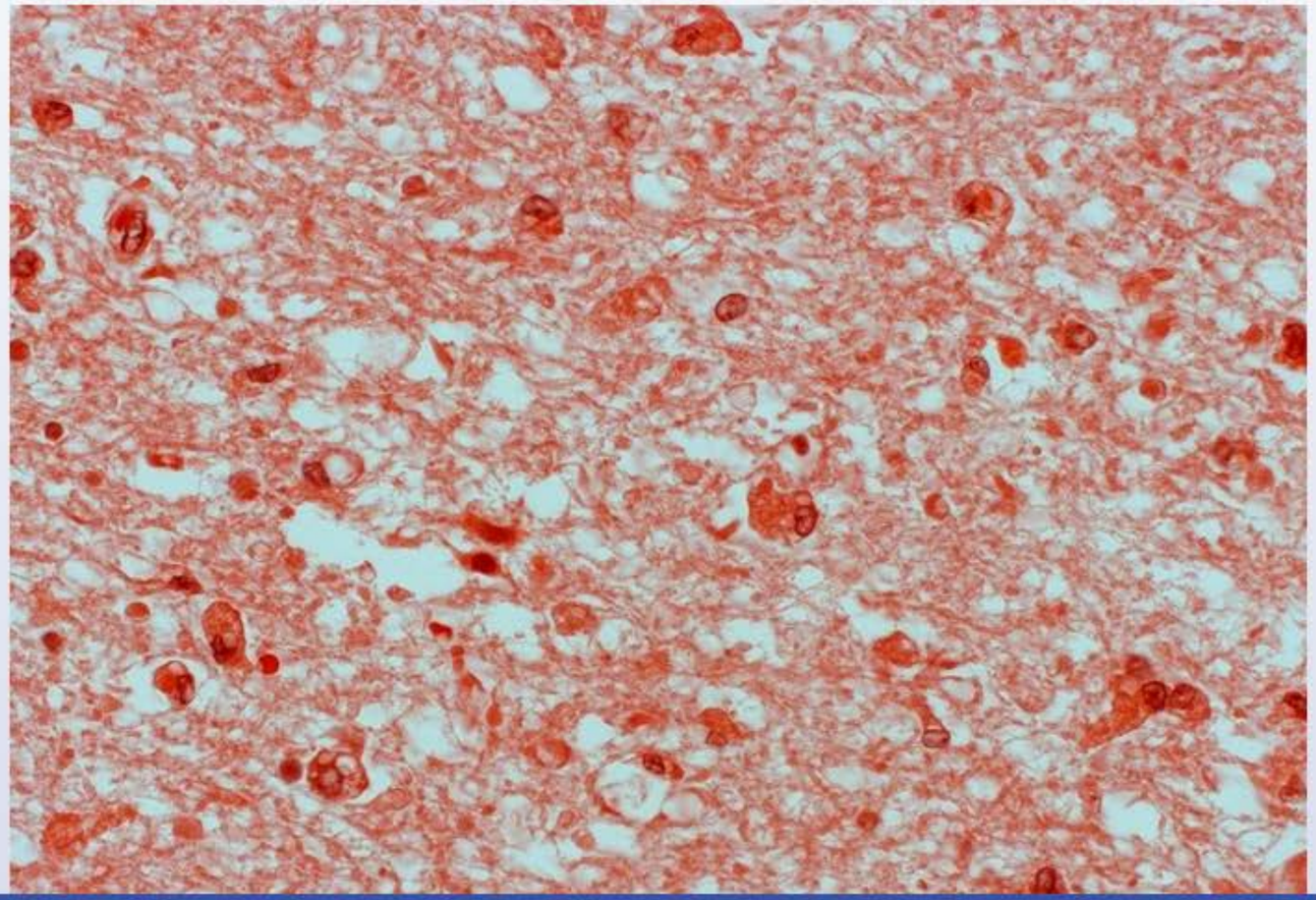

Block Time Remaining: 00:01:09
TUTOR

4 | Feedback | Suspend | End Block

Settings

1 2 3 4 5 6 7 8 9 10 11 12 13 14 15 16 17 18 19 20 21 22 23 24 25 26 27 28 29 30

Item 34 of 40
Question Id: 20

Mark | Previous | Next | Full Screen | Tutorial | Lab Values | Notes | Calculator | Reverse Color | Text Zoom | Settings

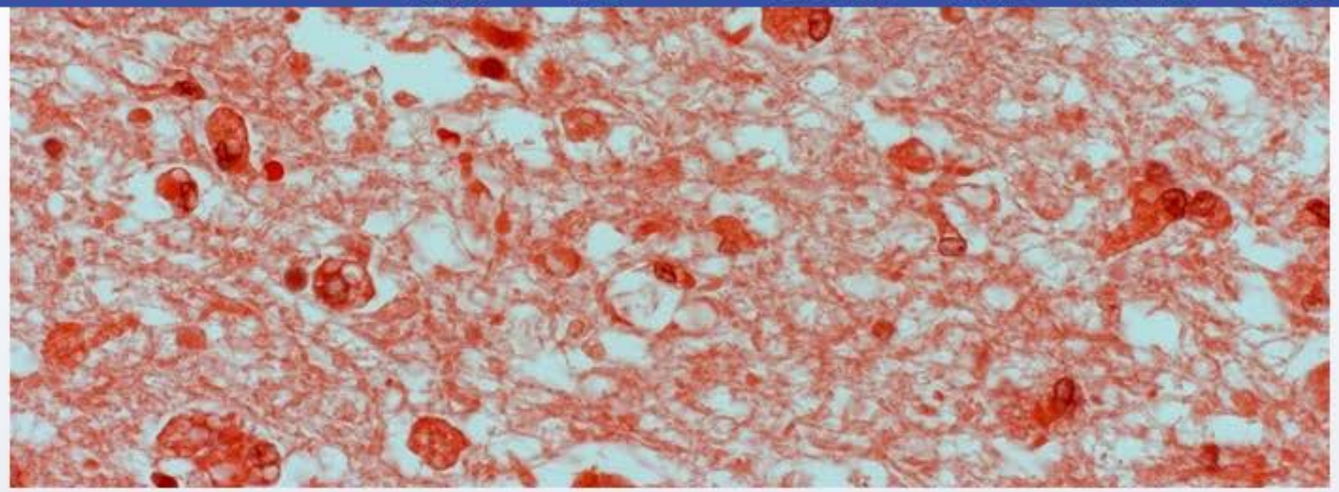

The cells most intensely stained in this patient's brain specimen represent which of the following cell types?

A. Astrocytes
B. Ependymal cells
C. Fibroblasts
D. Microglial cells
E. Neutrophils
F. Schwann cells

Submit

Block Time Remaining: 00:01:11
TUTOR

4 | Feedback | Suspend | End Block

Settings

1 2 3 4 5 6 7 8 9 10 11 12 13 14 15 16 17 18 19 20 21 22 23 24 25 26 27 28 29 30

Item 34 of 40
Question Id: 20

Mark | Previous | Next | Full Screen | Tutorial | Lab Values | Notes | Calculator | Reverse Color | Text Zoom | Settings

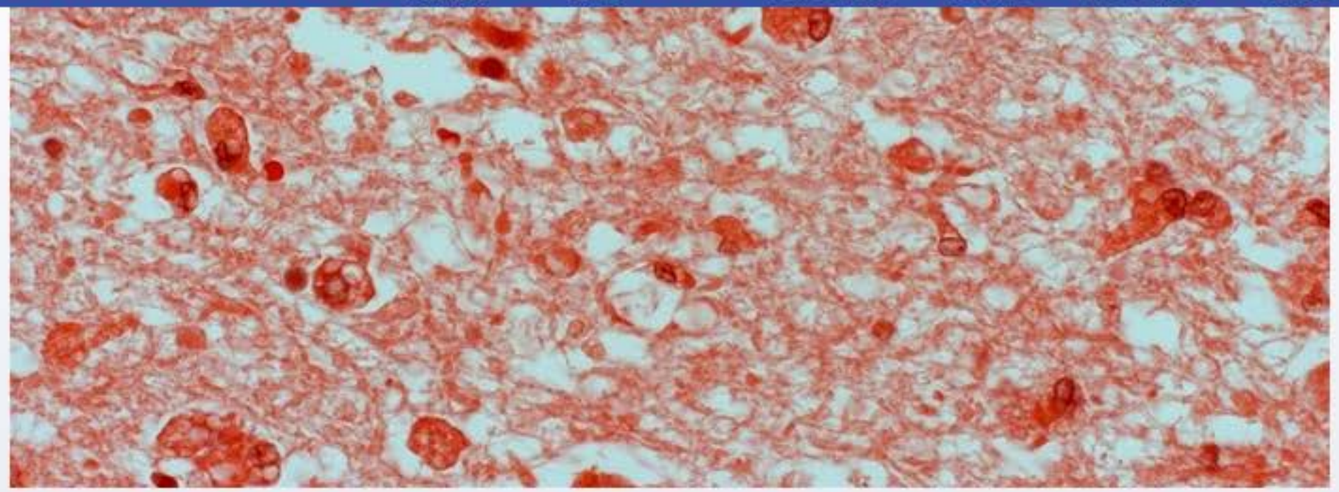

The cells most intensely stained in this patient's brain specimen represent which of the following cell types?

- A. Astrocytes (25%)
- B. Ependymal cells (3%)
- C. Fibroblasts (1%)
- ✓ D. Microglial cells (61%)
- E. Neutrophils (3%)
- F. Schwann cells (5%)

Omitted
Correct answer

61%
Answered correctly

04 secs
Time Spent

07/04/2020
Last Updated

Block Time Remaining: 00:01:12
TUTOR

4 | Feedback | Suspend | End Block

1 2 3 4 5 6 7 8 9 10 11 12 13 14 15 16 17 18 19 20 21 22 23 24 25 26 27 28 29 30

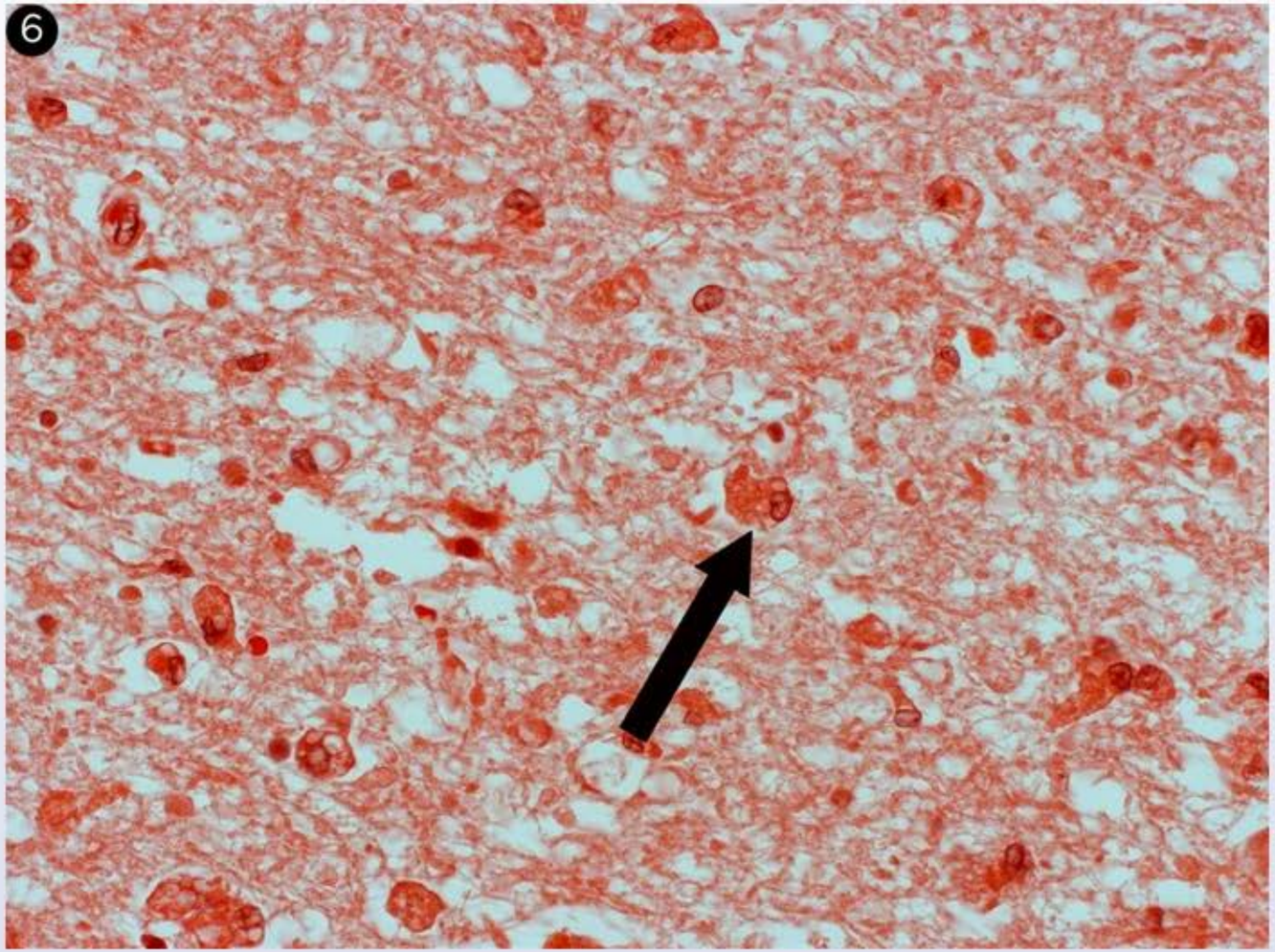

This patient developed acute-onset neurologic defects (eg, hemiparesis, dysphagia, dysarthria) secondary to an ischemic stroke, which was confirmed by CT scan and autopsy findings. An **ischemic infarct** results from regional hypoperfusion (eg, thrombosis, embolism) or a global

This patient developed acute-onset neurologic defects (eg, hemiparesis, dysphagia, dysarthria) secondary to an ischemic stroke, which was confirmed by CT scan and autopsy findings. An **ischemic infarct** results from regional hypoperfusion (eg, thrombosis, embolism) or a global decline in cerebral blood flow. Characteristic CT findings are evident 6-12 hours after the onset of ischemic injury and include hypoattenuation of the tissue and loss of grey-white matter differentiation within the affected region.

Microscopically, neurons in the necrotic area display signs of irreversible damage during the first 24 hours after injury (red neurons). Neutrophils initially move into the area in the first 1-2 days, followed by **microglia** (derived from yolk-sac monocytes) 3-7 days after the onset of ischemia. As the neurons disintegrate, their fragments are phagocytized by microglia, and myelin breakdown products **accumulate** in the cytoplasm of microglia as **foamy lipids**. Infiltration of the brain tissue by microglia (arrow) is seen on light microscopy in the photo and is consistent with the expected histology findings 5 days post-infarction.

(Choices A and C) In peripheral tissues, fibroblasts migrate to the area of injury to participate in tissue repair. However, in the central nervous system, repair is instead performed by astrocytes that migrate to the area of necrosis within 2 weeks of injury to begin forming a glial scar.

(Choices B and F) Although both ependymal cells and Schwann cells process lipids and would be prominent on lipid stain, neither type of cell participates in central nervous system repair after ischemic infarction.

(Choice E) Neutrophils are the predominant type of inflammatory cell 1-2 days after cerebral infarction and release inflammatory mediators that contribute to the hydrolysis of cells in liquefactive necrosis. They would not be prominent on lipid stain.

Educational objective:
Microglia are the predominant cell in the necrotic area 3-7 days after the onset of ischemia and phagocytize the fragments of neurons, myelin, and necrotic debris.

Pathology	Nervous System	Ischemic stroke
Subject	System	Topic

Copyright © UWorld. All rights reserved.

A 75-year-old man is brought to the emergency department due to 2 hours of left-sided chest pain and dyspnea. The patient has lived in a skilled nursing facility since developing right-sided hemiplegia, hemi-sensory loss, and aphasia 4 months ago. He has a history of diabetes mellitus, hypertension, and hypercholesterolemia. As an ECG is being obtained, the patient develops ventricular fibrillation and dies despite resuscitative efforts. An autopsy is performed; a coronal section of the brain is shown in the image below.

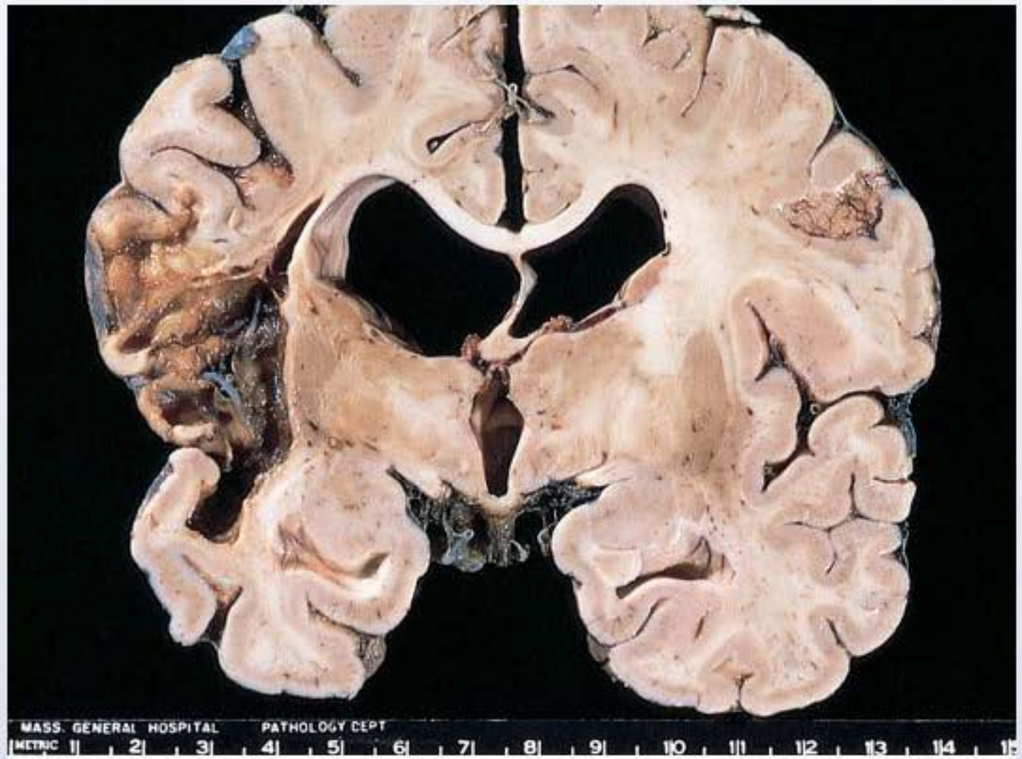

Displayed with permission from Springer Healthcare Ltd. © Copyright 2002 by Current Medicine

The walls of the brain lesion are most likely composed of which of the following?

Settings

1 2 3 4 5 6 7 8 9 10 11 12 13 14 15 16 17 18 19 20 21 22 23 24 25 26 27 28 29 30

Item 35 of 40
Question Id: 501

Mark | Previous | Next | Full Screen | Tutorial | Lab Values | Notes | Calculator | Reverse Color | Text Zoom | Settings

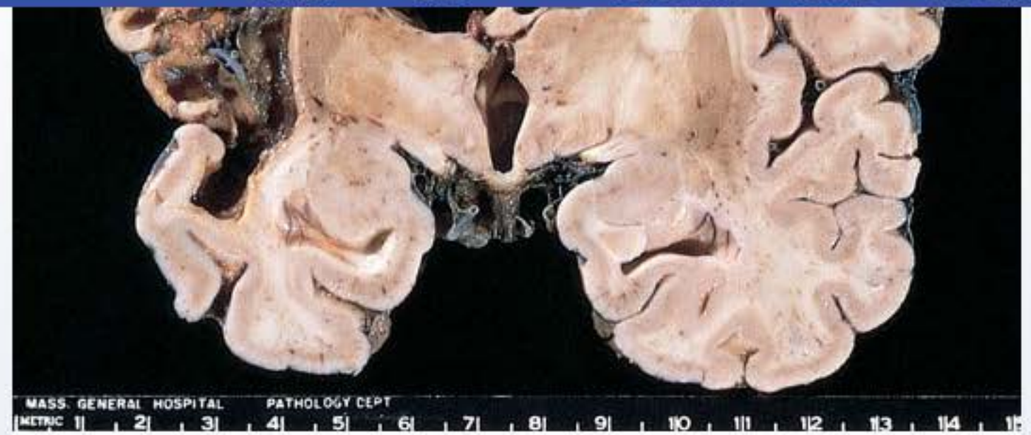

Displayed with permission from Springer Healthcare Ltd. © Copyright 2002 by Current Medicine

The walls of the brain lesion are most likely composed of which of the following?

- A. Astrocytes
- B. Ependymal cells
- C. Fibroblasts
- D. Oligodendrocytes
- E. Pia mater
- F. Schwann cells

Submit

Block Time Remaining: 00:01:14
TUTOR

2 | Feedback | Suspend | End Block

Settings

Item 35 of 40
Question Id: 501

Mark | Previous | Next | Full Screen | Tutorial | Lab Values | Notes | Calculator | Reverse Color | Text Zoom | Settings

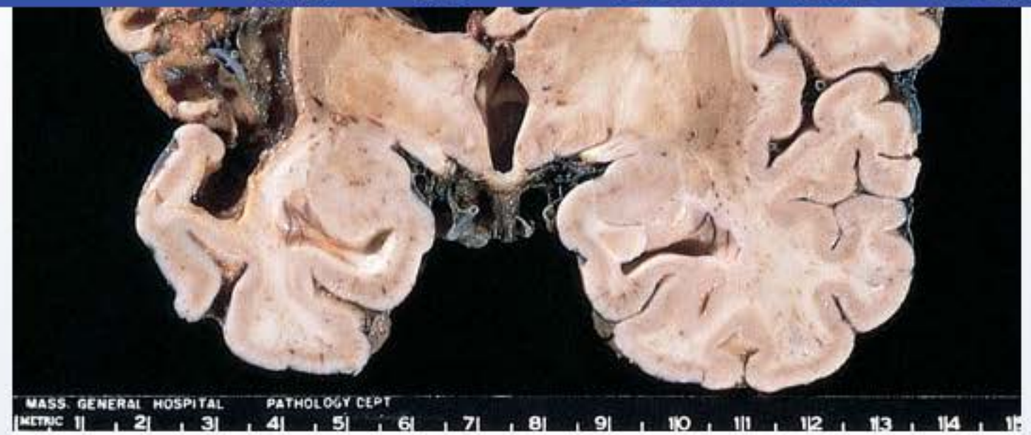

Displayed with permission from Springer Healthcare Ltd. © Copyright 2002 by Current Medicine

The walls of the brain lesion are most likely composed of which of the following?

- A. Astrocytes (70%)
- B. Ependymal cells (3%)
- C. Fibroblasts (13%)
- D. Oligodendrocytes (8%)
- E. Pia mater (3%)
- F. Schwann cells (0%)

Omitted
Correct answer

70%
Answered correctly

03 secs
Time Spent

03/01/2020
Last Updated

Block Time Remaining: 00:01:15
TUTOR

Feedback | Suspend | End Block

Ischemic stroke		
Time after injury	**Microscopic changes**	**Macroscopic changes**
12-24 hours	Red neurons (eosinophilic cytoplasm, pyknotic nuclei, loss of Nissl substance)	
24-72 hours	Neutrophilic infiltration	
3-7 days	Macrophage/microglia infiltration & phagocytosis begins	
1-2 weeks	Reactive gliosis & vascular proliferation around the necrotic area	Liquefactive necrosis (1 week-1 month)
>2 weeks	Glial scar formation	Cystic area surrounded by dense glial fibers (>1 month)

The coronal section of this patient's brain shows a cystic lesion caused by **ischemic stroke** involving the left cerebral hemisphere (eg, cortex, subcortical white matter, putamen). Neuropathology coronal sections are oriented with the right side of the brain on the examiner's right side.

Thrombosis of atherosclerotic plaques involving the cerebral arteries can result in vessel occlusion with tissue hypoxia and subsequent necrosis. Ischemic neuronal injury initially causes intense cytoplasmic eosinophilia ("red neurons") followed by neutrophil infiltration a day later. After several days, macrophages/microglia are recruited to phagocytize the necrotic debris and predominate in the ensuing 2-3 weeks. Around this time, the periphery of the necrotic area becomes populated with new blood vessels and proliferating astrocytes that form a network of cytoplasmic extensions (reactive gliosis). Several **months to years** after brain infarction, the necrotic area appears as a **cystic cavity** surrounded by a wall composed of dense fibers formed by **astrocytic processes** (glial scar).

(Choice B) Ependymal cells are ciliated glial cells that line the ventricles and central canal of the central nervous system and make up the choroid plexus. These cells produce cerebrospinal fluid but do not directly participate in glial scar formation around old infarcts.

Thrombosis of atherosclerotic plaques involving the cerebral arteries can result in vessel occlusion with tissue hypoxia and subsequent necrosis. Ischemic neuronal injury initially causes intense cytoplasmic eosinophilia ("red neurons") followed by neutrophil infiltration a day later. After several days, macrophages/microglia are recruited to phagocytize the necrotic debris and predominate in the ensuing 2-3 weeks. Around this time, the periphery of the necrotic area becomes populated with new blood vessels and proliferating astrocytes that form a network of cytoplasmic extensions (reactive gliosis). Several **months to years** after brain infarction, the necrotic area appears as a **cystic cavity** surrounded by a wall composed of dense fibers formed by **astrocytic processes** (glial scar).

(Choice B) Ependymal cells are ciliated glial cells that line the ventricles and central canal of the central nervous system and make up the choroid plexus. These cells produce cerebrospinal fluid but do not directly participate in glial scar formation around old infarcts.

(Choice C) Large ischemic strokes may result in perivascular fibroblast infiltration with fibrotic scar formation within the core of the lesion. However, this region remains separated from normal brain parenchyma by a wall of reactive gliosis, which protects viable neuronal tissue from being damaged by the fibrotic inflammatory response.

(Choice D) Oligodendrocytes are the myelin-producing cells of the central nervous system and do not directly participate in glial scar formation around old infarcts.

(Choice E) The meninges (eg, pia mater) are separated from the cystic cavity created after ischemic stroke by a gliotic tissue layer (derived from the cortex) and do not participate in glial scar formation.

(Choice F) Schwann cells are myelin-producing cells that help guide axonal repair and regeneration in the peripheral nervous system.

Educational objective:
Several months to years after ischemic brain infarction, the necrotic area appears as a cystic cavity surrounded by a wall composed of dense fibers formed by astrocytic processes (glial scar).

References

- Glial scar formation occurs in the human brain after ischemic stroke.
- Role of the lesion scar in the response to damage and repair of the central nervous system.

Settings

1 2 3 4 5 6 7 8 9 10 11 12 13 14 15 16 17 18 19 20 21 22 23 24 25 26 27 28 29 30

Item 36 of 40
Question Id: 347

Mark | Previous | Next | Full Screen | Tutorial | Lab Values | Notes | Calculator | Reverse Color | Text Zoom | Settings

A 1-month-old, full-term boy is brought to the emergency department by his mother due to difficulty awakening him. The mother says that the infant was left alone for a few minutes this morning and rolled off a bed. Since then, he has been sleepy and less active than usual. Physical examination shows a lethargic boy with a large, full anterior fontanelle. Bilateral retinal hemorrhages are seen on funduscopic examination. Which of the following should be strongly suspected in this patient?

- A. Abusive head trauma
- B. Bacterial meningitis
- C. Idiopathic thrombocytopenic purpura
- D. Neonatal vitamin K deficiency
- E. Retinoblastoma
- F. Unintentional head injury

Submit

Block Time Remaining: 00:01:16
TUTOR

4 | Feedback | Suspend | End Block

A 1-month-old, full-term boy is brought to the emergency department by his mother due to difficulty awakening him. The mother says that the infant was left alone for a few minutes this morning and rolled off a bed. Since then, he has been sleepy and less active than usual. Physical examination shows a lethargic boy with a large, full anterior fontanelle. Bilateral retinal hemorrhages are seen on funduscopic examination. Which of the following should be strongly suspected in this patient?

- ✓ A. Abusive head trauma (69%)
- B. Bacterial meningitis (1%)
- C. Idiopathic thrombocytopenic purpura (0%)
- D. Neonatal vitamin K deficiency (11%)
- E. Retinoblastoma (2%)
- F. Unintentional head injury (14%)

Omitted
Correct answer
A

69%
Answered correctly

02 secs
Time Spent

06/16/2020
Last Updated

Explanation

Shaking mechanism in abusive trauma

1 2 3 4 5 6 7 8 9 10 11 12 13 14 15 16 17 18 19 20 21 22 23 24 25 26 27 28 29 30

Shaking mechanism in abusive trauma

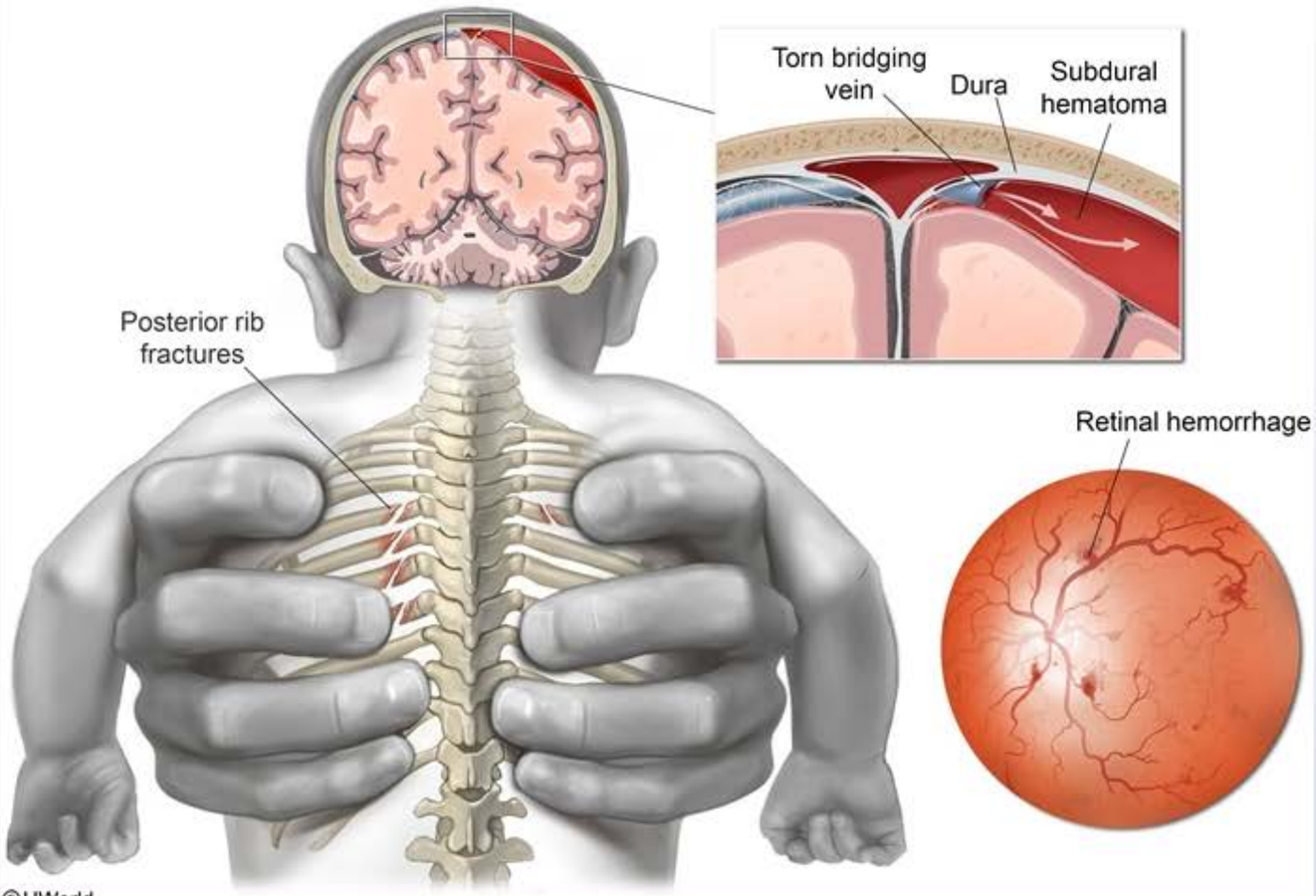

©UWorld

Abusive head trauma (AHT), formerly known as "shaken baby syndrome," is inflicted intracranial injury due to blunt force trauma or **vigorous shaking** in a to-and-fro fashion. The resultant injuries are due to infants' unique anatomic features. Infants have larger heads, enlarged subarachnoid spaces, higher brain water content, and decreased cervical muscle tone compared to older children. These factors lead to

©UWorld

Abusive head trauma (AHT), formerly known as "shaken baby syndrome," is inflicted intracranial injury due to blunt force trauma or **vigorous shaking** in a to-and-fro fashion. The resultant injuries are due to infants' unique anatomic features. Infants have larger heads, enlarged subarachnoid spaces, higher brain water content, and decreased cervical muscle tone compared to older children. These factors lead to increased movement of the immature brain in relation to the skull, resulting in **tearing of the bridging veins** and subdural hemorrhages. Because AHT may occur repeatedly over weeks to months, acute on chronic subdural hemorrhages are often seen.

The shaking motion also results in **retinal hemorrhages** due to rupture of congested retinal veins. Retinal hemorrhages are highly suggestive of AHT. Infants' ribs are flexible and pliable, and **posterior rib fractures** are also alarming for trauma by a perpetrator's grasp on the torso. In addition, the history provided by this patient's parent does not match his developmental age, as rolling over is not typical before age 4 months. Furthermore, an accidental fall **(Choice F)** from a bed would generally not be sufficient to cause a large intracranial hemorrhage resulting in altered mental status and would not explain retinal hemorrhages.

(Choice B) Although bacterial meningitis can cause lethargy, patients are typically febrile.

(Choice C) Idiopathic thrombocytopenic purpura, caused by platelet autoantibody formation, presents with petechiae, ecchymoses, and bleeding after minor trauma. Intracranial hemorrhage is rare and retinal hemorrhages are not seen.

(Choice D) All newborns are vitamin K-deficient and are given prophylactic vitamin K injections at birth. Although vitamin K deficiency can present with intracranial, umbilical, and gastrointestinal bleeding, retinal hemorrhages are not seen.

(Choice E) Retinoblastoma is the most common ocular tumor of infancy and presents with absence of the "red reflex" on physical examination. Lethargy and retinal hemorrhage are not seen.

Educational objective:
Abusive head trauma can be caused by vigorous shaking of an infant and results in **subdural hemorrhage** (due to tearing of bridging veins) and **retinal hemorrhages**. Additional red flags are injuries inconsistent with history or developmental age.

References

- Abusive head trauma in children: a literature review.

Settings

1 2 3 4 5 6 7 8 9 10 11 12 13 14 15 16 17 18 19 20 21 22 23 24 25 26 27 28 29 30

Item 36 of 40
Question Id: 347

Mark | Previous | Next | Full Screen | Tutorial | Lab Values | Notes | Calculator | Reverse Color | Text Zoom | Settings

©UWorld

Exhibit Display

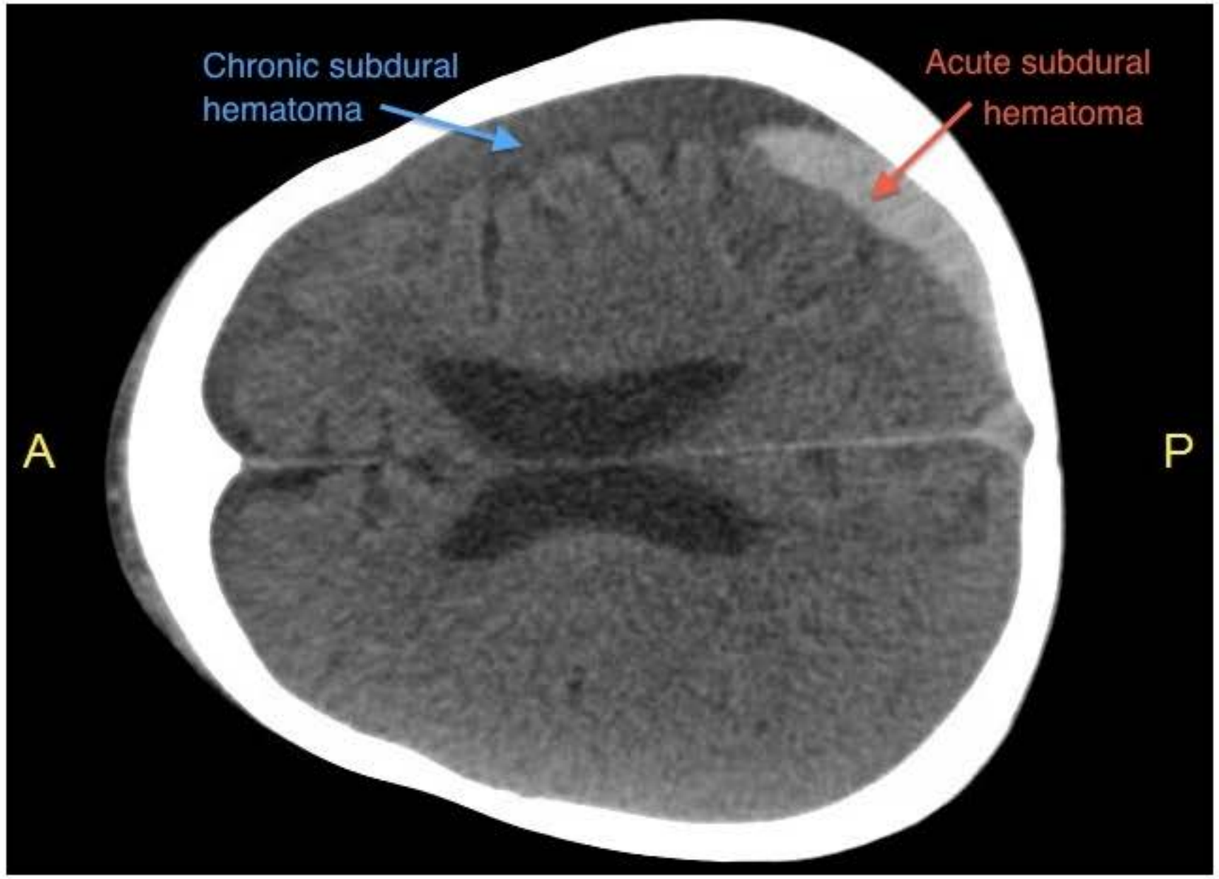

Zoom In | Zoom Out | Reset | Add To New Card | Existing Card

Block Time Remaining: 00:01:17
TUTOR

4 | Feedback | Suspend | End Block

Settings

1 2 3 4 5 6 7 8 9 10 11 12 13 14 15 16 17 18 19 20 21 22 23 24 25 26 27 28 29 30

Item 36 of 40
Question Id: 347

Mark | Previous | Next | Full Screen | Tutorial | Lab Values | Notes | Calculator | Reverse Color | Text Zoom | Settings

©UWorld

Exhibit Display

Normal eyes & white reflex

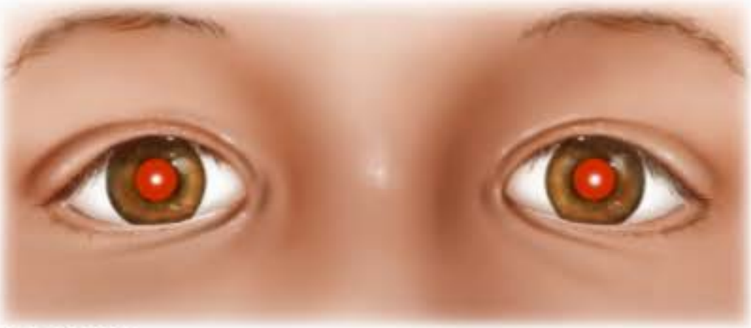

Normal eyes
Red reflexes & corneal light reflexes are equal.

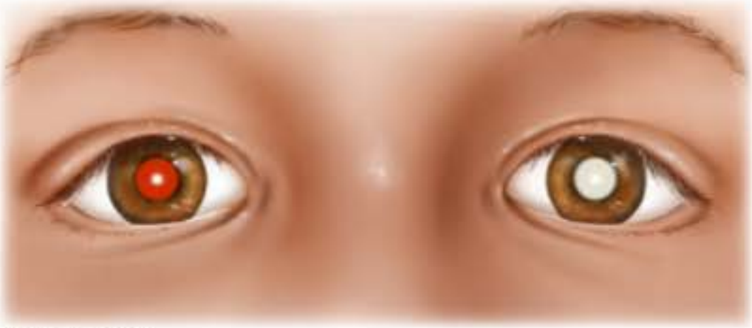

Absent reflex
White reflex on abnormal eye can result from opacities of the lens (eg, cataract) or tumor (eg, retinoblastoma).

©UWorld

Zoom In | Zoom Out | Reset | Add To New Card | Existing Card

Block Time Remaining: 00:01:17
TUTOR

4 | Feedback | Suspend | End Block

Settings

1 2 3 4 5 6 7 8 9 10 11 12 13 14 15 16 17 18 19 20 21 22 23 24 25 26 27 28 29 30

Item 37 of 40
Question Id: 636

Mark | Previous | Next | Full Screen | Tutorial | Lab Values | Notes | Calculator | Reverse Color | Text Zoom | Settings

A 15-year-old girl comes to the office with gait instability. Since age 12, the patient has had mild weakness and "clumsiness" in her lower limbs that have progressed. She has to hold on to the railing when walking down stairs due to several recent falls. Physical examination reveals kyphoscoliosis, pes cavus, and bilateral lower extremity ataxia. Joint position and vibration sense are also impaired. Further evaluation reveals that she is suffering from an inherited disease. This patient is at greatest risk of dying from which of the following conditions?

- A. Aortic dissection
- B. Brain tumor
- C. Cardiomyopathy
- D. Intracranial bleeding
- E. Liver failure
- F. Renal disease

Submit

Block Time Remaining: 00:01:17
TUTOR

1 | Feedback | Suspend | End Block

Settings

1 2 3 4 5 6 7 8 9 10 11 12 13 14 15 16 17 18 19 20 21 22 23 24 25 26 27 28 29 30

Item 37 of 40
Question Id: 636

Mark | Previous | Next | Full Screen | Tutorial | Lab Values | Notes | Calculator | Reverse Color | Text Zoom | Settings

A 15-year-old girl comes to the office with gait instability. Since age 12, the patient has had mild weakness and "clumsiness" in her lower limbs that have progressed. She has to hold on to the railing when walking down stairs due to several recent falls. Physical examination reveals kyphoscoliosis, pes cavus, and bilateral lower extremity ataxia. Joint position and vibration sense are also impaired. Further evaluation reveals that she is suffering from an inherited disease. This patient is at greatest risk of dying from which of the following conditions?

- A. Aortic dissection (8%)
- B. Brain tumor (4%)
- ✓ C. Cardiomyopathy (73%)
- D. Intracranial bleeding (8%)
- E. Liver failure (1%)
- F. Renal disease (3%)

Omitted
Correct answer
C

73%
Answered correctly

01 sec
Time Spent

06/07/2020
Last Updated

Explanation

Friedreich ataxia

Block Time Remaining: 00:01:18
TUTOR

Feedback | Suspend | End Block

1 2 3 4 5 6 7 8 9 10 11 12 13 14 15 16 17 18 19 20 21 22 23 24 25 26 27 28 29 30

Friedreich ataxia

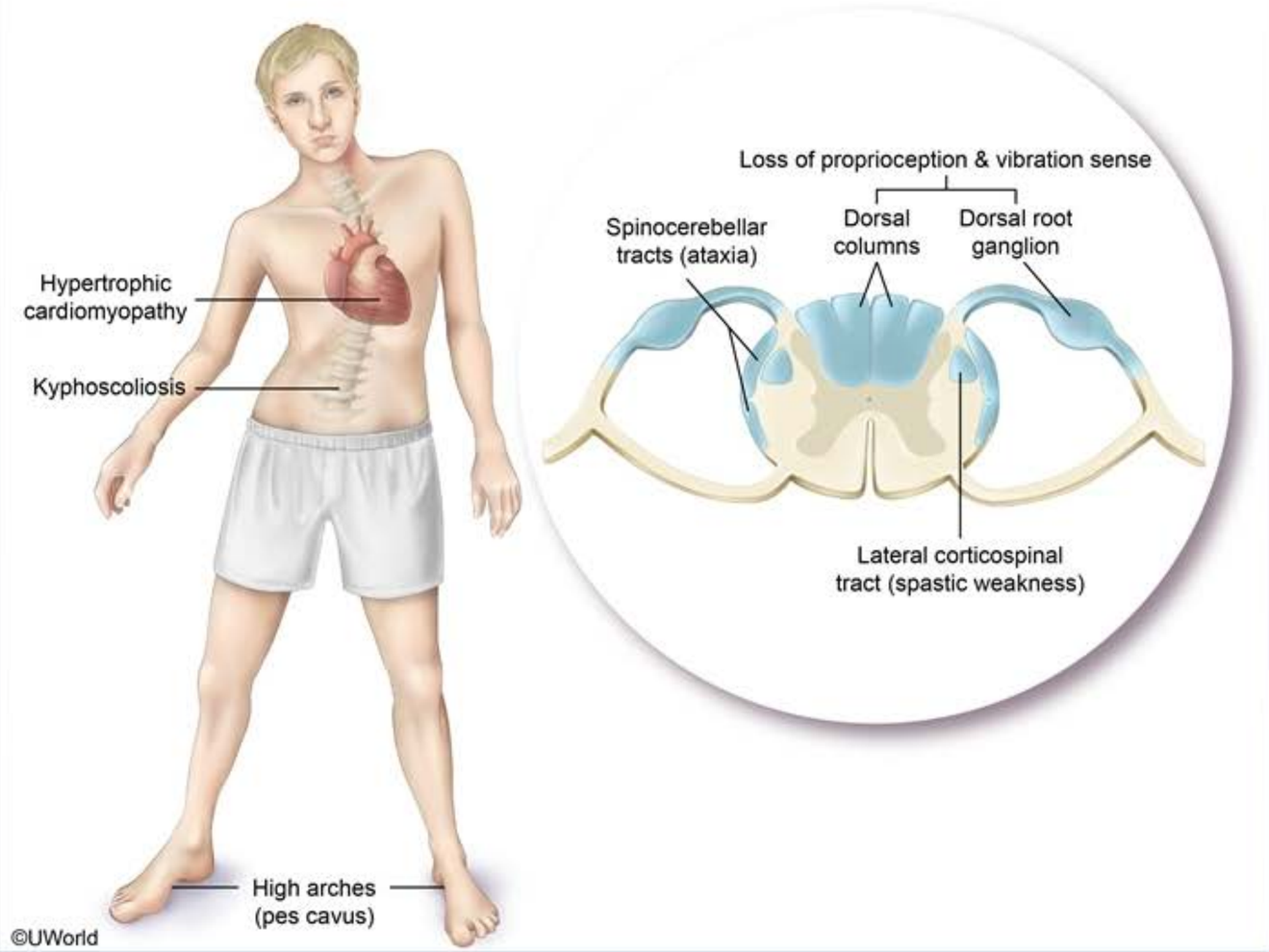

This patient likely has **Friedreich ataxia**, an autosomal recessive condition that typically presents during childhood/adolescence with progressive

©UWorld

This patient likely has **Friedreich ataxia**, an autosomal recessive condition that typically presents during childhood/adolescence with progressive **gait ataxia** (due to degeneration of the spinocerebellar tracts) and impaired joint and vibration sense (due to degeneration of the posterior columns and dorsal root ganglia). Lateral corticospinal tract involvement may result in spastic muscle weakness and a positive Babinski sign.

Other characteristic features of Friedreich ataxia include **hypertrophic cardiomyopathy**, skeletal abnormalities (eg, kyphoscoliosis, pes cavus), and diabetes mellitus. Complications from cardiomyopathy (eg, cardiac arrhythmias, congestive heart failure) are the most common cause of death.

(Choice A) Marfan syndrome is an autosomal dominant connective tissue disorder associated with aortic dissection, mitral valve prolapse, ectopia lentis, and skeletal findings (eg, pectus excavatum, arachnodactyly, joint hypermobility).

(Choice B) Neurofibromatosis types 1 (NF1) and 2 (NF2) are autosomal dominant disorders. NF1 is associated with optic gliomas, whereas NF2 is associated with bilateral acoustic schwannomas and meningiomas.

(Choices D and F) Autosomal dominant polycystic kidney disease usually presents in adults and is associated with hypertension, renal failure, and intracranial bleeding due to ruptured Berry aneurysms.

(Choice E) Wilson disease (hepatolenticular degeneration) is an autosomal recessive disorder associated with liver failure, movement abnormalities, and psychiatric symptoms.

Educational objective:
Friedreich ataxia is an autosomal recessive condition that presents during childhood/adolescence with progressive gait ataxia (due to degeneration of the spinocerebellar tracts) and impaired joint and vibration sense (due to degeneration of the posterior columns and dorsal root ganglia). Other features include hypertrophic cardiomyopathy (most common cause of death), skeletal abnormalities (eg, kyphoscoliosis, pes cavus), and diabetes mellitus.

References

- Clinical features of Friedreich's ataxia: classical and atypical phenotypes.

A 26-year-old man is brought to the emergency department after a high-speed motorcycle collision. The patient was thrown several feet after his motorcycle collided with a car. On arrival, he is profoundly comatose. A CT scan of the head performed within an hour of the event shows no abnormalities. The patient dies several hours later, and autopsy examination is performed. Brain histopathology shows widespread axonal swelling, predominantly at the gray-white junction. Immunohistochemical staining of these axons reveals accumulation of alpha-synuclein and amyloid precursor proteins. Which of the following is the most likely cause of these observed findings?

A. Diffuse cerebral hypoperfusion

B. Disruption of the bridging cortical veins

C. Glutamate-mediated neuronal injury

D. Interruption of the white matter tracts

E. Secondary microvascular spasm

Submit

A 26-year-old man is brought to the emergency department after a high-speed motorcycle collision. The patient was thrown several feet after his motorcycle collided with a car. On arrival, he is profoundly comatose. A CT scan of the head performed within an hour of the event shows no abnormalities. The patient dies several hours later, and autopsy examination is performed. Brain histopathology shows widespread axonal swelling, predominantly at the gray-white junction. Immunohistochemical staining of these axons reveals accumulation of alpha-synuclein and amyloid precursor proteins. Which of the following is the most likely cause of these observed findings?

- A. Diffuse cerebral hypoperfusion (28%)
- B. Disruption of the bridging cortical veins (5%)
- C. Glutamate-mediated neuronal injury (25%)
- ✓ D. Interruption of the white matter tracts (34%)
- E. Secondary microvascular spasm (5%)

Omitted
Correct answer
D

34%
Answered correctly

01 sec
Time Spent

04/07/2020
Last Updated

Explanation

Diffuse axonal injury

Settings

1 2 3 4 5 6 7 8 9 10 11 12 13 14 15 16 17 18 19 20 21 22 23 24 25 26 27 28 29 30

Item 38 of 40
Question Id: 15678

Mark | Previous | Next | Full Screen | Tutorial | Lab Values | Notes | Calculator | Reverse Color | Text Zoom | Settings

Diffuse axonal injury

Traumatic brain injury

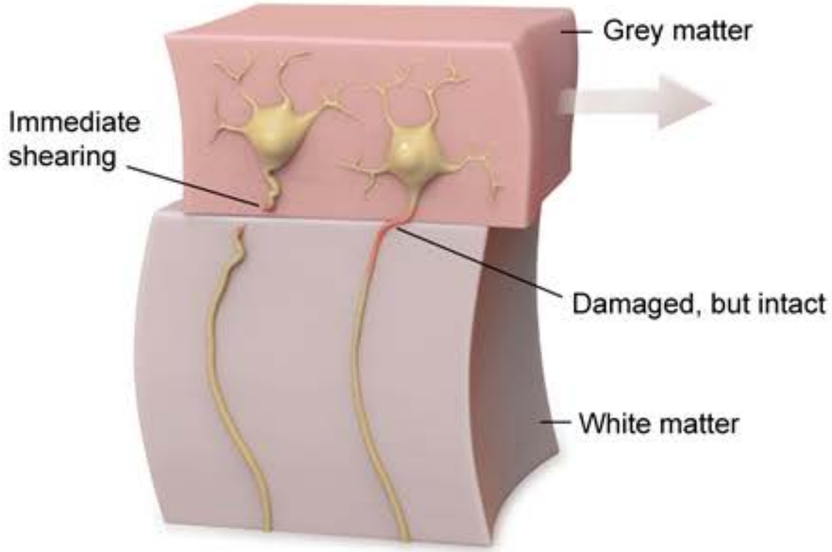

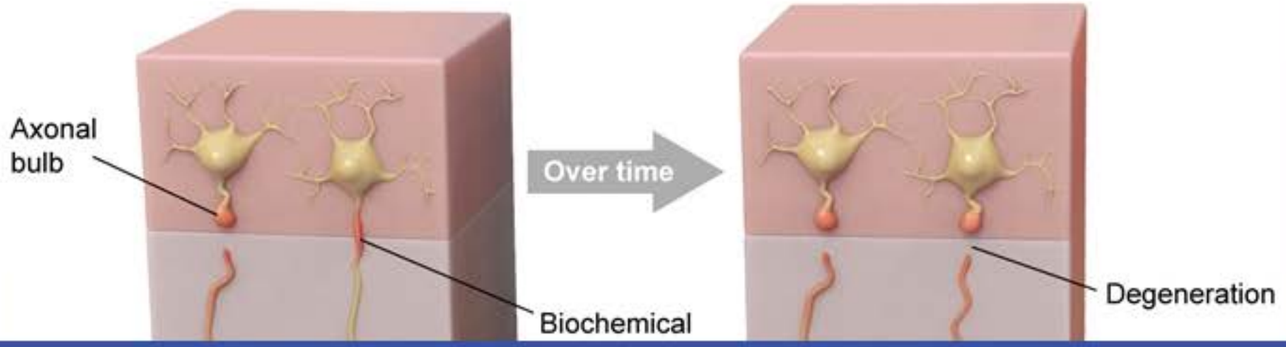

Block Time Remaining: 00:01:19
TUTOR

3 | Feedback | Suspend | End Block

Settings

1 2 3 4 5 6 7 8 9 10 11 12 13 14 15 16 17 18 19 20 21 22 23 24 25 26 27 28 29 30

Item 38 of 40
Question Id: 15678

Mark | Previous | Next | Full Screen | Tutorial | Lab Values | Notes | Calculator | Reverse Color | Text Zoom | Settings

Diffuse axonal injury

Traumatic brain injury

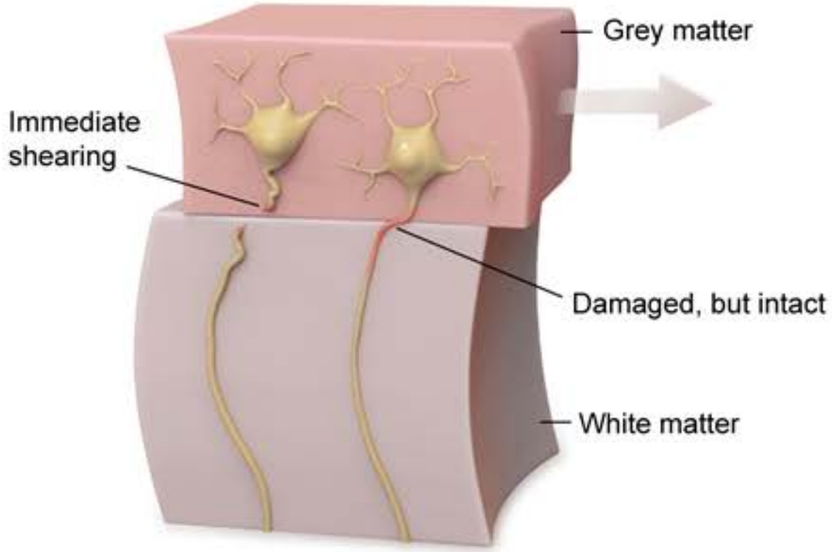

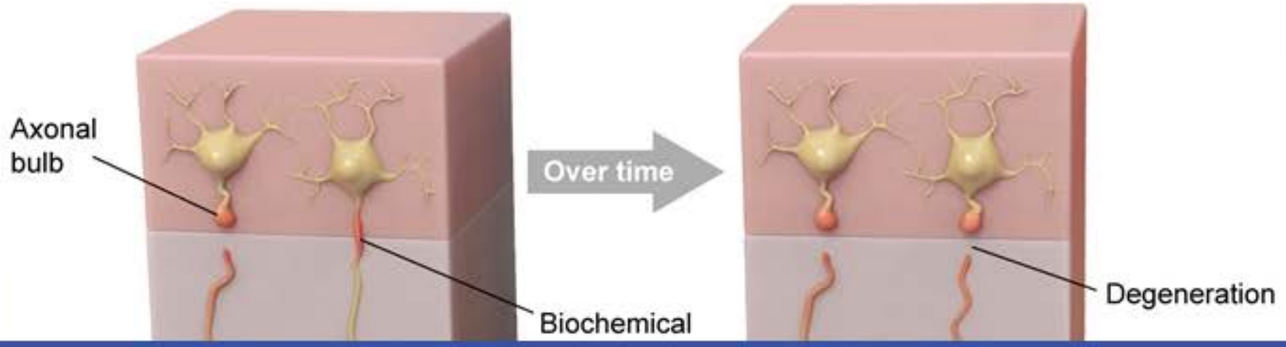

Block Time Remaining: 00:01:19
TUTOR

3 | Feedback | Suspend | End Block

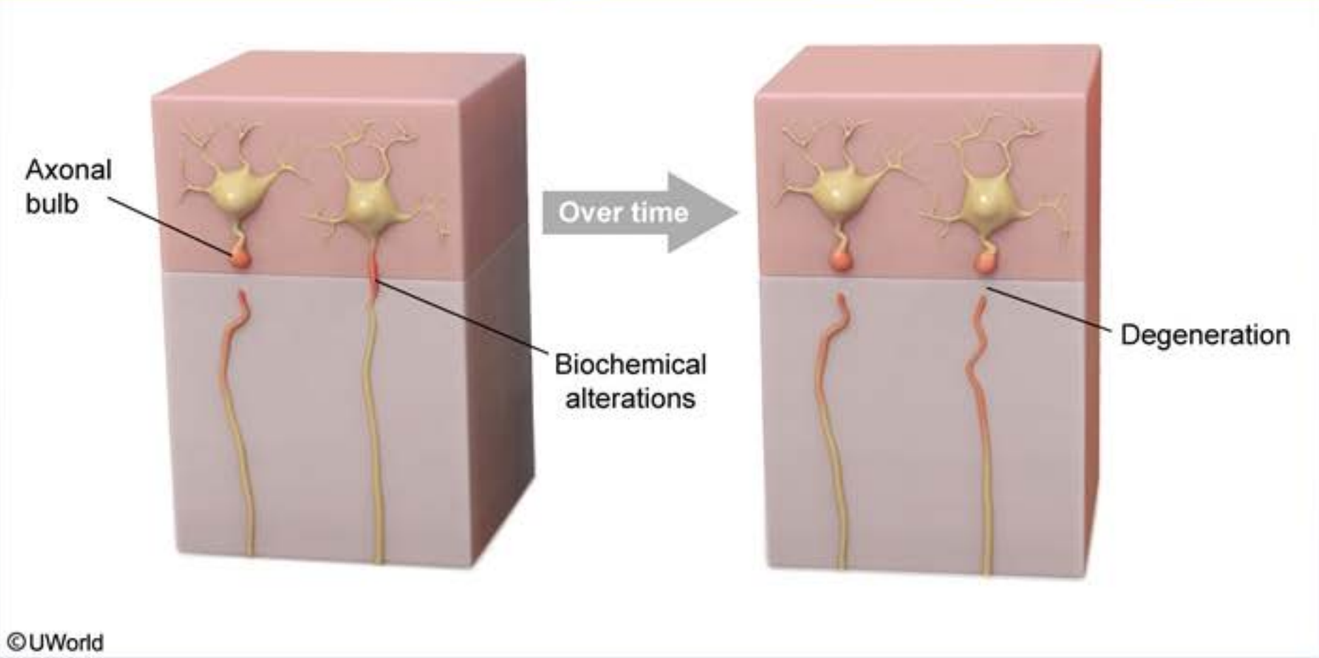

This patient has histopathologic findings of **diffuse axonal injury** (DAI), a type of severe traumatic brain injury that can occur from direct blunt force injury (eg, head hitting windshield) or abrupt changes in acceleration-deceleration (eg, restrained passenger coming to sudden stop after a collision). Transfer of force can result in immediate **shearing of the white matter tracts** or induce secondary biochemical changes leading to degradation of the axonal cytoskeleton with subsequent axon breakage. Normal axonal transport is inhibited, leading to accumulation of axonally transported proteins (eg, **amyloid precursor**, **alpha-synuclein**) within axonal swellings at the point of injury (eg, axonal bulb formation).

Presentation varies based on the extent of injury; most patients are **comatose** (Glasgow Coma Score <8); however, those with very mild DAI may have only concussive symptoms (eg, headache, amnesia). CT scan has low sensitivity for diagnosis and is often normal, but MRI may demonstrate lesions at the gray-white junction. Microscopically, DAI is visible as **widespread axonal swelling**, most pronounced at the **gray-white matter junction**. Prognosis is poor, with up to 25% of cases resulting in death.

(Choices A and C) Diffuse cerebral hypoperfusion typically occurs in the setting of systemic hypotension or cardiac arrest. Watershed zone

This patient has histopathologic findings of **diffuse axonal injury** (DAI), a type of severe traumatic brain injury that can occur from direct blunt force injury (eg, head hitting windshield) or abrupt changes in acceleration-deceleration (eg, restrained passenger coming to sudden stop after a collision). Transfer of force can result in immediate **shearing of the white matter tracts** or induce secondary biochemical changes leading to degradation of the axonal cytoskeleton with subsequent axon breakage. Normal axonal transport is inhibited, leading to accumulation of axonally transported proteins (eg, **amyloid precursor**, **alpha-synuclein**) within axonal swellings at the point of injury (eg, axonal bulb formation).

Presentation varies based on the extent of injury; most patients are **comatose** (Glasgow Coma Score <8); however, those with very mild DAI may have only concussive symptoms (eg, headache, amnesia). CT scan has low sensitivity for diagnosis and is often normal, but MRI may demonstrate lesions at the gray-white junction. Microscopically, DAI is visible as **widespread axonal swelling**, most pronounced at the **gray-white matter junction**. Prognosis is poor, with up to 25% of cases resulting in death.

(Choices A and C) Diffuse cerebral hypoperfusion typically occurs in the setting of systemic hypotension or cardiac arrest. Watershed zone infarctions or diffuse edema with blurring of the gray-white junction are often visible on imaging. Ischemic neurons can release glutamate, leading to overactivation of the NMDA receptor with continuous membrane depolarization. This results in neuronal damage in a process known as excitotoxicity. Red neurons with intensely eosinophilic cytoplasm are seen on histopathology.

(Choice B) Disruption of the bridging cortical veins results in subdural hematoma; the elderly are at increased risk due to cerebral atrophy (stretching of the bridging veins increases the risk of tear). Subdural hematomas are visible on imaging as crescent-shaped hyperdensities that cross suture lines.

(Choice E) Subarachnoid hemorrhages are typically caused by rupture of saccular aneurysms but may be associated with trauma (typically with associated brain contusions); head CT scan demonstrates blood within the subarachnoid space.

Educational objective:
Diffuse axonal injury (DAI) is a type of traumatic brain injury that results from disruption of the white matter tracts. Microscopically, DAI is visible as widespread axonal swelling, most pronounced at the gray-white matter junction, with accumulation of transport proteins (eg, amyloid precursor, alpha-synuclein) at the site of injury.

References

- Axonal pathology in traumatic brain injury

Presentation varies based on the extent of injury; most patients are **comatose** (Glasgow Coma Score <8); however, those with very mild DAI may have only concussive symptoms (eg, headache, amnesia). CT scan has low sensitivity for diagnosis and is often normal, but MRI may demonstrate lesions at the gray-white junction. Microscopically, DAI is visible as **widespread axonal swelling**, most pronounced at the **gray-white matter junction**. Prognosis is poor, with up to 25% of cases resulting in death.

(Choices A and C) Diffuse cerebral hypoperfusion typically occurs in the setting of systemic hypotension or cardiac arrest. Watershed zone infarctions or diffuse edema with blurring of the gray-white junction are often visible on imaging. Ischemic neurons can release glutamate, leading to overactivation of the NMDA receptor with continuous membrane depolarization. This results in neuronal damage in a process known as excitotoxicity. Red neurons with intensely eosinophilic cytoplasm are seen on histopathology.

(Choice B) Disruption of the bridging cortical veins results in subdural hematoma; the elderly are at increased risk due to cerebral atrophy (stretching of the bridging veins increases the risk of tear). Subdural hematomas are visible on imaging as crescent-shaped hyperdensities that cross suture lines.

(Choice E) Subarachnoid hemorrhages are typically caused by rupture of saccular aneurysms but may be associated with trauma (typically with associated brain contusions); head CT scan demonstrates blood within the subarachnoid space.

Educational objective:
Diffuse axonal injury (DAI) is a type of traumatic brain injury that results from disruption of the white matter tracts. Microscopically, DAI is visible as widespread axonal swelling, most pronounced at the gray-white matter junction, with accumulation of transport proteins (eg, amyloid precursor, alpha-synuclein) at the site of injury.

References

- Axonal pathology in traumatic brain injury.

Pathology	Nervous System	Traumatic brain injury
Subject	System	Topic

Copyright © UWorld. All rights reserved.

Settings

1 2 3 4 5 6 7 8 9 10 11 12 13 14 15 16 17 18 19 20 21 22 23 24 25 26 27 28 29 30

Item 39 of 40
Question Id: 15638

Mark | Previous | Next | Full Screen | Tutorial | Lab Values | Notes | Calculator | Reverse Color | Text Zoom | Settings

A previously healthy 16-year-old boy is evaluated for progressive headaches and blurred vision that started several months ago. The headaches are more severe upon waking up in the morning and are often accompanied by nausea and vomiting. He takes no medications and does not use tobacco, alcohol, or illicit drugs. Physical examination is notable for bilateral papilledema. MRI of the brain is shown in the exhibit. This patient's brain lesion most likely originated from which of the following cells?

- A. Astrocytes
- B. Ependymal cells
- C. Microglia
- D. Neurons
- E. Oligodendrocytes
- F. Schwann cells
- G. Vascular endothelial cells

Submit

Block Time Remaining: 00:01:19
TUTOR

7 | Feedback | Suspend | End Block

Settings

1 2 3 4 5 6 7 8 9 10 11 12 13 14 15 16 17 18 19 20 21 22 23 24 25 26 27 28 29 30

Item 39 of 40
Question Id: 15638

Mark | Previous | Next | Full Screen | Tutorial | Lab Values | Notes | Calculator | Reverse Color | Text Zoom | Settings

A previously healthy 16-year-old boy is evaluated for progressive headaches and blurred vision that started several months ago. The headaches are more severe upon waking up in the morning and are often accompanied by nausea and vomiting. He takes no medications and does not use tobacco, alcohol, or illicit drugs. Physical examination is notable for bilateral papilledema. MRI of the brain is shown in the exhibit. This patient's brain lesion most likely originated from which of the following cells?

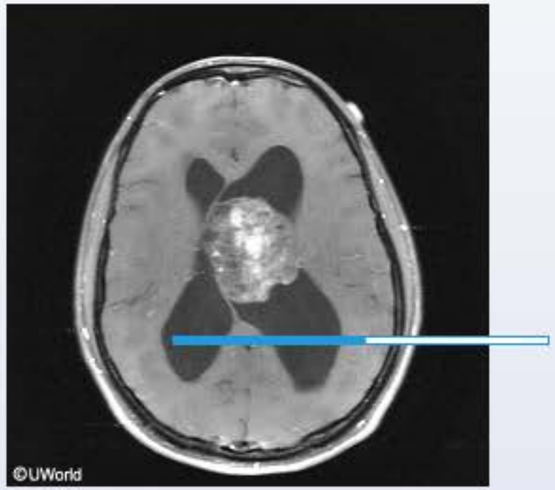

A. Astrocytes (15%)
B. Ependymal cells (73%) ✓
C. Microglia (2%)
D. Neurons (2%)
E. Oligodendrocytes (3%)
F. Schwann cells (0%)

Block Time Remaining: 00:01:21
TUTOR

7 | Feedback | Suspend | End Block

Settings

Item 39 of 40
Question Id: 15638

Mark

Calculator | Reverse Color | Text Zoom | Settings

Error

Session timeout. Please launch the application again.

OK

A. Astrocytes (15%)
B. Ependymal cells (73%)
C. Microglia (2%)
D. Neurons (2%)
E. Oligodendrocytes (3%)
F. Schwann cells (0%)
G. Vascular endothelial cells (2%)

Omitted
Correct answer
B

73%
Answered correctly

02 secs
Time Spent

06/01/2020
Last Updated

Explanation

Block Time Remaining: 00:01:21
TUTOR

Feedback | Suspend | End Block

11
12
13
14
15
16
17
18
19
20
21
22
23
24
25
26
27
28
29
30
31
32
33
34
35
36
37
38
39
40

A previously healthy 16-year-old boy is evaluated for progressive headaches and blurred vision that started several months ago. The headaches are more severe upon waking up in the morning and are often accompanied by nausea and vomiting. He takes no medications and does not use tobacco, alcohol, or illicit drugs. Physical examination is notable for bilateral papilledema. MRI of the brain is shown in the exhibit. This patient's brain lesion most likely originated from which of the following cells?

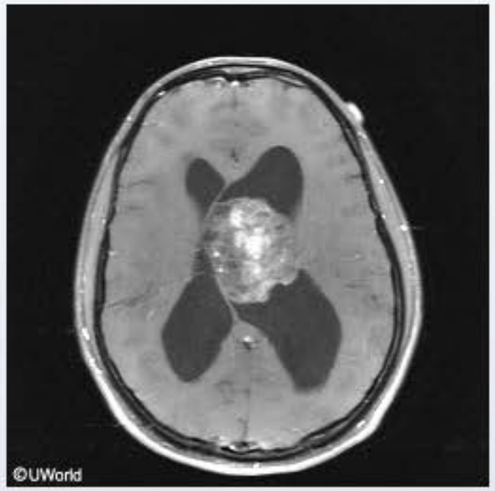

A. Astrocytes
B. Ependymal cells
C. Microglia
D. Neurons
E. Oligodendrocytes
F. Schwann cells
G. Vascular endothelial cells

11
12
13
14
15
16
17
18
19
20
21
22
23
24
25
26
27
28
29
30
31
32
33
34
35
36
37
38
39
40

brain lesion most likely originated from which of the following cells?

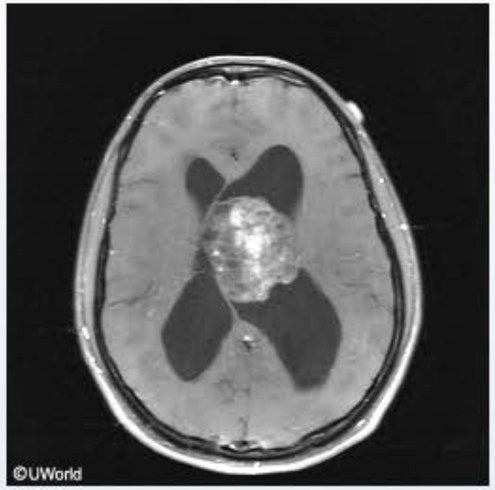

A. Astrocytes (15%)
✓ B. Ependymal cells (73%)
C. Microglia (2%)
D. Neurons (2%)
E. Oligodendrocytes (3%)
F. Schwann cells (0%)
G. Vascular endothelial cells (2%)

Omitted
Correct answer

73%
Answered correctly

06 secs
Time Spent

06/01/2020
Last Updated

11
12
13
14
15
16
17
18
19
20
21
22
23
24
25
26
27
28
29
30
31
32
33
34
35
36
37
38
39
40

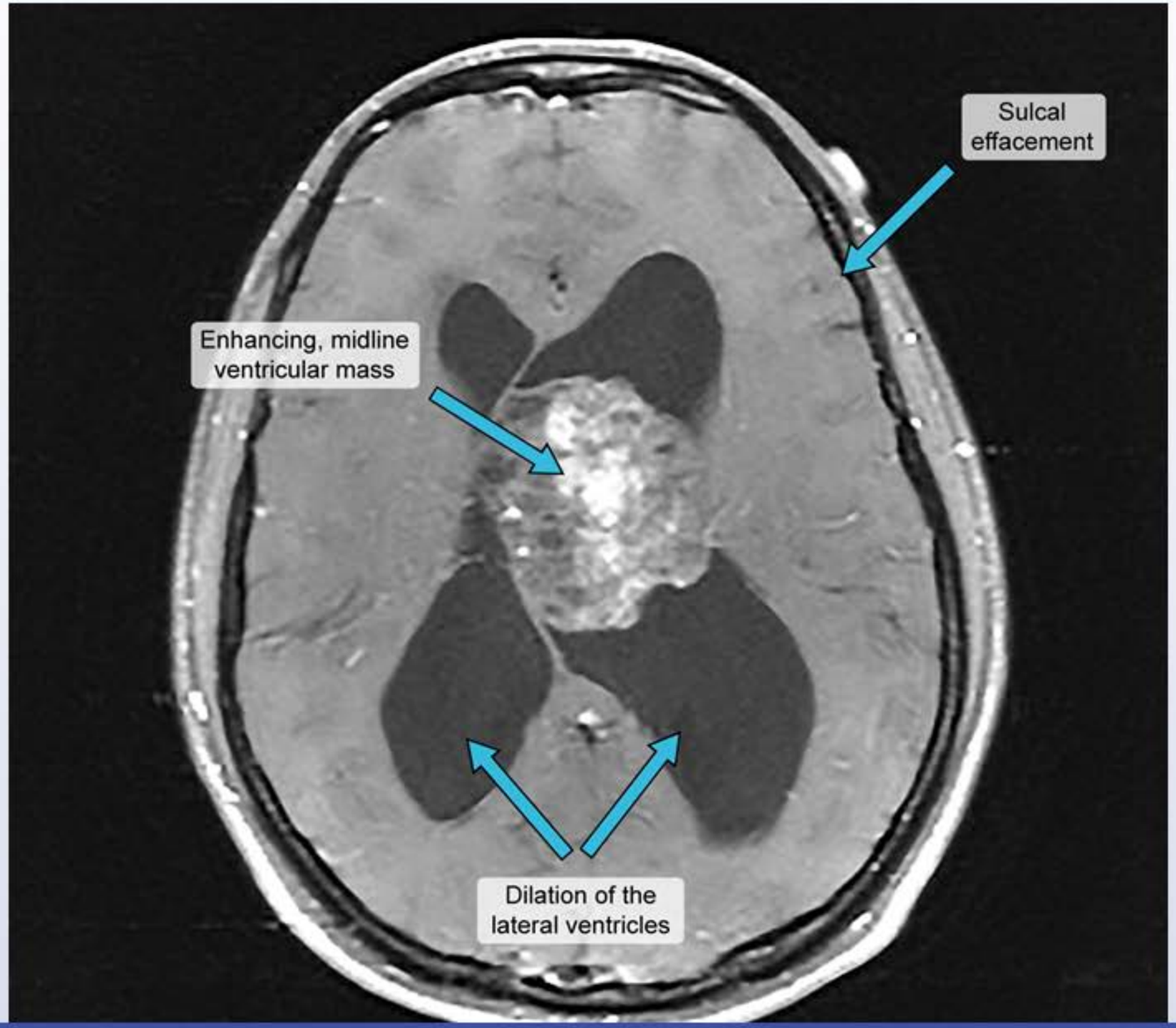

11 12 13 14 15 16 17 18 19 20 21 22 23 24 25 26 27 28 29 30 31 32 33 34 35 36 37 38 39 40

This patient with **progressive headaches** has an enhancing ventricular mass on MRI, consistent with a ventricular **ependymoma**. Ependymomas arise from **ependymal cells**, which line the walls of the ventricular system and the central canal of the spinal cord and produce cerebrospinal fluid. Choroid plexus tumors (derived from modified ependymal cells) can also be found in the lateral ventricles and have a similar appearance on MRI.

Intraventricular tumors can cause **obstructive (noncommunicating) hydrocephalus** due to impaired flow of cerebrospinal fluid through the interventricular foramina. Hydrocephalus typically manifests with headache, signs of **increased intracranial pressure** (eg, nausea, papilledema, blurred vision), and dilated ventricles on neuroimaging. The diagnosis of ependymoma can be confirmed on histopathologic examination by finding perivascular pseudorosettes.

(Choice A) Astrocytes are the most prevalent type of glial cell in the CNS. Tumors derived from these cells (eg, astrocytoma, glioblastoma) can cause hydrocephalus due to mass effect but are typically found in the brain parenchyma as opposed to the ventricular system.

(Choice C) Microglial cells are the phagocytic cells in the CNS. They are not associated with the origination of any major types of CNS tumors.

(Choice D) Brain tumors that arise from neuronal cells are rare, usually found in the brain parenchyma, and more likely to be of mixed neuronal-glial cell origin.

(Choice E) Oligodendrocytes are glial cells that are responsible for the myelination of axons in the CNS. Well-differentiated brain tumors arising from oligodendrocytes are referred to as oligodendrogliomas. These tumors, like astrocytomas, occur in the brain parenchyma and not in the ventricular system.

(Choice F) Schwann cells form myelin in the peripheral nervous system and serve as the cell of origin for schwannomas, which most commonly occur on upper extremity nerves. Schwannomas that arise from cranial nerves (eg, CN VIII, acoustic neuromas) can cause hydrocephalus from mass effect due to their central location but would not be associated with an intraventricular mass.

(Choice G) Hemangioblastomas originate from vascular endothelial cells in the cerebellum or spinal cord. They characteristically appear as an enhancing nodule with a cystic component. These tumors often bleed, which can cause hydrocephalus due to dysfunction in cerebrospinal reabsorption at the arachnoid villi, but do not originate from the ventricular wall.

Educational objective:
Ependymomas originate from the ependymal cells that line the ventricular system and the central canal of the spinal cord. Ventricular

finding perivascular pseudorosettes.

(Choice A) Astrocytes are the most prevalent type of glial cell in the CNS. Tumors derived from these cells (eg, astrocytoma, glioblastoma) can cause hydrocephalus due to mass effect but are typically found in the brain parenchyma as opposed to the ventricular system.

(Choice C) Microglial cells are the phagocytic cells in the CNS. They are not associated with the origination of any major types of CNS tumors.

(Choice D) Brain tumors that arise from neuronal cells are rare, usually found in the brain parenchyma, and more likely to be of mixed neuronal-glial cell origin.

(Choice E) Oligodendrocytes are glial cells that are responsible for the myelination of axons in the CNS. Well-differentiated brain tumors arising from oligodendrocytes are referred to as oligodendrogliomas. These tumors, like astrocytomas, occur in the brain parenchyma and not in the ventricular system.

(Choice F) Schwann cells form myelin in the peripheral nervous system and serve as the cell of origin for schwannomas, which most commonly occur on upper extremity nerves. Schwannomas that arise from cranial nerves (eg, CN VIII, acoustic neuromas) can cause hydrocephalus from mass effect due to their central location but would not be associated with an intraventricular mass.

(Choice G) Hemangioblastomas originate from vascular endothelial cells in the cerebellum or spinal cord. They characteristically appear as an enhancing nodule with a cystic component. These tumors often bleed, which can cause hydrocephalus due to dysfunction in cerebrospinal reabsorption at the arachnoid villi, but do not originate from the ventricular wall.

Educational objective:
Ependymomas originate from the ependymal cells that line the ventricular system and the central canal of the spinal cord. Ventricular ependymomas can block the flow of cerebrospinal fluid through the interventricular foramina, causing signs of increased intracranial pressure (eg, headache, papilledema) due to obstructive (noncommunicating) hydrocephalus.

Pathology	Nervous System	Brain tumors
Subject	System	Topic

Copyright © UWorld. All rights reserved.

11 12 13 14 15 16 17 18 19 20 21 22 23 24 25 26 27 28 29 30 31 32 33 34 35 36 37 38 39 40

11
12
13
14
15
16
17
18
19
20
21
22
23
24
25
26
27
28
29
30
31
32
33
34
35
36
37
38
39
40

Exhibit Display

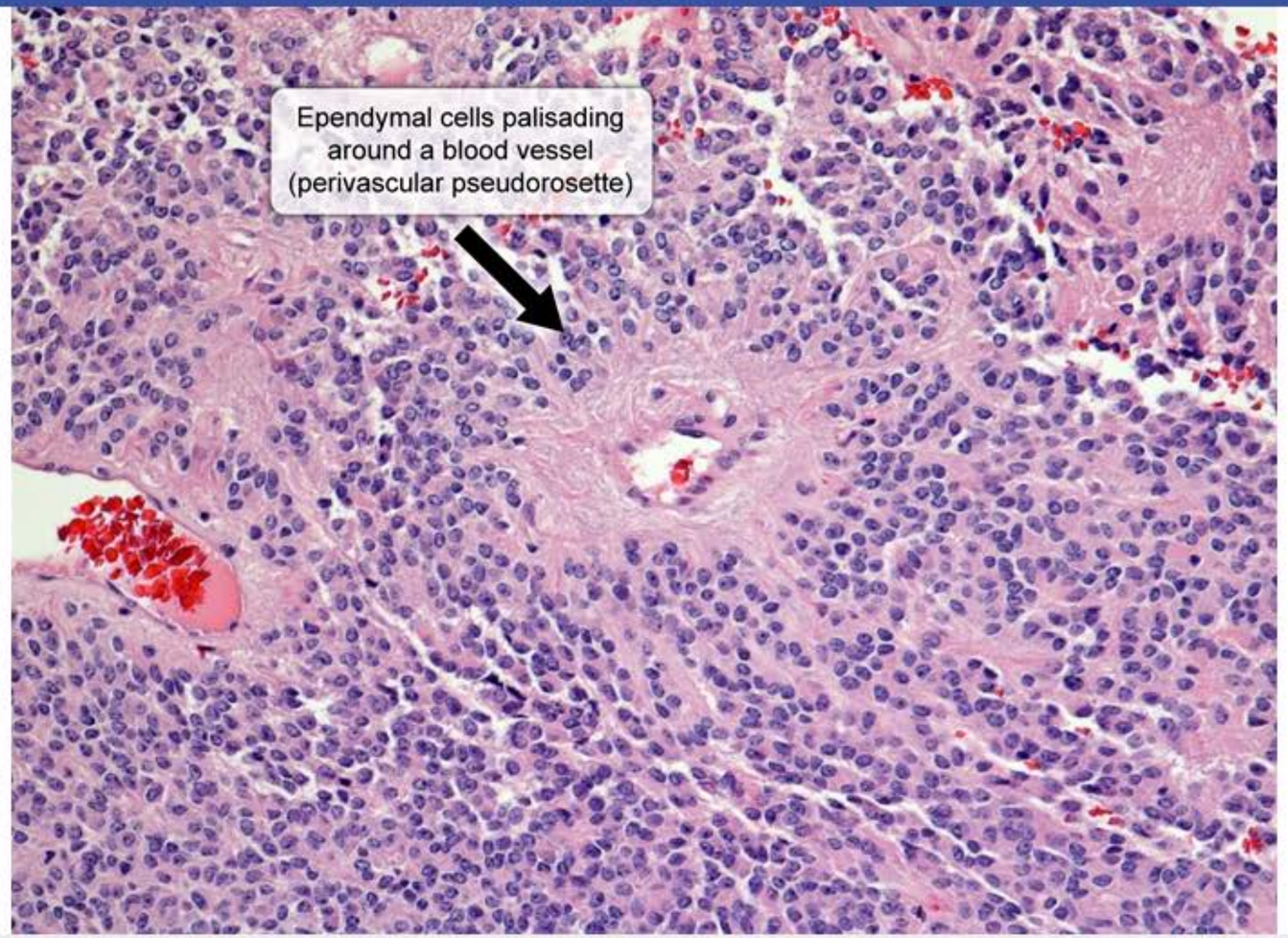

Zoom In | Zoom Out | Reset | Add To New Card | Existing Card

(Choice F) Schwann cells form myelin in the peripheral nervous system and serve as the cell of origin for schwannomas, which most commonly

11
12
13
14
15
16
17
18
19
20
21
22
23
24
25
26
27
28
29
30
31
32
33
34
35
36
37
38
39
40

Exhibit Display

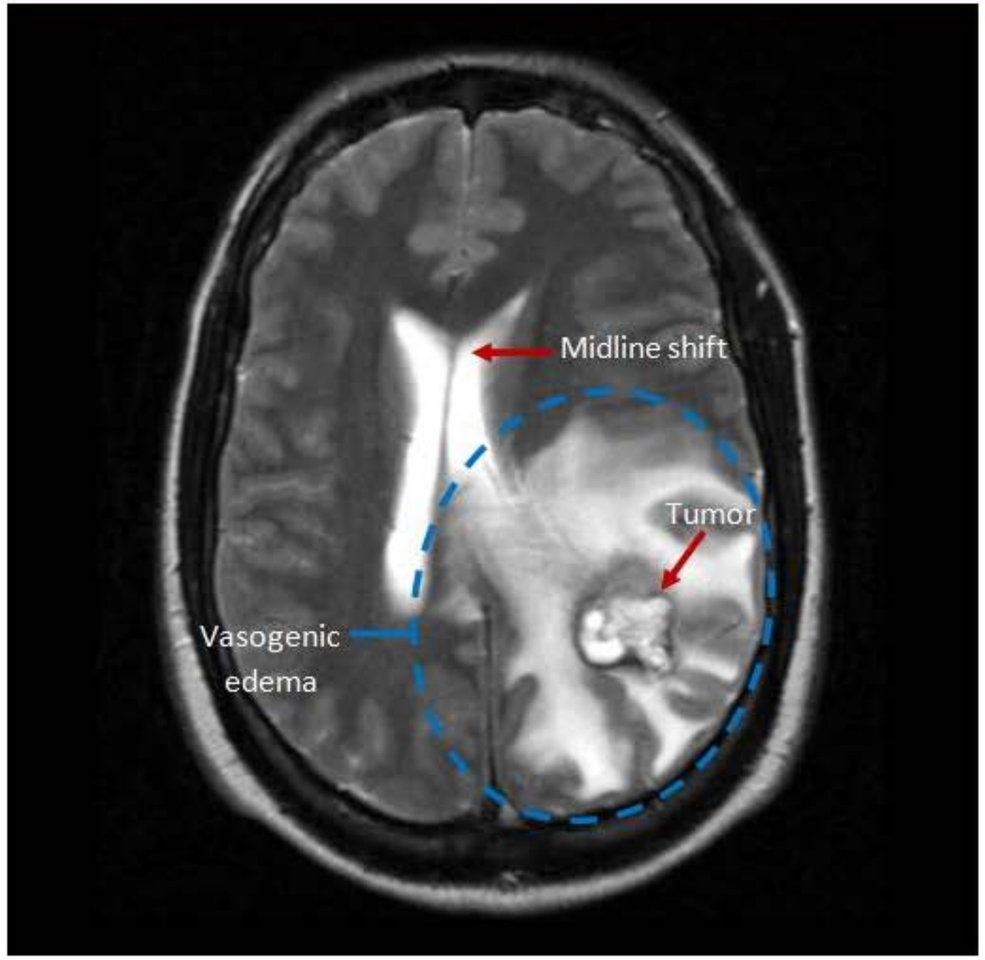

Zoom In | Zoom Out | Reset | Add To New Card | Existing Card

(Choice F) Schwann cells form myelin in the peripheral nervous system and serve as the cell of origin for schwannomas, which most commonly

finding perivascular pseudorosettes.

Exhibit Display

Zoom In | Zoom Out | Reset | Add To New Card | Existing Card

11
12
13
14
15
16
17
18
19
20
21
22
23
24
25
26
27
28
29
30
31
32
33
34
35
36
37
38
39
40

finding perivascular pseudorosettes.

Exhibit Display

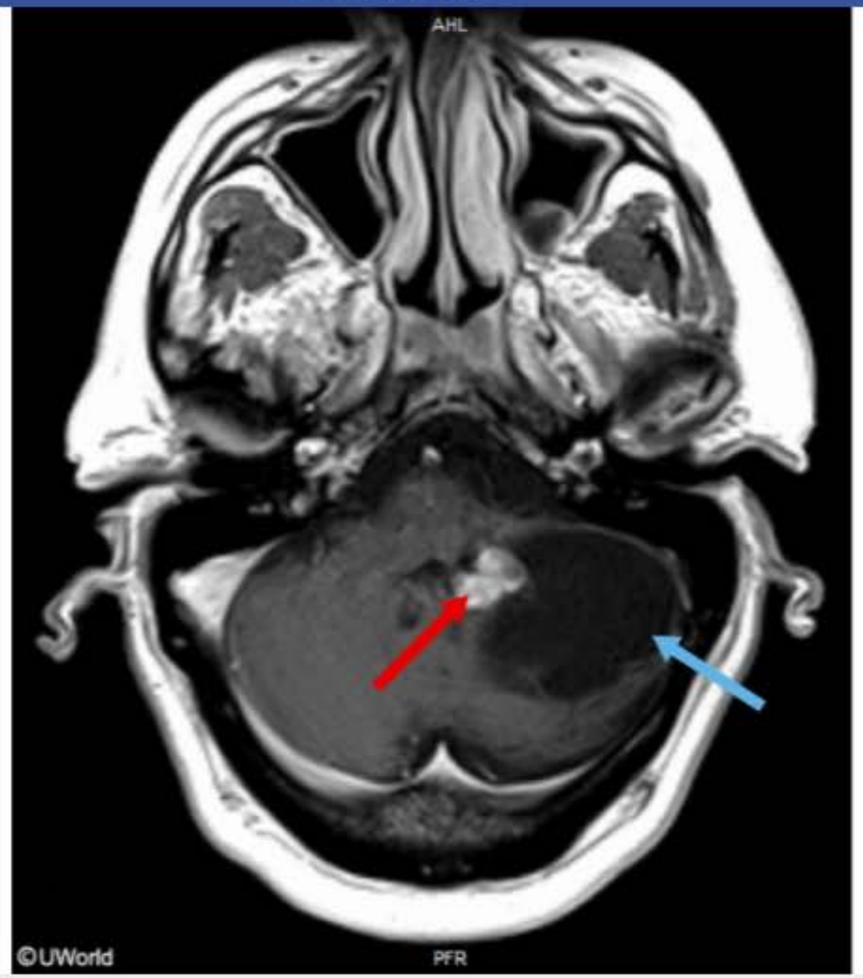

Zoom In | Zoom Out | Reset | Add To New Card | Existing Card

11
12
13
14
15
16
17
18
19
20
21
22
23
24
25
26
27
28
29
30
31
32
33
34
35
36
37
38
39
40

11
12
13
14
15
16
17
18
19
20
21
22
23
24
25
26
27
28
29
30
31
32
33
34
35
36
37
38
39
40

A 65-year-old man comes to the office due to tremors. He was diagnosed with idiopathic Parkinson disease 10 years ago and has since been successfully treated with levodopa/carbidopa. However, over the last several months, he has developed frequent "freezing" episodes characterized by a sudden loss of mobility. More recently, the patient's tremors worsened after he reduced his levodopa dose following the development of excessive body movements. On examination, he has a bilateral resting tremor that is worse on the right, bradykinesia, and cogwheel rigidity. He is interested in discussing surgical options. This patient would most likely benefit from high-frequency deep brain stimulation targeted at suppressing neuronal activity in which of the following brain structures?

A. Caudate nucleus
B. Globus pallidus externa
C. Putamen
D. Red nucleus
E. Subthalamic nucleus
F. Ventral intermediate nucleus of the thalamus

Submit

11
12
13
14
15
16
17
18
19
20
21
22
23
24
25
26
27
28
29
30
31
32
33
34
35
36
37
38
39
40

A 65-year-old man comes to the office due to tremors. He was diagnosed with idiopathic Parkinson disease 10 years ago and has since been successfully treated with levodopa/carbidopa. However, over the last several months, he has developed frequent "freezing" episodes characterized by a sudden loss of mobility. More recently, the patient's tremors worsened after he reduced his levodopa dose following the development of excessive body movements. On examination, he has a bilateral resting tremor that is worse on the right, bradykinesia, and cogwheel rigidity. He is interested in discussing surgical options. This patient would most likely benefit from high-frequency deep brain stimulation targeted at suppressing neuronal activity in which of the following brain structures?

A. Caudate nucleus (11%)

B. Globus pallidus externa (28%)

C. Putamen (9%)

D. Red nucleus (2%)

✓ E. Subthalamic nucleus (42%)

F. Ventral intermediate nucleus of the thalamus (4%)

Omitted
Correct answer
E

42%
Answered correctly

02 secs
Time Spent

04/05/2020
Last Updated

Explanation

Normal basal ganglia motor pathways

11
12
13
14
15
16
17
18
19
20
21
22
23
24
25
26
27
28
29
30
31
32
33
34
35
36
37
38
39
40

Normal basal ganglia motor pathways

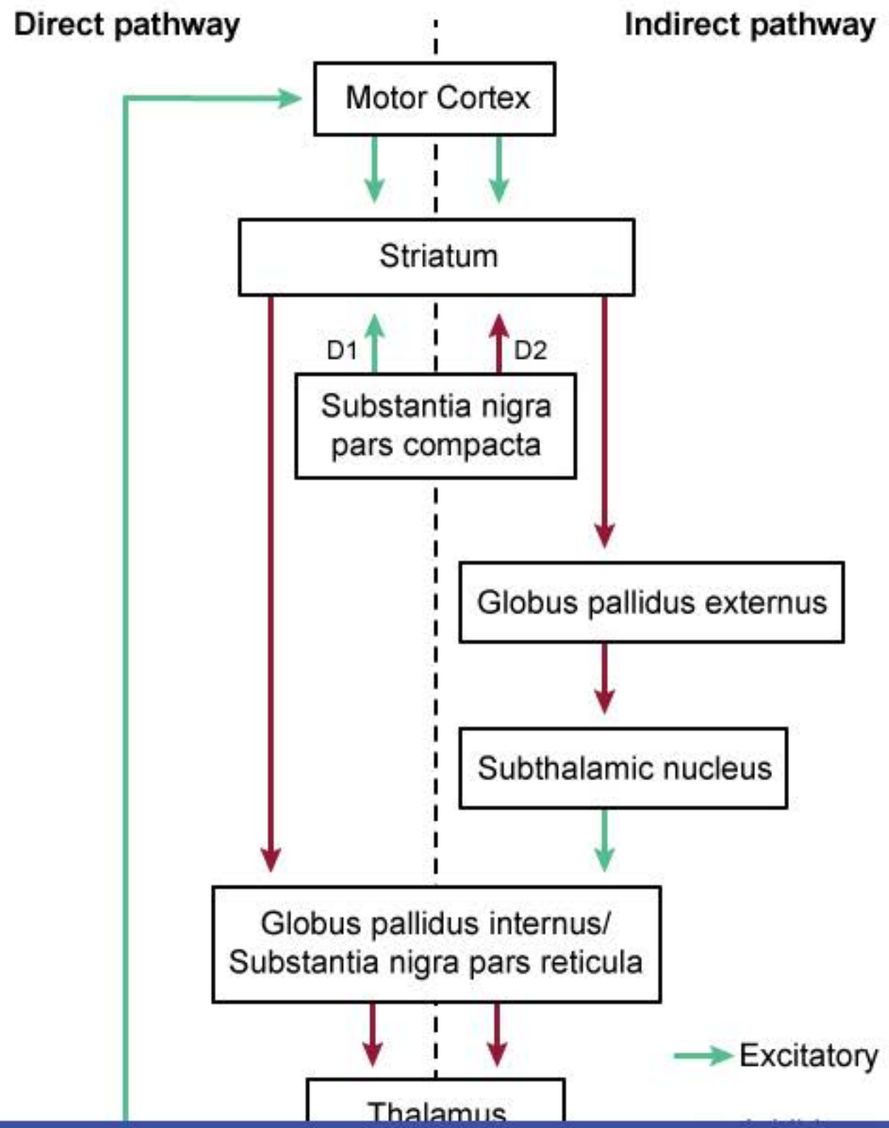

Direct pathway | Indirect pathway

Exhibit Display

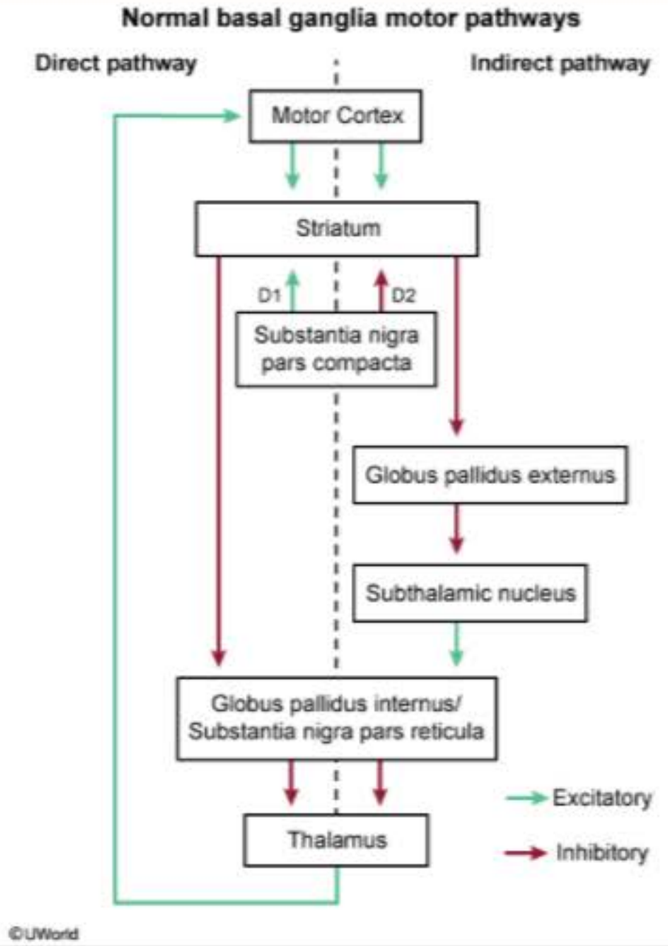

Zoom In | Zoom Out | Reset | Add To New Card | Existing Card

11
12
13
14
15
16
17
18
19
20
21
22
23
24
25
26
27
28
29
30
31
32
33
34
35
36
37
38
39
40

11
12
13
14
15
16
17
18
19
20
21
22
23
24
25
26
27
28
29
30
31
32
33
34
35
36
37
38
39
40

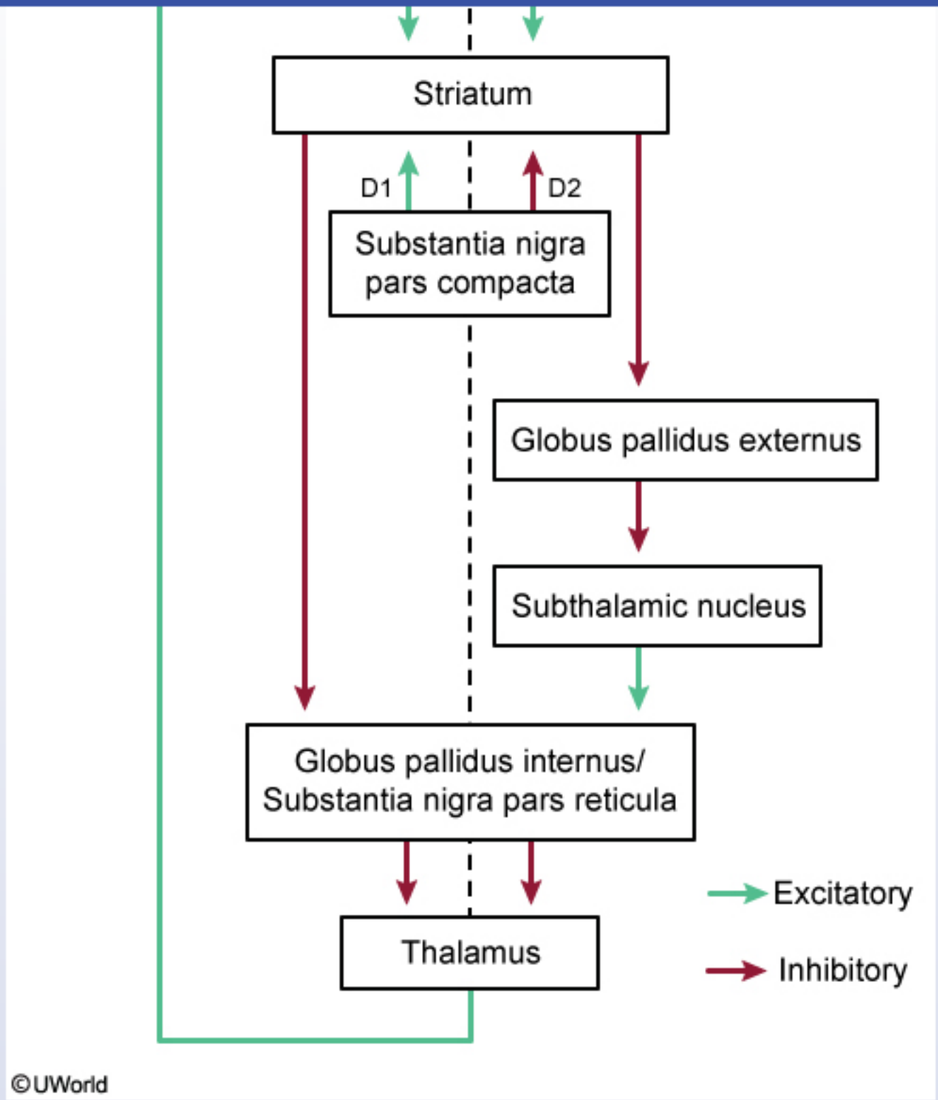

This patient on long-term levodopa treatment for **Parkinson disease** has likely developed motor fluctuations and dyskinesia, which often occur >5 years after starting therapy. Motor fluctuations can initially correlate with serum drug levels and are characterized by good mobility during "on"

This patient on long-term levodopa treatment for **Parkinson disease** has likely developed motor fluctuations and dyskinesia, which often occur >5 years after starting therapy. Motor fluctuations can initially correlate with serum drug levels and are characterized by good mobility during "on" periods and increased bradykinesia/rigidity during "off" periods when the drug wears off. Dyskinesia typically occurs when the patient is "on" and is characterized by excessive involuntary movements.

Nigrostriatal degeneration in Parkinson disease results in excessive excitation of the globus pallidus internus by the subthalamic nucleus, which in turn causes excessive inhibition of the thalamus. Reduced activity of the thalamus and its projections to the cortex consequently result in rigidity and bradykinesia. Patients with **medically intractable** symptoms of Parkinson disease may benefit from high-frequency deep brain stimulation of the globus pallidus internus or **subthalamic nucleus**. High-frequency stimulation **inhibits firing** of these nuclei. This causes increased activity in the downstream nuclei, resulting in **thalamo-cortical disinhibition** with improved mobility.

(Choices A, B, C, and D) These neural structures are not generally subjected to therapeutic high-frequency deep brain stimulation.

(Choice F) High-frequency stimulation of the ventral intermediate nucleus of the thalamus may reduce thalamic excitation and lessen excessive movements in patients with medically intractable essential tremor.

Educational objective:
Nigrostriatal degeneration in Parkinson disease reduces activity of the thalamus and its projections to the cortex, resulting in bradykinesia and rigidity. Patients with medically intractable symptoms of Parkinson disease may benefit from high-frequency deep brain stimulation of the globus pallidus internus or subthalamic nucleus as it promotes thalamo-cortical disinhibition with improved mobility.

References

- Deep brain stimulation of the subthalamic nucleus in Parkinson's disease 2003-2013: Where are we another 10 years on?
- Deep brain stimulation for Parkinson disease: an expert consensus and review of key issues.
- History, applications, and mechanisms of deep brain stimulation.

Pathology	Nervous System	Parkinson disease
Subject	System	Topic

Copyright © UWorld. All rights reserved.